
sketchymedicine.com
doodles for studying

Title	Page
Gram Positive Cocci	1
Gram Neg Cocci	7
Gram Pos Bacilli	10
Enteric Gram Neg Bacilli	17
Respiratory Gram Neg	27
Zoonotic Gram Neg	30
Gram Pos Branching Filamentous Rods	35
Gram Indeterminate	37
Mycobacteria	43
Spirochetes	45
Cutaneous Mycoses	52
Opportunistic Fungi	55
Parasites	60
RNA Pos Virus	76
RNA Neg Virus	87
DNA Virus	94
Cell Wall membrane active antibiotics	106
Inhibitors of Bacterial Protein Synthesis	113
Other antibiotics	119
Antimycobacterials	122
Antifungals	124
Antivirals: HIV	127
Antivirlas: Hepatitis	131
Antivirlas: other	133
Autonomic Drugs – Parasympathetic & Sympathetic	135
Cardiovascular and Kidney	144
Blood and Inflammation	159
Smooth Muscle	172
GI and Endocrine	178

Bacteria – Gram Positive Cocci



Staphylococcus (grape like) **aureus** (gold in color) – The golden staff of Moses

1. Moses Robes are violet – Gram Positive cocci
2. Cat – Catalase Positive
3. Parting of the red sea – Coagulase Positive (will change fibrin to fibrinogen)
4. Bright red B lightbulb – Beta Hemolytic
5. Tall man – Ferments Mannitol Salt Agar turns yellow.
6. Large letter A on Moses Staff – Protein A, Main virulence factor on staph aureus. Protein A is a component of S. Aureus cell wall and it can bind to the FC region of antibodies and this will prevent compliment from occurring. Preventing opsonization and phagocytosis.
7. Nose missing from the sphinx – S. Aureus will colonize the nares
8. Guy pulling the camel down to his knees
    a. Coughing – Pneumonia
    b. Patchwork quilt – Patchy infiltrate on x-ray
    c. Icosahedron shaped lamps – Icosahedron shaped capsule of the virus that will infect after a S. Aureus infection.
    d. Bandages on the knees – S. Aureus is the most common cause of Septic Arthritis in adults.
    e. Humps with red cloth – Really large erythematous abscesses
9. Spooked camel running to the edge of the cliff – Rapid onset that just happened out of nowhere
    a. Clutching chest with hearts – Rapid onset Bacterial Endocarditis
    b. Mortar and pestle – IV drug use
    c. 3 pyramids in background – Tricuspid valve endocarditis
    d. 2 Fish bones – most common cause of osteomyelitis in adults
10. Bald man w/o turban that is all red – Scalded skin syndrome mediated by a protease
    a. Super Cape on Man - Toxic Shock Syndrome, commonly caused by leaving a bandage in or a tampon, causes nonspecific binding of MHC II to T cell receptors causing over reaction and Cytokine storm.
11. Running Camel with woman holding her mouth – Leads to Food Poisoning. This one is die to preformed toxins not the actual organisms. Usually from meats and mayonnaise. Also comes with salad and cream filled pastries. Usually in 6 hours they will be sick
12. Pharaoh raising hand showing mercy – MRSA – resistant to penicillin Binding proteins
    a. Anubis building pyramids – altered builders of the pyramid signifying altered cell walls
13. Van or Caravan – Vancomycin, TXT for S. Aureus.
14. Nafcillin – TXT for methicillin sensitive S. Aureus "Naf for Staph

Salmon colored sputum. can form abscesses in lungs.



Bacteria – Gram Positive Cocci



Staph epidermidis and Staph saprophyticus – Beauty and the Plumber

1. Violet Color – Gram Pos
2. Cat – Catalase Positive
3. Ammonia Bottle – Urease Positive
4. Jell-O that is not coagulated - Coagulase negative
5. Moses Gello – Coag Neg separates from staph aureus, notice the "-" is red to signify Negative

Staph Epidermidis – normal skin flora,

1. Hardware – Infects hardware or orthopedic joints
2. Tubing – Catheter tubes, Indwelling catheters are also important spots of infections
3. Heart valves - Infection of heart implants – endocarditis of artificially implanted heart valves
4. Gunk on pipes and valves - Uses biofilms to stick to sleek metal and plastic surfaces, these are poly saccharides that protect to antibiotics and immune cells
5. Van – Vancomycin for TXT of Staph Epidermidis endocarditis
6. Dirt on the plumber – Normal Skin Flora
7. Petri dish with blood dripping in – representing contamination of blood cultures.
8. Belly button is showing – Novobiocin Sensitive

Staph saprophyticis – young lady on counter

1. Belly Button NOT showing – Novobiocin resistant
2. Bladder Shaped Drink – UTI's in Sexually Active Females.

Bacteria – Gram Positive Cocci



Group A Strep (Strep pyogenes) – The Pie Genies' Bakery

1. Pie in glass Capsule – Group A Strep is encapsulated
2. Hot Apple – Capsule made out of Hyaluronic Acid
3. Heating Lamp w/ "B" Light – Beta Hemolytic
4. 1st Baker
    a. Baker Holding Honey Crusted Pie – Impetigo
    b. Red Handkerchief – Strep throat, red inflamed throat
    c. Red Mittens on Baker - Erysipelas, red lesion with well demarcated borders, S Pyogenes is the most common cause.

2nd Baker w/ Cape – represents Strep Toxins 3 issues

5. Scarlett Fever –
    a. Strawberry Tongue
    b. Red Handkerchief - Pharyngitis,
    c. Red Gingerbread Man - widespread rash that spares the face.
6. Cape w/Bolt - Toxic Shock Like Syndrome mediated by a super antigen – SpeA, SpeC
7. Burnt Gingerbread man - Necrotizing Fasciitis –SpeB

Master Chef – M Protein in GAS well main virulence factor for Rheumatic Fever, will interfere with opsonization, antiphagocytic, M Protein will mimic antibodies in heart and cause issues with Mitral Valve in heart

8. Chef Swatting away other chef – Antiphagocytic action
9. Miter hat - Very antigenic and elicits a humoral response, creating an antibodies to myosin in cardiac muscle (Molecular mimicry), damages mitral valves
10. Red Handkerchief – Pharyngitis precipitates RF, NOT IMPETIGO
11. Cupcakes w/ JONES on them
    a. J = Joints
    b. "Heart" = Heart Problems
    c. Nodules on extensor surfaces
    d. Erythema marginatum
    e. Sydenham's Chorea
12. Phone cord that looks like a glomerulus - Post Strep Glomerulonephritis, type III hypersensitivity reaction (deposition of antibodies in glomerulus)
    a. Puffy Cheeks – Puffy Cheeks w/ nephritis
    b. Bottle of Cola – Cola Colored Urine
    c. Calendar – Occurs 2 weeks after strep infection
    d. Can occur after pharyngitis and impetigo
    e. Pencil – TXT is penicillin
13. Baker on bottom Right 3 more virulence Factors
    a. O Shaped Donuts – Streptolysin O, allows Strep to be Beta Hemolytic, we generate ASO antibodies to this
    b. Phosphate Cupcakes – Streptokinase, converts plasminogen to plasmin.
    c. Twists – DNA'ases, depolymerize DNA
14. Basset hound – Bacitracin sensitive
15. Lady checking a box of donuts – Tongs are antibodies, check ASO titers to see if there was a Group A Strep Infection.





Group B Strep, Strep agalactiae (galactic Baby)

1. Purple means that it is gram positive
2. Baby – Group B strep Is a major infection in newborns
3. Hippo doll – Positive hippurate test, hydrolyzes sodium hippurate
4. Capsule on hippo – polysaccharide positive
5. Camp tent – cAMP test positive
6. Tent Pole – similar to staph aureus, will have an increasing zone of hemolysis when plated w/ S. aureus
7. Beta Light – Beta hemolytic
8. Basset Hound with Capsule – Bacitracin resistant
9. Meningitis helmet – Most likely to cause meningitis in neonates
10. Red Suit – most likely to cause sepsis in neonates
11. Coughing – Causes Pneumonia
12. Red Arrow on space ship – Space ship represents the petri dish, the Arrowhead is the arcuate that forms in the zone of hemolysis.
13. Tunnel – Vaginal canal where neonate gets group B strep
14. 35 Wk – when a mother is cultured for GBS
15. Pencils for landing legs – Penicillin will be given to mom intrapartum to prevent Group B Strep



Bacteria – Gram Positive Cocci



Strep Pneumonia "the alpha knight tournament"

1. Purple Background - G+
2. α knight tournament – α hemolytic, partial hemolysis where the surrounding zone is a green hue
3. **Strep Pneumonia Knight**
4. Armor – Polysaccharide Capsule is major virulence factor
5. Chin is exposed – Optochin sensitive, optochin inhibits the growth of strep pneumo
6. Double Lance – Lancet shaped diplococci
7. Mud on horses legs - Bile soluble, meaning it does not grow in Bile
8. Rust Colored single lobe on chest – Rust colored sputum and lobar pneumonia
9. Squire mopping up muddy mess MOPS - Meningitides, Otitis Media, Pneumonia, Sinusitis
10. Number 1 sign – number one cause of all these diseases.
11. Cracked Shield with the symbol of IgA dimer molecule - Protease that cleaves IgA that allows invasion of mucosa reducing host defenses
12. Sickle - Removal of spleen leads to susceptibility of infection by encapsulated organisms like in sickle cell anemia.
13. Crows – azithromycin Macrolides
14. 3 Axes - Ceftriaxone
15. **Adults** in the **M**ezzanine, **Children** on the **G**round - 2 pneumococcal vaccines, adult is a 23 valiant polysaccharide vaccine, children is 7 valent but conjugated to a protein. Adults will have a T-Cell independent response creating IgM that does not last long. Adding the protein adds a more robust antigen response leading to a production of IgG in children.

Strep Viridians

1. No Armor – Not encapsulated
2. Jesters mask protects face including the chin – optochin resistant
3. Donkey with bile resistant boots – Bile resistant
4. Foul Yellow teeth on donkey – associated with dental carries
5. Deck of cards with plate shield - Synthesizes Dextran's from glucose which allows strep viridians to adhere to any fibrin from platelets that has been damaged in the heart.
6. Strep Sanguineous adheres to fibrin platelet aggregates in <u>damaged</u> heart valves, most commonly occurs in mitral valve.





Enterococcus – Protest at the Caucus – Entero (intestinal) Coccus (Round)

1. Massive amount pf people under the California caucus sign - E. Faecalis and more common
2. Buff protestor holding the “stop the fees” sign - E. Faecium is more dangerous than Faecalis
3. Resist the 6.5% N Ca - Grow in mediums of up to 6.5% NaCl
4. E Faecium resisting the police officer hitting him with a billy club – Bile resistant
5. E. Faecium wearing bile resistant boots – Bile resitant
6. Do you (heart) Trees – U is UTI’s, (heart) is endocarditis, Tree is infection of biliary tree
7. Resisting arrest and being thrown in the van - Nosocomial infection resistant to almost every antibiotic we have. Vancomycin resistant
8. Police line sign – Linezolid TXT
9. Tiger stripes - Tigacycline



Bacteria – Gram Negative Cocci



Neisseria species overview - "Noir Series"

1. Blue ring - Oxidase positive
2. Red theme - Gram Neg
3. Double handcuffs – Diplococci
4. Detective holding a chocolate bar - Grows on Chocolate Agar, inhibited on blood agar.
5. **V**ice city **P**rivate **N**vestigator – VPN special agar enriched with vancomycin, polymixin, and nystatin
6. Starring "Thayer Martin" – Thayer martin AKA VPN agar **SELECTIVE AGAR**
7. "MAC" Private eye - MAC Deficiency unable to form the MAC complex due to complex c5-c9 being inhibited
8. Show runs 5-9pm – reminds us c5-c9 MAC Deficiency
9. **Virulence Factors**
    a. different pocket watch chain metals - Pilli allows attachment to surfaces and display <u>antigenic variation</u>
    b. Ace in MAC's Hat w/ IgA symbol - IgA protease will cleave IGA at its hinge point, facilitates survival along mucosal surfaces



Bacteria – Gram Negative Cocci



Neisseria meningitides "A shocking Death on Campus"

1. Takes Place in a College dorm - Easily spread in areas with a lot of people, military recruits, college dorms via respiratory droplets
2. Red Hue – Gram Neg
3. MAC – Reminds us of the common features
4. Inspection of a bottle of MALT liquor -Only meningitides ferments maltose
5. Long Cotton Swab - Nasopharyngeal swab suggests that it is found in nasal cavities first and transmitted via respiratory secretions.
6. Syringes on the floor - We have vaccines for A,C,D polysaccharide capsules but not B
7. Covered up syringes - Capsule is the major virulence factor, type B strain is not included in the vaccine
8. Sickle and Hammer Flag - Sickle cell disease are more susceptible to Neisseria meningitides because it is encapsulated
9. Burning Envelopes – N. Meningitides Invades hemotogenously leading to a massive Immune response generated but LOS (lipooligiosaccharides) proteins, these are Neisseria's version of LPS, it grows so much of it that it outgrows the surface area of the bacteria and begins blabbing off. These blebs of LOS envelope that lead to a massive inflammatory response. "LOS envelopes caught fire
10. Pathogenesis
    a. Burning Envelopes - Inflammatory response
    b. leaky sprinklers - Leakage of interstitial fluid by capillaries) hypovolemia
    c. Dark Spots on Carpet - Characteristic petechial rash leading to thrombocytopenia leading to DIC
    d. Red spot on boxers also mean petechial rash
    e. Water sprinkler on and shock coming from electrical outlet - Capillary leakage can lead to shock
    f. Waterhouse in the background - Vasoconstriction will go to max to attempt to maintain blood pressure and adrenals can infarct and will contribute to shock (Waterhouse fritter syndrome)
11. 15% mortality rate
12. Axes on Firefighter - Treatment - 3rd generation cephalosporin (ceftriaxone)
13. Police with rifle - Close contacts will need rifampin





Neisseria gonorrhea - "The Violinists last Clap"

1. Mac – Reminds us of all the common features of the Neisseria species
2. Flirting with someone at the bar - Sexually transmitted infection
3. Gonzo's - Gonorrhea
4. 2 red pillows on chairs - with Gram Neg diplococci
5. Seats with the high back white chairs - Facultative intracellular and invade PMN's
6. White spots on chairs – look like nuclei, trying to look like PMN's
7. Glass falling off the table and breaking - Not encapsulated NOT ENCAPSULATED
8. Effects genitalia first – in male's causes urethritis and prostatitis and orchiditis.
9. Female infection
    a. Chandelier (uterus w/ fallopian tubes and ovaries) candle wax is falling - Pelvic inflammatory Disease - purulent white discharge
    b. Fitz Hugh Curtis Band - PID spreading to peritoneum - Fitz Hugh Curtiss syndrome - Violin string like adhesions in liver from spread into peritoneum.
    c. Statue fell with cracks on one knee - May cause polyarthritis in the knee and is asymmetric
10. Mother holding a baby shielding the baby's eyes - Can be passed on to baby during delivery and will cause a conjunctivitis w/ in 5 days of birth.
11. Statue w/ three axes, and three axe emblem on wall - Ceftriaxone is treatment but will need treatment for chlamydia, macrolide Zpack.
12. Shell shape napkins – reminder to treat for chlamydia due to coinfection.





Bacillus Anthracis and Bacillus cereus – King Anthra's Axe

1. Vikings standing around red hot flames and black in the middle – Black Eschar with erythematous ring.
2. Viking ships lined up in the background - Large gram pos rods in chains
3. Leather armor – encapsulated, this one is made of a protein
4. D Belt Buckles - Capsulated with Poly –D glutamate
5. Air Bellow - Obligate Aerobe
6. walnuts – Bacillus anthracis is a spore forming bacteria allowing them to survive in very poor environments
7. Viking Camp Test - EF Toxin <u>increases cAMP intercellularily</u> this will cause fluid to go extracellular space leading to edema inhibiting host defenses and preventing phagocytosis
8. MAP with Lethal Factor Viking Burning it - LF (lethal Factor), exotoxin that acts as a protease and <u>cleaves MAP Kinase</u>, this is a signal transduction protein that is responsible for cell growth. This factor will lead to necrosis and black eschar
9. Sheep – pulmonary anthrax, wool sorters disease. Spores can get into wool and hide of animals and persist there. People will inhale the spores when the animal is handled.
10. Axe that is dripping blood – represent pulmonary anthrax that can move to mediastinal lymph nodes progressing to hemorrhagic mediastianitis
11. Viking ship with a mast supposed to look like a chest xray – widened mediastinum
12. Flower and Bicycle wheel on the ship – txt is fluoroquinolone or doxycycline

1. **Bacillus cereus**
2. Aerobic and spore forming
3. Viking reheating rice and vomiting - Associated with food poisoning – reheated fried rice



Clostridium tetani – Rhesus Research Revolution

1. Violet Hues – Clostridium Genus is Gram Positive
2. Researcher in the middle with gas mask– Obligate anaerobes
3. Walnuts – Spore forming
4. Rusty nails and barbed wire, pots of soil – Clostridium is found in the dirt and enters the body through a puncture wound
5. Rhesus monkeys that are grinning - Spastic paralysis leading to rigidity, rhesus (to grin) sardonicus (evil), also accompanies with lock jaw.
6. Monkey in the exaggerated arching back position – reminds us of Opisthosomas
7. Pathogenesis
    1. Puncture wound occurs either by nail or barbed wire with tetany spores on it, spores are embedded in the flesh and the organism vegetates and stays at the wound site. It will release tetanus toxin that will cause all the symptoms
    2. Monkey operating a pulley with scissors on it - Tetanus toxin will travel retrograde through the motor axons to the spinal cord.
    3. Monkey cutting the snare trap - Tetanus toxin will cleave snare and inhibit exocytosis of the neurotransmitter into the synapse (GABA and glycine) or Renshaw cells.
    4. G&G labs – to represent 2 type of inhibitory neurons, GABA and glycine. If these are inhibited it will result in uncontrolled firing of the motor neurons leading to spastic paralysis.
    5. Monkey with wrench and saw - Renshaw cells will sense over activity of nearby motor neurons and when they sense this activity they will attempt to fire and inhibit the motor neuron. So the GABA and Glycine release from these cells is inhibited leading to spasm

a. Researcher with Vaccine in hand – Toxoid Vaccine, toxin conjugated to protein. Antibody response to the toxin.





Clostridium botulinum – Robotulism

1. Purple Hues – Gram Pos
2. Robots made of cans –transmitted by improper canning of food allowing it to flourish in the anaerobic environment producing heat stable toxin. “a family are presenting with the same neural symptoms”
3. Lug Nuts – Spore formers
4. Gas Mask – Obligate Anaerobe
5. Robots struggling to keep body’s upright – Flaccid paralysis, descending paralysis. Opposite of Guillen barre syndrome. Multiple people is most likely botulism, not Guillen barre
6. Robots eyelids are droopy – early symptoms include ptosis and diplopia.
7. Robots lights are on or off – to demonstrate the descending paralysis, toxin is unable to cross BBB so only peripheral nervous system
8. Power area in the back with the ACh symbol - Cleavage of SNARE protein similar to Tetany toxin, only difference is that botulism attacks motor neurons that release Ach, inhibiting motor neuron release leading to flaccid paralysis.
9. Guy in a suit similar to tetany story cutting wire with scissors – Toxin is a protease that cleaves SNARE proteins
10. Robot Baby has no lights on and is limp – toxin effects similar to babies and cause flaccid paralysis “Floppy Baby Syndrome”
11. Robot pouring honey all over the baby robot dripping all over the nuts (spores) - Babies lack robust flora of gut that can out compete Clostridium botulinum will be colonized if they ingest honey. Then they will produce the toxin and have floppy baby syndrome – **Babies get the toxin by ingestion of spores, adults get the toxin by ingestion of pre formed antigen from improperly canned foods.**





Clostridium Difficile – Field trip to the chocolate factory

1. Walnuts – Spore formers
2. Clean sign that reminds employees to wash hands, that is directly over the chocolate machine to show that it Clindamycin and poorly washed hands can cause it - Nosocomial diarrhea, spores easily transferred from patient to patient, antibiotics will wipe out normal flora making patients immunocompromised and able to be colonized then create the toxin. Clindamycin is one of the main antibiotics that will cause this.
3. Workstation A and workstation B - 2 exotoxins that are produced by C Diff.
4. A is for Apple and is for exotoxin A – Binds to the brush border of the intestine and causes inflammation, cell death and watery diarrhea. A for Apple
5. Employee picking up the apple and brushing chocolate on them – brushing is for targeting the brush border, the proximity to the chocolate canal will remind you that exotoxin A causes diarrhea. Brush Border Toxin causing watery diarrhea.
6. B is for black licorice and is for exotoxin B – B is for Black Licorice – disrupts cytoskeleton integrity by depolymerizing actin leading to enterocyte death and necrosis. Yellowish grey exudate that forms a pseudo membrane that covers the colonic mucosa. This is why it is called a pseudomembranous colitis.
7. Black Licorice – looks like actin
8. Little kid chewing them apart – Depolymerization of actin filaments
9. Worker packing the licorice in sheets of yellowish plastic – Pseudo membrane formation
10. Kid walking in the flowing chocolate – Assay to detect TOXIN in stool that will be detected downstream
11. Gas mask – Obligate anaerobe
12. Violet – Gram Positive
13. Van with the mouth look alike - Oral Vancomycin txt
14. Train – txt Metronidazole





Clostridium perfringes – Private Ringen's Motorcycle Accident

1. Motorcycle accidents and deep penetrating military combat wounds – Classic Presentations, Large amounts of flesh are exposed to dirt and dust
2. Walnuts and knocked over dirt - Forms spores that are found in soil
3. Gas leaking out or the motorcycle - Causes Gas Gangrene after it enters the wound, clostridial myonecrosis, gas produced under tissue and has a cracking sound on palpation
4. α flag - Alpha toxin that effects lipid bilayer and lyses RBC's. Myonecrosis involves alpha toxin, or lecithiinase (phospholipase)
5. Clothespins are arranged opposite of each other – showing the lipid bilayer and how it is damaged
6. Red tomatoes on the ground – Lecithinase can cause red cell hemolysis
7. Red sign "double fine zone" - Double zone of hemolysis
8. Gas Mask - Obligate anaerobe
9. Slow sign - Slow onset diarrhea due to spores needing to reproduce in the gut then create the toxin
10. Woman holding a pencil – 1st line txt is IV Penicillin G



Corynebacterium Diphtheria - Corazon de la Corrida

1. Purple Hues - Gram Pos, non-spore forming
2. Guy playing Morocco's that are blue and red – Bacteria is club shaped and y or v shaped, Metachromatic granules that stain with aniline dyes, Metachromatic granules will stain red and the rest of the cell will stain blue.
3. Zig Zag shape in the morocco - V or y shape the bacteria will form
4. 2 subunits A and B, A is active and B is binding
    1. Man playing an accordion wearing a bow tie - Toxin causes Ribosylation of elongation factor 2, this will inhibit ribosome function inhibiting protein synthesis leading to cell death
    2. Kids in the stand eating grey cotton candy wrapped with a plastic wrap - This will lead to pseudomembranous exudate that will be found in the oral pharynx
5. Bull extending its neck with droplets coming out of the mouth and nose - Found in throat and tonsils because the infection is transmitted by respiratory droplets, Can cause airway obstruction and lymphopathy, this will cause bulls neck (thickening of the neck)
6. Cape in the shape of a heart - Can lead to myocarditis like arrhythmias and heart block. Lethal effect of diphtheria
7. Man eating the sausage links - Will damage the myelin of nerve fibers, the sausage man eating the myelin having a neuropathy.
8. Television and kid laughing - Lab diagnosis -plate on Tellurite and Loeflers media (tele like television and loughlers will be the kid laughing like enjoying a show)
9. Bulls tongue sticking out and licking the matador - Eleks test – in-vitro assay that has antitoxin on it.
10. Why it's in another language - Immigrants most likely to get this
11. Syringes in the bull - DTaP vaccine is used, given with tetanus and pertussis. Toxoid Vaccine





Listeria monocytogenes – Santa's List

1. β – Hemolytic Lightbulb – β Hemolytic
2. Purple ornaments tumbling down the Christmas tree - Motile and facultative intracellular, tumbling motility extracellular
3. Purple oblong shaped ornaments – Gram Positive Bacilli
4. Rocket toys notice that one is still inside Santa's bag - Rapidly polymerizes actin along the cell wall allowing it to move quickly in the cell. Rocket "Actin Rocket" Intracellular movement
5. Cat – Catalase Positive
6. Icicles – Listeria survives and multiplies in near freezing temperatures
7. Milk and cheese left out for Santa - Can contaminate food items even if they are refrigerated, like milk, cheese
8. Pregnant – Pregnant women are more likely to get listeria than anyone else. May lead to termination or disease in the newborn
9. Meningitis helmet - Newborns can get meningitis from the mom, can also get in in adults over 60
10. Guitar with amp – txt is Ampicillin

Bacteria – Gram Negative Bacilli

Enteric



Proteus Mirabilis - The god of the public restroom

1. Red Hue - Gram Negative
2. Swarming Tentacles – Swarming Motility when plated
3. Facultative Anaerobe
4. Helmet means stag horn calculi in the kidney, kidney stones
5. Ammonia Spray - Ammonia means urease positive, this is what makes the stag horn calculi, to struvite stones causing pain and kidney stones, alkaline formation causes kidney struvite stones. Formed of ammonia, magnesium, and phosphate
6. Throwing a stone – Kidney Stones
7. Urinating in the stall – causes UTI's
8. Fish on the floor - Fishy Odor
9. Eggs on the floor - Treatment – Sulfonamides
10. H2S Positive





Yersinia enterocolitica & pestis - "Yersins pets"

Yersinia enterocolitica

1. Red Hue - Gram Neg
2. English terrier - enterocholitica
3. Puppy Poop - Transmitted through puppy feces
4. Child on the stool - Children are the most common individuals infected
5. Child drinking from a milk bottle - Transmitted through contaminated milk products
6. Ice on the outside of the building - Similar to listeria it is resistant to cold temperatures
7. Bipolar "safety pin" staining – Stains heavily on two ends
8. Glass Capsule - Encapsulated virulence factor
9. Red Stool - Bloody Diarrhea
10. Invasive systemic effects like fever, intestinal issues, leukocytosis, abscesses, major bowel issues
11. English terrier licking RLQ of toddler - Mimics appendicitis

Yersinia Pestis

1. Bubonic plague - 25 million people died
2. Anti-Flea spray sign - Transmitted through human as incidental host, usually with rats or prairie dogs. "Rodents" with fleas, then fleas bite humans
3. Guy in the back with the swollen lymph nodes - Forms Buboes with swollen tender lymph nodes.
4. Cause abscesses in organs or DIC from endotoxin and neurotoxin
5. Exotoxins
6. Turkey baster - Yersinia outer proteins that inhibit macrophages through a type 3 secretion system, inhibiting phagocytosis
7. Sai and bicycle wheel - Treatment Aminoglycosides with tetracycline
8. Vaccine Poster - Killed vaccine is used to vaccinate





Shigella: She Gorilla's Circus

1. Red Stool with flames surrounding it - Gram Negative enteric causes gastroenteritis (inflammatory) leading to watery diarrhea and then finally bloody diarrhea
2. Green Tutu - Green colonies on hektoin agar INDOLE POSITIVE, differentiate salmonella from Shigella: Salmonella will grow black
3. Chained to the weight- **Immotile**, non-lactose, **non H2S, LPS(endotoxin) leads to inflammation, type III secretion**
4. Gorilla walking over the acid - Acid Stable - needs far fewer organisms to cause infection
5. Cannon shooting a gorilla and landing on a pad w/ an M - Shigella induces M Cells in peyers patches to phagocytose them and they escape from the phagolysosome to prior to destruction. And then will use the host cells actin cytoskeleton to create a tail it can use to propel itself from one cell to the other.
6. Facultative intracellular
7. Damages tissue and releases cytokines that will inflame the tissue causing bloody diarrhea
8. Shigella Dysentaria
    a. Kid using a whip on the blood cells - Leads to **hemolytic uremic syndrome in younger children most commonly under 10 years of age**. Progerminal diarrhea following with <u>acute renal failure (glomerular damage)</u>. Form shistocytes
    b. 60s hourglass - Shiga Toxin will bind to the 60s unit of ribosomes and inhibit translation,
    c. Turkey baster - Uses a type 3 secretion system to release micro enzymes.
9. Treatment with Macrolides and Fluoroquinolones





Escherichia coli

1. Red Theme – Gram Neg
2. Milk Container - Ferments lactose - Grow pink on MacConkey's Agar
3. Capsule - Encapsulated - Facultative Anaerobic, Oxidase negative, green sheen on EMB
4. **K Cake - Main Virulence Factor -** Capsular K antigen and Flagellar H Antigens
5. Green Coasters - Metallic green sheen on EMB Agar
6. Cat - Catalase Positive
7. #1 UTI Bladder Drink with long fimbriae bow off girls head - Fimbriae that will lead to **UTI's #1 cause of UTI's**
8. Red Strawberry Milkshake - E.coli leading cause of gram neg sepsis by LPS endotoxin in outer cell membrane
9. Meningitis Helmet - Causes **neonatal meningitis only if have the K antigen**
10. EHEC - Severe Hemorrhagic Colitis caused by O157 H7
    a. Burger - Most Commonly caused by eating undercooked meat.
    b. Red Stool and bloody Ketchup- Causes bloody diarrhea, red stool symbol
    c. Sorbitol Free Coke - Only E.coli that does not ferment sorbitol
    d. Gorilla toy, Blown up balloon - Toxin: inhibits ribosomes at the 60s position. Shiga like Toxin can cause hemolytic uretic syndrome. Shiga like toxin damages endothelial cells of capillaries in the glomerulus. Damaged endothelial lining causes platelets to adhere decreasing platelet count causing thrombocytopenia and these platelet clumps will hemolysis RBCS. Little to no fever but mucosal inflammation or invasion
    e. "E. Coli Burger only $1.57" - O157:H7 Antigen is associated with outbreaks.
11. ETEC - travelers' Diarrhea
    a. Water Truck - Transmitted via water sources.
    b. It's in Spanish - Recent travel to Mexico where they drank the water, called **Montezuma's revenge.**
    c. "eL Agua" - Heat **l**abile toxin produces c**A**MP
    d. "San Gabriel" - **S**table produces c**G**MP
    e. Brown Stool with water above it - Watery Diarrhea
12. Treatment
    a. TMP/SMX or fluoroquinolones



Bacteria – Gram Negative Bacilli

Enteric



Campylobacter Jejuni - Camping Guy and the bears – guy and bears = Guillen Barre

1. Mustache is curved or comma shaped - Gram Negative Spiral / Curved Rod Bacilli - Enteric
2. Campy medium or **Skirrow Agar**
3. Microaerophilic
4. Camp Fire - Prefers warm environments around 42 deg Celsius, thermophile (Special Incubator)
5. Chicken being cooked - Main reservoir is intestinal tract of poultry and transmission is fecal oral / also contaminated water supplies or ingestion of raw milk
6. Red Stools - Bloody Stools and diarrhea
7. Blue Ring - Oxidase Positive
8. Bear cub invading the cooler - Can get Bacteremia, INVASIVE
    a. Laughing and slapping his knee - Reactive arthritis, riders syndrome
9. Bears being tripped by the sausage links on his ankle - Can cause Guillen barre syndrome due to an autoimmune response damaging myelin of peripheral nerves leading to an ascending paralysis will start at the feet then ascend.
10. Pathogenesis
    a. Bacteria Colonize intestinal Mucosa and attach to epithelial cells then replicate intracellularly causing an acute PMN response, edema of the mucosa and ulcerations. Presenting with acute enteritis and diarrhea
11. Treatment
    a. Supportive Care



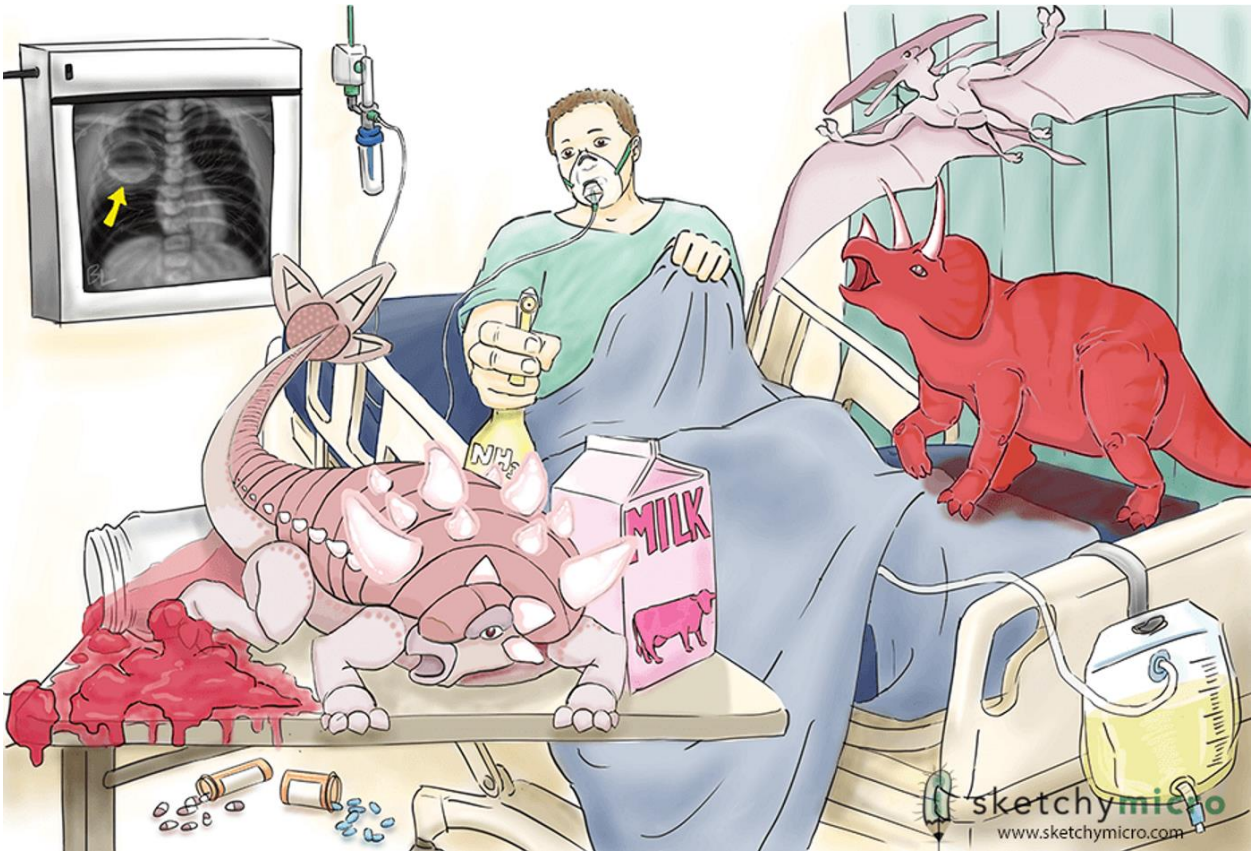

Klebsiella, Enterobacter, Serratia

1. Red theme - Gram Neg
2. Oxygen Mask - Pneumonia
3. Urinary Bag hanging off the bed - UTI
4. In the hospital - Nosocomial infections
5. Pills on the ground – Multi Drug Resistant Carbopenam for treatment or Clindamycin
6. Milk Carton - **Ferment lactose** - turns it pink - along with E Coli - on **MacConkey's agar**
7. Enterobacter
    a. Very motile since pterodactyl is flying
8. Serratia
    a. Triceratops - very motile
    b. Red pigment when cultured like a pink ring around shower or bright red
    c. Catalase Positive
9. Kleibsiella - Ankylosaurs with club shaped tail - Immotile
    a. Three A's in the spikes –Alcoholics, Abscesses, Aspiration
    b. Thick shell like scales is like a polysaccharide capsule
    c. Knocked over jar of currant jelly, that is sticking him to the table - Current jelly like sputum that is a red color
    d. Jelly sticking klebsiella to the table - Kliebsiella is immotile
    e. X-Ray - Cavatary lesion on patients right lobe "tb like"
    f. Ammonia spray bottle - Urease positive

Treat 3rd gen ⇒ ceftriaxone, cefotaxime





Helicobacter Pylori: The helicopter Pilot

1. Red Helicopter -Curved Gram Negative rod
2. Mustache that is comma shaped - Helical slender curved rod Shape found in pylorus of the stomach
3. Not a rare infection.
4. Helicopters are motile - Motile by way of flagella
5. **Ammonia bottle - Urease positive - MAJOR VIRULENCE FACTOR** - allows to reduce the acidity of the stomach and allows Helicobacter to survive there.
6. Can be tested with Urea breath test, radioactive urea that is broken down and exhaled as CO2 and NH3 by urease positive organisms.
7. Blue ring - Oxidase Positive – all curved rods are oxidase positive
8. Bullet holes in helicopter, Gas pump w/duodenum - Causes 95% of all duodenal ulcers
9. Crab - Mechanism of Chronic infection causes increased acid infection. At risk of developing gastric adenocarcinoma
10. Tissues that are thrown in garbage - Patient can develop lymphoma of mucous associated lymphoid tissue.
11. Treatment
    a. Gas Pump with duodenum and H+ Bomb - Proton Pump Inhibitor
    b. Amoxicillin - ammo
    c. Crow w/ Keep Clear - Macrolide - Clarithromycin
12. Transmission
    a. Fecal Oral or Oral





Pseudomonas - The suiters of pseudo Mona

1. Red theme - Gram Negative rod
2. Bathtub - Thrives in aquatic environments, hot tub folliculitis
3. Blue Ring - Oxidase Positive
4. Cat - Catalase Positive -
5. Chronic Granulomatous Disease heightened risk
6. Blue Green on tub - Produces a blue green pigment when plated may even turn wounds blue. It's from Pyocyanin and pyoverdin
7. Grapes being eaten - Fruity grape like odor
8. Air bellow Billowing the flames - Obligate Aerobe
9. Nurse pouring chlorine to remind us of the dysfunctional channel of CF patients - Most common Gram Neg Nosocomial Pneumonia, respiratory failure in CF patients. Chlorine channels in CF
10. Nurse Coughing – Causes pneumonia
11. Mortar and pestle w/ Fish bones - Osteomyelitis in the IV drug users and Diabetics.
12. Glass Capsule - Encapsulated
13. Maid on fire - Burn patients are especially susceptible.
14. Chamber Pot - Indwelling catheter infections from UTI's, chamber pot, nosocomial UIT's
15. Pruritic folliculitis (Hot tub folliculitis)
16. Dalmatian Dog - Can lead to ecthyma gangrenosom (black spots on the Dalmatian)
17. ear trumpet maid listening - Otitis Externa (swimmers ear)
18. 1st suiter in green - Exotoxin A - Ribosolation of elongation factor 2, leads to inhibition of protein synthesis and cell death
19. Piper suiter and Suiter with a Sai and flower - Treatment - Piperacillin (penicillin) , aminoglycosides and Fluoroquinolones



Bacteria – Gram Negative Bacilli

Enteric



Salmonella - the salmon dinner

1. Gram Negative - Non lactose Fermenter, white on MacConkey's
2. **Tail Flopping around - Motile** - Indole Negative due to lack of tryptophanase
3. Plate is black **- H2S positive -** All motile enteric colonies stain black on hektoen agar
4. Glass dome over salmon - Capsulated - Positive for citrate utilization turns indicator blue due to alkaline pH
5. Lemon - Acid Labile - need high does to cause an infection patients on proton pump inhibitor more susceptible to infection
6. Bird Cages w/ MΦ - Invades through colon through the macrophages to get into the colon, Facultative intracellular
7. **Salmonella E. (Left)**
   a. Chicken - Caused by eating undercooked Chickens
   b. Candle - Causes inflammatory Diarrhea, Gastroenteritis
   c. Turkey Baster - Contains type 3 secretion system that detects eukaryotic cells that will increase infectivity
8. **Salmonella Typhi** (typhoid Fever) always from a HUMAN Source
   a. Chef Apron - Harbored in the Gall Bladder, Typhoid Mary
   b. Red spots on apron to remind us that patients get on their stomach due to infection
   a. Bones on the head of salmon and sickle- #1 cause of osteomyelitis in adults with sickle cell
   b. Bird droppings - Can cause "pea soup" diarrhea
   c. Flower on table - Treated with fluoroquinolone, or a cephalosporin (ceftriaxone)
   d. Syringe sticking leg of seagull - Live, Attenuated Vaccine
9. Treatment – many resistances
   a. Gastroenteritis Antibiotics not warranted, Do not use antidiarrheal
   b. Sal. Septicemia Aggressive Chloramphenicol, amp, Amox, or TMP/SMX for 10 days
   c. Flouroquinalones – Cipro/levo
   d. CEFTRIAXONE FOR INVASIVE AND BLOODY

Salmonella Typhi (right)

Three Phases

1. After sufficient bacteria have multiplied in the intestines there is a manifestation of lethargy dull frontal headache, **CONSTIPATION**, rise in body temp. binds to

Phase 2: Development of a bacteremia, patients have fever and are severely ill with a **Dull Expressionless look, rose spots develop mainly on the trunk**

Phase 3: **Second Bacteremia** occurs from reinfection of biliary tract, pus in stools and bleeding in peyers patches, Ileum Necrosis





Vibrio Cholera - Colonel Cholera's Base Camp

1. Mustache - COMMA SHAPED Gram Negative Curved rod Enteric Tract Bacilli
2. BASE in BASE cAMP – Prefers to grow in alkaline media
3. Blue Ring - Oxidase Positive - Grows on TCBS agar
4. Lemon - Grows in alkaline environments, ACID LABILE - Dies with acid
5. Rice Patties - Causes Profuse watery diarrhea **"Rice Water"** stool
6. Outhouse dumping directly into the river - Cholera is transmitted fecal oral due to poor sanitation that gets into food and is not an invasive infection
7. River walls are mucosal wall and the water is the intestinal lumen - Found in the intestines and is found in the intestinal mucosae
8. Raft that is attached to the shore - Attaches to the mucosa by fimbriae that attach to ganglioside receptors in the intestinal wall.
9. Then releases **cholera toxin - Main Virulence Factor AB type toxin**
    a. BASE cAMP map - Upregulates production of Gαs cAMP by binding to and increasing activating adenylate cyclase.
    b. GS grenade - Then it will activate the GS pathway. Activates GS, upregulates cAMP, Produces watery diarrhea through an efflux if Cl and H2O
10. Treatment
    a. Drinking some water - Oral rehydration therapy with electrolytes
11. Vibrio Vulnificus and paraliticus
    a. Oysters - Can contaminate seafood, especially oysters.
    b. Vibrio V. causes Acute Gastroenteritis
    c. Vibrio P. Causes fulminating septicemia leading to death. Marked edema and necrosis



Bacteria – Gram Negative Rods

Respiratory



Bordetella Pertussis – Board and Care

1. Streamers to represent pili - Respiratory droplets are very infective using Pilus called filamentous hemagglutinin
2. Bow tie - Pertussis Toxin - Ribosylates Gi disabling it
3. GI uniform - Toxic inhibits GI, Disabled Gi (G inhibitor Protein)
4. Military Camp - Leads to a rise in cAMP
5. Popcorn, overabundance of white kernels - ADP Disables Chemokine receptors for lymphocytes leading to an overabundance of white blood cells in the blood stream, lymphocytosis
6. EF Shield - Adenylate cyclase toxin acts like the anthracis toxin edema factor, increases cAMP, Edema Factor, Most Virulent
7. Tractor on the middle road cutting the grass- Tracheal toxin damages ciliated cells in the epithelium, tractor cuts long cilia grass
8. Vet coughing vigorously - Catarrhal phase, limited symptoms nonspecific, most bugs, most contagious. 1-2 weeks
9. Whooping Horn - Paroxysmal - characteristic cough "Whoop"
10. 100 days war banner - Convalescence stage - final stage lasting 3 months with a cough, 100 day cough, most susceptible to secondary infections
11. Crow - Treatment Macrolides
12. Syringe with cell phone - DTaP - **acellular** vaccine using purified antigens
13. Red Hues - Gram Neg
14. Aerobic
15. Non motile

Catarrhal stage lasts one to two weeks and is characterized by symptoms of an upper respiratory infection such as low-grade fever, nasal congestion, and rhinorrhea.

The paroxysmal stage lasts two to eight weeks and is characterized by paroxysms of coughing followed by an inspiratory whoop.

The last stage is the convalescent stage, which may last for weeks to months, and is characterized by a subsiding cough.





Haemophilus Influenza - "Phyllis's Chocolate Covered Cherries"

1. Red Hues - Gram Neg
2. Shape of the candy machine and candy on top of the machine - Coccobacillary Shape
3. Chocolate sign – Grown in chocolate agar
4. 10 cent sign – Needs Factor 10 “Hemodin”
5. 5 cent sign - Grown on chocolate agar needs factor 5 (NAD, nicotinamide) and factor 10 (Hemodin) "hemoTEN"
6. Child Coughing and aerosol spray - Infection primarily moved by aerosol transmission leading to droplets going to respiratory track calling pneumonia
7. Child sticking out the red tongue screaming - Disease Epiglottitis - symptoms Drooling, inflamed epiglottis, strider, drooling
8. Cherries - "cherry red epiglottis"
9. Child plugging his ears - Otitis Media
10. Meningitis helmet and Bee flying around - Meningitides - only caused by type B capsular form.
11. Sickles attached to belts - Sepsis and Septic arthritis in patients without a spleen, hemophilic infections, especially sickle cell disease
12. Syringe and Capsule with the Bee flying around it - Vaccine for only the type B capsule is conjugated with diphtheria toxoid and haemophilus type B capsule
13. **Dip**ped for 2.18 - Vaccinate between 6 weeks - 18 months (bound to diphtheria) Dip=Diphtheria
14. Three Axes -Treatment Ceftriaxone
15. Rifle - Treatment for close contacts is rifampin





Legionella - "The SS cysteine joins the legion"

1. Red and Rusty ship due it to being gram neg - but visualized under silver stain
2. Silver Ship – Silver stain to visualize
3. Heaping piles of coal on the ship - Agar requirement is charcoal yeast extract in presence of cysteine and iron
4. SS Cysteine and Iron anchor – Cysteine and iron need to be added to agar
5. Pontiac car broke down - Pontiac Fever - fever and malaise usually is self-limiting
6. Sailor smoking - Legionnaire's Disease - common in smokers and elderly men
7. Blue print of the ships layout with lobar infiltrate - Atypical pneumonia patchy unilobed infiltrate
8. Sailor spilling salt into the sea - Clinical presentation - Hyponatremia - excess HNO3 ammonia Na. wasting salt
9. Falling paint can hitting sailor below - Neurologic symptoms, headache with confusion
10. Brown paint spilled over - Diarrhea
11. Sweating sailor - High fever over 104 F
12. Fresh Water
13. Sailor pissing in the river - Lab test to confirm - rapid urine antigen test to confirm
14. Crow or Sailor giving away a flower - Treat with macrolides and fluoroquinolones
15. Girl wearing the ring - Oxidase Positive
16. **Zinc Melloprotease is the main virulence factor, its cytotoxic and inhibits PMN production, inhibits superoxide reduction, deactivates il-1 and CD4 and TNF.**





Bruce Farms - Brucella

1. Bruce farms - red to remember it is Gram neg
2. Farm animal is the reservoir - cows and pigs, goats, veterinarian, slaughterhouse worker, or rancher.
3. Milk Bucket on the ground - Indirect contact with milk or cheese products that unpasteurized
4. Open Cage on Barn house - Facultative intracellular can live inside or outside of host cells
5. Symptoms - fever, chills, and anorexia initially.
6. Undulating hills - Undulant fever
7. Markings on the cow - Can travel through multiple endothelial organs leading to enlargement of spleen, liver and lymph nodes.
8. Fish Bones - Osteomyelitis - chronic infection
9. Wheel -Treatment - tetracycline, doxycycline
10. Rifle - Along with rifampin for primary treatment
    blocks oxidative bursts
11. Cage in the background - Infect macrophages
12. Large amounts of catalase and superoxide dismutase to protect from respiratory burst
13. Urease and H2S positive
14. Require cO2 to grow





Francisella Telarensis Tularemia Francis the rabbit

1. Red Beets - Gram Neg Coccobacilli
2. Rabbits and Ticks - Tick vector or rabbit vector (dermacenter tick)
3. Can be aerosolized and potential to use in bioterrorism
4. Radish shape - Looks like a radish, not perfectly spherical.. Coccobacilli
5. Cage is open - Facultative intracellular - cell mediated immunity needed to kill it
6. Rabbit hole ulcerating into the soil - Causes painful ulcer
7. Center of radish pile is rotting - Enters through ulcer and into macrophages in the lymph system to reticuloendothelial organs and causes caseation necrosis
8. Radishes pushing up dirt around them - Regional lymphadenopathy
9. Sais - Treatment is streptomycin - aminoglycoside
10. Fransciella does not induce oxidative burst



Coxiella burnetii - "Curly Q the Ram"

1. Causes Q fever -
2. Red Barn - Gram Negative
3. Pristine white - means that coxiella does not cause a rash, IE NO RASH
4. Exaggerated horns to look like curly Q's - q fever
5. Ram is never allowed to leave the barn - Obligate intracellular organism
6. Walnuts and Animal Droppings - Transmission - spore like structure that comes in animal droppings
7. Dust everywhere from the pissed off Ram - It gets into humans through aerosol transmission - outbreaks from farm animals to farmers or placental excretions
8. Coughing and hitting head on rafter - Clinical presentation - pneumonia and headache
9. Sick Farmer sweating profusely- Fever
10. **spots on the cow resemble a liver - Also causes hepatitis**
11. Antibiotics are not needed, self-limiting
12. Prevention is pasteurization of milk
13. Hemorrhage on fingers





Pastuerella Multocidida - Louis Pasteur's Lab

1. All red - Gram Neg
2. Dog Bite - Dog and Found in respiratory tract of small animals - cats and dog bites
3. Red erythematous that happens immediately - Leads to a **cellulitis** after a bite
4. Fish Bone - May lead to a necrotizing fasciitis or **osteomyelitis**
5. Lymphadenopathy in patients with COPD or Liver disease
6. Cat - Catalase Positive
7. Blue Ring - Oxidase Positive
8. Swan neck flask inside capsule - Capsule is an important virulence factor
9. Sheep's Blood all over - Grows on 5% sheep's blood agar
10. Safety pin - Bipolar / safety pin staining similar to Yersinia
11. Pencils - Treatment - penicillin
12. Beta Lactamase inhibitor amoxicillin and clavulanic acid





Bartonella henselae – “Bart the Leopard”

1. Red Pillow – Gram negative
2. Van Goh Starry night stain - Wartharin starry silver stain needed to visualize it
3. Princess petting bart the leopard that is scratched – Cat scratch fever
4. Princess with balls around axilla - Can involve regional lymph nodes in axilla in one arm, this happens in immunocompetent
5. Prince has scratches on his arm - Bacillary angiomatosis is transmitted by cat scratches to Immunocompromised individuals
6. Red lesions on prince - Raised red vascular lesions in Bacillary angiomatosis
7. Immunocompromised cane – on prince
8. Karposi’s sarcoma is very similar and is a differential
9. Bicycle wheel – Doxycycline
10. Crow - Treatment – azithromycin for both if needed





Nocardia – No card game for old men

1. Blue Cat - Catalase Positive, an increased risk w/ CGD patients
2. Tree in the window - Gram Pos Filamentous Rod
3. Ammonia Bottle - Urease Positive
4. Air Bellow - Obligate Aerobe
5. Cowboys shawl with chaps - Mycolic Acids stain light acid fast
6. Pink Gun - Partially Acid Fast, carbofusion stain that stains mycolic acids
7. Cactus pot found broken on the ground - Found in soil
8. Cane - Immunocompromised vulnerable
9. Men – infection in men > women
10. Shooting a hole in the hat - Brain Abscess formation
11. Coughing w/ bullet hitting in the chest- Pneumonia like symptoms, Cavitating (the lung)
12. Cowprint on cowboy w/ redness - Cutaneous Symptoms - indurated lesions and inflammatory reaction
13. Eggs on the counter - Treat with Sulfonamides
14.



Actinomyces israaelii – Israeli Soldier

15. Purple Hue and tree in the background - Gram Positive Filamentous Rods
16. Pencil - Treat with penicillin
17. Gas Mask - Obligate Anaerobe
18. Bandage on head - Infection associated with jaw trauma due to normal flora of oral cavity, recent dental work – Cervical facies actinomyces infection
19. Drain with water - Formation of sinus tracts
20. Yellow rocks - Yellow Sulfur Granules



Bacteria – Gram Indeterminate



Chlamydia Trachomatis, Pneumonia, philapsittaci: the pirates of Calam Island

1. White island - Gram Indeterminate - does not gram stain
2. stuck on an island - Obligate intracellular bacteria -
3. Stuck on an island - Cannot create its own ATP which is why it is intracellular
4. "No mermaid sign" - Lack of muramic acid in the cell wall
5. Pearls outside of the cell - Elementary bodies - 1st stage of life cycle outside of the cell. This is the **INFECTIOUS** form Elementary enters the eukaryotic cell and are taken up by phagosomes. Elementary Enters
6. Pearl inside the clam - Reticulate body - 2nd stage and is active and multiply, aka the **DIVIDING** form. Reticular Replicates to form Inclusion Bodies seen under microscope in cells when infected. Reticulate Replicates
7. Pearls spread everywhere – inclusion bodies seen when under a microscope
8. Treasure chest of gems - Visualized using Giemsa stain
9. Gnats around treasure chest - Diagnose with NAAT test. Aka PCR.
10. Monkeys and pirate slapping the knee - Reiter's syndrome: reactive arthritis, cross react of antibodies fighting chlamydia hits knee or sacroiliac joint. "can't see, cant pee, cant climb a tree"
11. Symptoms of trachomatous – 3 types
    i. A-C: Blindness - Pirate is blind - Trachoma: leading cause of blindness in world
    ii. Hand shield sun from eye -Transmission: hand to eye contact, possibly from fomites

a. Mermaid at head of ship - D-K: STI
    i. **Scene takes place in water and leak in the ship - Most common Bacterial STI in US, watery discharge, Ghon has a mucopurulent discharge**
    ii. Flying the Jolley roger uterus flag - Can turn into PID w/o symptoms, ectopic pregnancies as well
    iii. Mermaid shielding babies eyes wearing a clamshell bra - Baby can get infection if mother has it during delivery giving it neonatal conjunctivitis and pneumonia. Baby will present w/ in 1-2 weeks with a possible cough (Staccato cough) or conjunctivitis. Gonorrhea will present 2-4 days

b. L1-L3: LGV
i. Mermaid w/ barnacles around inguinal region Lymphogranuloma Venerum - infection of inguinal nodes, Presents as a tender lymphadenopathy with draining lymph nodes.

12. Clam Shell bra on adult mermaid - Chlamydia Pneumonia: Walking pneumonia, more common in the elderly
13. Parrot - Chlamydia Psittaci: Transmitted by Birds, causes pneumonia and transmitted by bird droppings
14. Treatment:

a. Crows - Macrolides - azithromycin
b. Bicycle wheel - Tetracycline -
c. Confection of Chlamydia and gonorrhea treat with cephtriaxone



Gardnerella vaginalis - The fish garden - Bacterial Vaginosis

1. Purple and red graffiti - Gram Variable Rod
2. Venus fly trap eating all of the fish - Normal vaginal flora is lactic bacilli, an overgrowth of anaerobic flora will get rid of normal flora
3. Dog sniffing the white grey discharge from the vulva like Venus fly trap- Thin grayish white malodorous odorous from the vagina.
4. pH 4.5 and up sign – pH is when infection occurs
5. Dog sniffing - Positive Whiff Test w/ 10% KOH prep
6. Inspector inspecting the missing fish stain - Microscopic exam shows blue clue cells with dark blue spots, diffuse coating of bacteria
7. Metra train - Treatment - metronidazole



Mycoplasma pneumonia - "walking on thin ice"

1. No stain color - Gram indeterminate
2. No walls on the pond for the hockey game - No cell walls, like the pond, so cant appear on gram stain
3. Net with ringed structures resembling sterols - Cholesterol in the cell membrane, sterols in the membrane
4. Referee walking around with no issues - Atypical pneumonia because can't readily culture a microbe - walking pneumonia. X ray much worse than patients do clinically
5. Patchy collection of clouds in the sky -Patchy infiltrate in the x ray
6. Young players - Young adults, commonly in military recruits. Less than 30 y/o
7. Camouflage goalie <30 – military recruits <30
8. Hockey pucks that are stuck together - IgM molecules that agglutinate red blood cells in cold temperatures, lysis of RBC's
9. IgM Snowflakes - IgM
10. Do not EAT ON ice - Grown on eatons agar, "do not eat on ice"
11. Crows - Treatment - Macrolides - Zpack

Bacteria – Gram Indeterminate



Rickets Species Overview: Rickettsia Tennis

1. Everyone is wearing white - Gram indeterminate - gram neg but don't gram stain well aka **Pleomorphic**
2. **Inside of a dome - Obligate intracellular**
3. Colonize **Endothelial Cells** and cause **endothelial hyperplasia**
4. NAD+ water bottle held by CoAch - Unable to produce NAD+ and CoA, so both are important for bacterial growth and replication
5. Tennis balls - Coccobacillary Shape that are weakly gram negative
6. Weil and Felix are playing the game- Weil **Felix** agglutination test for rickettsia infections
7. Felix is holding his head and sweating – Prodromal Headache and fever in early rickettsia, along with VASCULITIS. Inflammation and destruction
8. Strings of tennis racket is bright red and broken – Vasculitis
9. Bumpy clay court - Rash
10. Treatment:
    a. Bicycle tire - Doxcycline:
    b. Chloramphenicol if pregnant
    c. Supportive care with vascular collapse

???



Rickettsia Prowazekii: Pro Boot Camp

1. Inside of a dome with white crowd - Obligate intracellular - poor gram staining
2. CoAch with NAD+ water - NAD and CoA needed
3. Rickets Tires - Doxycycline treatment
4. Football play that starts in the middle and spreads outwards - Rash starts at trunk and moves out towards the extremities
5. Uniforms that re red but no color on hands and feet or head - Rash spares the hands feet and head
6. Coach with hat military on - Affects military recruits and POW's - Close Contact allows for human to human spread
7. **Footballs are Lice - Lice** spread prowazeki, **louse feeds on blood and defecates near feeding sites** and it's the **scratching that infects patients** from the lice feces
8. "the outbreak" play - Illness is called epidemic typhus: widespread outbreak
9. Symptoms
    a. Getting tackled - Myalgia and arthralgia
    b. Getting wind knocked out of you - Pneumonia
    c. Player hit in the head - Encephalitis with dizziness and confusion
    d. Can cause COMA if really serious
    e. Unremitting Headache
    f. Patchy rash that begins on the trunk





Rickettsia Rickettsii: Rickett's Rock Climbing Competition in the **dermacenter** arena

1. **Rocky Mountain Spotted Fever**
2. Everyone in white -- stain poorly
3. Inside a dome Obligate intracellular
4. Giemsa stain
5. CoAch holding NAD+ drink - NAD+ and CoA needed and provided by eukaryotic host
6. Rickets Tires - Treatment : Doxy
7. Ticks on the side of the wall - Transmitted via ticks
8. Derma – Center arena - **Dermacenter Tick transmission** through direct biting
9. Climbers all over - Incubation period of 2-14 days causes a **Maculopapular Rash**
10. **Look at the way they are climbing the wall - Rash will start on ankles and wrists**, then moves more centrally
11. Will have headache, sever fever, and muscle pains (myalgia)





Mycobacterium tuberculosis - Shoot out at the TB Corral

1. Pink Gun leaving a pink finish - Acid fast is represented by the mycolic acids (carbol fuschien stain), ie the 2 branched tassels representing mycolic acids.
2. Lowenstein General Store - Lowenstein Medium
3. Billows - Obligate Aerobe
4. Cart - Transmission - Human to Human respiratory droplets and proliferates in macrophages
5. Cart - Macrophage Cage
6. Glycolipid are responsible for Clumping of bacteria into a serpentine formation – Virulence factor - called cord factor
7. Lasso wrapping up the driver of the macrophage cart - Cord factor will Increases granuloma formation by increasing TNF-a activating other macrophages walling itself off in a granuloma – this will protect the bacteria
8. Spurs kicking up Dust clouds behind cowboy - Sulfatides - prevent phagolysosome fusion. Allow TB to survive in macrophages by creating incompetent secondary lysosomes preventing fusion to hydrolyzes
9. Cactus with holes in the middle lobe and red cactus fruit near hilum, Gun complex - Primary infection - healed infection, Affects lungs and will form a GHON complex, visual calcification, right middle lobular, Hilar lymph node involvement.
10. Carts that are broken down - Caseation Granulomas - tubers - tuberculosis resides in broken down necrotic macrophages (Langerhans giant cells)
11. Sick Child in burlap sack- Primary infection symptoms, long fever and in children, resolves by fibrosis (burlap sack)
12. Shovel with Dirt - Test for TB with PPD, BCG vaccine will always show positive skin test
13. Millet seed pouring out of the cart and cow skull- Milliary TB – Multi-organ failure - Millet seeds from the macrophage cart - Lethal
14. Guy strapped to barrels of TNF - Latent Infection - Associated with immunosuppression through downregulation of TNF-a release
    Immune system is defenseless if TNF is inhibited. Always screen for PPD before using a TNF inhibitor like infliximab
15. Right Cactus with holes in upper lung scene takes place at night- Reactivation is on the upper lungs, look for cough, night sweats, Bloody cough hemoptysis
16. Prisoner in the MΦ cage - Reactivation occurs in macrophages
17. Coughing out blood on handkerchief - Promotes body wasting
18. Broken Pots - Pots disease is demineralization of the bone, spinal weakness,
19. Bullet hole going through the hat - CNS involvement is also seen as meningitis or tuberculoma. "Hat being shot off"
20. Treatment - combination of RIPE, rifampin, isoniazid, Pyrazinamide, ethambutol
21. Prophylaxis - Rifampin or isoniazid - 9 months





Mycobacterium Leprae - The good, the bad, and the lion faced

1. Thrives in cool temperatures leading to growth in extremities
2. Acid Fast Gun slinger - Acid fast, carbol fuscion stain
3. Tassels on coat and jacket - Mycolic acids
4. Armadillo County - Armadillos are the major reservoir - commonly called Hanson's disease
5. Hanson the Armadillo – Hanson's Disease
6. Clinical presentations
    a. Tuberculoid # 1
        i. Jail Cell 1 - Helper TH1 cells stimulate macrophages to engulf the bacteria in cell mediated immunity
        ii. Well demarcated bald spot - Mild symptoms, well demarcated hairless lesions on skin
        iii. Shovel in mound of dirt - Lepermans skin test - test for immune reaction, similar to TB Test, wheel will form if positive
    b. Lepromatous presentation #2
        i. Jail Cell 2 with laughing prisoner- TH2 cells promote humoral (humorous) response
        ii. Prisoner breaking out of cage - Bacteria being unable to contained in macrophages
        iii. Touching each other - High chance of transmission human to human
        iv. Prisoner are wearing glove and stockings - Distal portions are affected in a glove and stocking pattern
        v. Extensor surfaces w/ patches - Numerous extensor surfaces are cooler and present with disease of demarcated lesions
        vi. Mask on the gunslinger - Leonine faces, facial deformity.
7. Treatment - multi drug therapy for long time
8. Deputy carrying a rifle - TH1 Dapsone and rifampin for 6 months (deputy and rifle)
9. Deputy with rifle and white cloth, and cloth escape rope - TH2 Dapsone, rifampfin, and Clofazimine for 2-5 years





Borrelia burgdorferi: the bows and arrows of borrelia

1. Spirochetes - helical and longer than Treponema
2. Causes **Lyme disease**
3. Forest and the NORTH EAST archery competition - Primarily in the northeastern united states.
4. Tick on the sign, Robin of Ixodes - Transmitted by ticks, **Ixodes scapularis**. Which also transmits erliciosis, bubesiosis
5. Life cycle
    a. Mouse – ticks larvae feed on white footed mouse, Main reservoir
    b. Deer – adult form feeds on white tailed deer, Obligatory Host
    c. Tick is the vector, humans are an incidental host
6. Spirochetes **do not gram stain**
7. Wright and Giemsa competitors wearing lime green - Two stains that can be used, **Wright and Giemsa Stain**
8. Two types of the disease
    a. Endemic Relapsing Fever is caused by tick borne borelia hermsii and Borelia duttonii
9. Symptoms
    a. Stage I
        i. "Stage 1" with bulls eye with spiral arrow - Erythema **Chronic Migrans "Bulls Eye" rash**, Spirochete
        ii. Sir Wright is sweating and looking feverish - sweating and feverish, flu like illness
        iii. Papule will form (Ixodes tick)
    b. Stage II
        i. "Stage 2" with heart and 2 bells - <u>Heart block</u> cause by myocarditis, Bilateral facial nerve **Bell's palsy.**
    c. Stage III
        i. "Stage 3" straw man swinging in front of the target - Joint pain arthritis of large joints, symptoms may move from joint to joint. <u>Migratory arthritis</u>
        ii. Arrow in the head and Sir Giemsa is confused - <u>Memory difficulty</u>, lymphocytic meningitis. Suttle <u>encephalopathy</u>
10. Treatment
    a. Bike wheel - Stage 1 doxycycline,
    b. 3 axes - stage 2 ceftriaxone



Treponema Palladium - Pallidum Observatory

1. **Spiral shapes - Spirochetes - Spiral Organisms - Microaerophilic cannot be grown in culture, only in rabbit testes**
2. Transmission
    a. Sexually Transmitted Disease
3. **Dark field galaxy - Dark field microscopy** is needed for direct visualization of the organism.
4. Main screening Test
    a. Video display - Venereal Disease Research Laboratory - VDRL -screening test for Treponema but not specific.
    b. RPR - rapid plasmin reagent, high incidence of false positives due to cross antigenicity
5. Confirmatory Test
    a. Telescope - FTA ABS is a Specific test to confirm a positive screening
6. Clinical Presentations
    a. Early Stages
        i. Sundial poking in the butt - Primary: Painless genital chancre, syphilis locally invades small blood vessels causing ischemic necrosis and takes out nerves making it painless. Painless: heals in 3-6 weeks
        ii. Lower level, Solar system, astronaut with red hands and soles of feet, bumpy exterior of the planet - Secondary: Systemic Disease, maculopapular rash that occurs on palms and soles of feet months to weeks after infection. Condoloma Latta, a lot of bumps that are flat topped. Can visualize the spirochetes in the condoloma lata vis dark field microscopy
        iii. Cratered moon signifying gummas, tree that looks like an aorta -Tertiary: formations of Gummas which are soft growth with a firm necrotic center. Aortitis, leading to an ascending pathologic aneurysm. Tree barking. Destroys the vasovasorum or blood supply of the aorta.
            1. Columns in the back that are cracked and damaged - Demyelination of nerves and posterior walls of the spinal cord and lead to a loss of proprioception and other neurological issues.
            2. Greeter wearing argyle sweater with kid shining light into the eyes - Prostitutes pupil - Argyle Robertson: Ocular effects that make pupils that accommodate to distance but do not react to light. Prostitutes Pupil… ha-ha
    b. Constellations - Congenital Symptoms
        i. Saber Shins, an anterior bowing of tibia
        ii. Saddle shaped nose
        iii. Kids chattering teeth - Hutchinson teeth which are notched incisors or mulberry molars
        iv. Ear muffs - Deafness
7. Treatment - Penicillin, if allergic - desensitize them and use penicillin
8. Sign directing students - Jarisch Herschimer reaction is the dying spirochetes releasing a bunch of cytokines that make people feel sick along with fever and chills.





Leptospirosis: The Surfers Oasis

1. Question mark on the board - Spirochetes may be question marked shaped
2. Surfing in the water - Water sports,
3. Yellow tide - water contaminated with animal urine'
4. Surfer rubbing his eyes, rose colored sunglasses and dripping wet - Fever and conjunctival suffusion redness around the eyes without the puss
5. Hawaii - Tropical regions
6. Water
7. Whale – Weil's disease
8. Inner tubes that look like RBC's – travels in blood stream
9. Rubber dingy shaped like a kidney - Renal dysfunction
10. Yellow suit - jaundice from live damage



Histoplasma capsulatum: The Historians Cave

1. Bird or Bat droppings in a cave – Location of exposure. Mississippi and Ohio River valleys. Midwestern US
2. Histoplasmosis Indiana jones - Indiana area "His on the Miss"
3. Coughing: transmission through respiratory.
4. Macrophage Cage and puddles - Macrophages w/ intracellular oval bodies. Canary just a reminder about the cave
5. Red Stalactite and yellow Stalactite: Diagnosis through KOH or rapid serum (red) or urine (yellow) antigen test
6. Puddles with Ovoid bodies – what it would look like on histological size
7. Many ovoid bodies inside of the puddle - Histoplasma much smaller than RBC
8. Dimorphic Butterfly - mold in the cold and yeast in the beast
9. Historian Coughing and lung symbol in the background w/ white stalactites: Pneumonia
10. Stalactites and TB Wild West scene - granulomas, can look like TB w/ calcified nodes and nodules in the hilar region.
11. Book w/ TB symbol: looks like TB
12. Long Legs: erythema nodosum
13. Cane Associated w/ immunocompromised cave drawing of bull w/ liver and spleen: disseminated to liver and spleen because fungus targets the reticuloendothelial system that has a lot of macrophages these are prevalent in the liver and spleen. Causes hepatosplenomegaly
14. Pine cones and Frogs - TXT: -Azole drugs, and systemic infections AMP B

2-5ym (smallest) with "a thin cell wall but no true capsule" (think inside the puddles)



Coccidioides immitis – Presidio San Joaquin

1. Presidio rhymes with Cocciodioides
2. Map on the statue – Location for coccidioides
3. Dust storm and fault line - Route of transmission is inhalation, very common after earthquakes
4. Dimorphic butterfly: Mold in the cold, Spherule of endospores in the body. Not yeast
5. **Tumbleweeds: Spherules packed with endospores in the lungs instead of yeast when in the body**
6. **Red sombrero -** spherules are bigger than RBC's
7. Clinical: Asymptomatic in most, or may look like the
8. Soldier: kneeling (Knee pain), Cough (pneumonia), and fever
9. Cracks on adobe wall in the shape of the lungs: Radiographically images may be unremarkable with nothing showing or there may be some cavities (bricks facing in) and/or nodules (bricks facing out)
10. Pillars on the presidio resemble shins: represent that the cocci is associated with Erythema Nodosum (robust immune response)
11. Statue with immunocompromised cane: cracks and lesions in lungs show common sites of infection, rod in leg show that it goes to the bone,
12. Soldier with neck brace - can also go into meningitis
13. KOH stain to prove, IgM against cocci indicates recent infection
14. Pine Cones - TX: local lung infections - azole drugs (conozole pine cones)
15. Frogs - Systemic: Amphotericin B (the frogs)

20-60ym (largest)(bigger than tumbleweed) nonbuding spherule filled with endospores



Blastomycoses dermatidis – the blast of the cannon

1. Map - Geographic distribution of Blastomycosis generally matches the locations of civil war battles, southern and southeastern United States. **Buzz word "Great lakes and Ohio River Valley"**
2. Valley and River should remind me of Ohio River Valley
3. Dimorphic Butterfly: Mold in the Cold and Yeast in the Heat, Dimorphism.
4. Cannon firing: the smoke represents the transmission of spores via inhalation which is why the soldier on the side of the cannon is coughing.
5. Cannon Balls fused together in pairs - Broad Based Budding, commonly seen on slides, **Blasto is typically the same size as RBC's**
6. Cracks in the valley looks like lungs with dust: Blastomycosis on chest X-ray has patchy alveolar infiltrate
7. Landing sites of cannon balls represents lesions in the lungs
8. General Lee holding a cane: Cane represents immunocompromised leading to systemic infections
9. chunks missing mean systemic infection,
10. iron rod symbolizes bone involvement osteomyelitis, Damages skin and bones, Robert E. Lee represents southern United States
11. Yellow river: Can be detected with a KOH prep, or also with a **Urine Antigen test**.
12. Txt for blasto: immunocompetent - Iitraconazole, Systemic infection Amphotericin B



Paracoccidioides brasiliensis – Piratas **del Sur (south)**

1. Treasure map hanging on the wall – location of <u>geographic distribution</u>
2. **Captains Wheel** - Paracocci and yeast forms that are multiple buds radiation out in a central pattern. Rounded and bulbish shape, how it looks in the lungs
3. Dimorphic Butterfly –mold in the cold, yeast in the beast
4. Red in the center of the captains wheel – general of size compared to rbc
5. Captain is coughing – major symptom and transmission through respiratory droplets
6. White beads **– lymphadenopathy** in chains op lymph nodes in cervical region
7. Medallions hanging over the lungs – Granulomatous nature of the disease
8. Really bad teeth - **Mucosal ulcers and cutaneous** lesions in the upper mouth leading to small hemorrhages
9. Pine cones and Frogs – txt – itraconazole and amphotericin B

10-60ym yeast with multiple budding (ship wheel)



Malessezia Furfur - Malassezia's Italian Restaurant – causes Pityriasis versicolor

1. Versi di colore sauce - versicolor in Pityriasis versicolor
2. Woman wearing a Fur Coat reminds us of Malessezia FURFUR
3. Spaghetti and Meatball appearance on KOH prep of Skin scrapings, KOH salt for KOH prep
4. Heat lamps - Malasezzia thrives under hot and humid conditions, and the fungus will convert to disease form with humidity.
5. Chef is sweaty – Mallessezia likes humidity
6. Light and dark colored patches of sauce on chef back and chest- Forms patches on the back and chest of individuals
7. Brocken Bottle of Olive Oil - Lipid degradation builds up acid that will cause damage to melanocytes causing loss of pigmentation
8. Lasagna w/ Corn - demonstrates that the stratum corneum is the layer that is damaged (top layer of skin)
9. Baby slurping Spaghetti - Malessezia fungimia may come with TPN, total parental infusion, fungus will grow in the catheter of lipid transfusions causes sepsis and thrombocytopenia.
10. Blue stained glass window - Selsum blue - Selenium Sulfate - txt for malassezia furfur



Sporothrix schneckii – Shanked by a rose

1. Trees and Greenery –Found in rose thorns, tree bark and other plants
2. Causes Sporotrichosis - Commonly caused by cuts from a rose bush, commonly called rose gardeners disease
3. Trees on the left represent that sporotrix is commonly found on tree bark, bushes, and plants
4. Butterfly - Dimorphic fungus
5. Branching rose stems - represent branching hyphae of sporothrix at 25C
6. Rose Buds are Cigar shaped and represent rose buds disease
7. Cigar - represents cigar shaped yeast.
8. Vines ascending the wall and Roses wrapped around the arm - Sporothrix is usually introduced into the skin by a local trauma that will lead to a pustule or nodules and then will develop an ascending pattern along the lymphatics causing red bumps along the skin. (SPOROTRICHOSIS)
9. Biopsy yields **cigar shaped budding yeasts**, multinucleated giant cells, histiocytic
10. Pine cones on the ground - Iitraconazole, txt for lymphocutaneous sporotrichosis
11. Spray Canister pesticide - Potassium solution of potassium iodide is used to txt lymphocutaneous sporotrix.



Dermatophytes – Tinea Tin Man – Fungi that cause Tinea

Dermatophytes - represented by the T, E, and M on the little Munchkins chest. No clothes because they live on the skin, the name dermatophyte means Skin Plant in Greek.

1. Three Little Munchkins with T, E, and M. Trichophyton, Epidermophyton, Microsporum
2. Rings of rust on the tin man are meant to look like tinea infections. Why it's called ringworm.
3. Tinea Capitus: found on the head
4. Tinea Corpus: Found on the body
5. Tinea cruris: found on the groin (Crura is the structure that connects the base of the penis to Ischeal pubic rami)
6. Tinea pedis: found on the foot
7. Athletic Head Band - Athletes are most at risk, swimmers and wrestlers.
8. Todo - Animals are also a source or infection
9. Tin man scratching – itchy
10. KOH salt shaker: means you can see the hyphae on KOH prep of skin scrapings
11. Lamps in the Woods: Can also use the **Woods lamp to diagnose the microsporum** because they illuminate them.
12. Pine cones: used to txt generally -azoles.
13. Wizard of Oz - Onchomycosis: dermatophyte infection of the nails.
14. Turban - reminds us of terbanifine which is used to txt
15. Wizard holding a can of grease - Griseofulvin is used for more serious dermatophyte infections. (GI SE's)

Fungi – Opportunistic Fungi



Aspergillus fumigatus – Asparagus Farm

1. Cat on scarecrow - Catalase Positive
2. Peanut plant in the front – Peanuts are associated with **aflatoxins produced by Aspergillus flavus**
3. Wheat field – aflatoxins associates with grain
4. Cow with liver and Crab on the tractor - Hepatocellular carcinoma
5. Plant has acute angles and septations – Aspergillus is Acute branching with septations ASpergillus
6. Fruiting bodies on the peanut plant - Condiophores with fruiting bodies, those will be inhaled by humans
7. 3 types of infection
    a. Crop duster with Sweaty, running, farmer running with inhaler below- Allergic bronchopulmonary aspergillus (ABPA), causing wheezing, fever, and a migratory pulmonary infiltrate.
        i. Inhaler says IgE on it - Type I hypersensitivity, IgE response
    b. Farmer that is coughing with a handkerchief and TB Cactus – Susceptibility increases with TB cavities. Aspergillosis causing aspergillomas
        i. Peanuts under the ground - Aspergillomas are gravity dependent so fungus balls will be at the bottom of the cavity
    c. Farmer on the right w/immunocompromised cane – Angioinvasive aspergillosis - Patients with neutropenia from leukemia or lymphoma –
        i. Red sprinkler system throughout the crops - invades blood vessels and the surrounding tissues
        ii. Scarecrow with a straw heart, kidneys, and black dots on head, black dot on nose – Kidney failure, endocarditis, ring enhancing lesions in the brain. Invades nasal sinus
8. Pine cones and vortex – Voriconazole for less serious infections
9. Frogs – Amphotericin B for angioinvasive disease

Fungi – Opportunistic Fungi



Candida albicans – Candid Canadians

1. Canada Flag – Candidia
2. Most common cause of opportunistic mycoses
3. Dimorphic Butterfly – Pseudo hyphae at 25c and true Hyphae germ tubes at 37
4. 37 flavors snow cone booth with 1 straw snow cones – Candida forms germ tubes at 37c
5. Canadian shrubbery with 20c thermometer and snowballs – at 20c candida is in yeast form with pseudo hyphae formation
6. Cat – catalase positive, CGD patients are especially susceptible to this
7. Normal flora of GI tract and Oral cavity, commonly contaminates sputum cultures
8. Crying baby in red swing – Sever diaper rash, when exposed to heat and humidity
9. Old man with cane and Boy with inhaler – oral candidiasis usually in immunocompromised or used with inhaled steroids.
10. White patches in boys mouth and adult in background shoveling snow and KOH – can be scraped off, KOH is used to prep plates
11. Cartoon tube slide with white patches of snow – esophagitis and white pseudo membranes caused by candida
12. Max 100 CD4 - Aids defining illness at CD4 of 100
13. School teacher getting hit in crotch– Vaginal candidiasis

a. Jar of candy – diabetics
b. Prescription pills – antibiotics can predispose yeast infections due to lowering pH
c. Birth Control Pills – also succeptible

14. Playground open until 4pH – Candida infections don't happen after 4pH
15. Hearts on roof of slide - Candida can cause endocarditis
16. IV drug users are at increased risk - Candida found in certain types of heroine that infects tricuspid valve
17. Pine cones – Azoles for minor infections
18. Frogs – Amphotericin B for major infections
19. Play Nyce - Nystatin for oral or esophageal candidiasis
20. Winter cap on immunocompromised man - Capsofungin for resistant candida

Asthmatic kids that don't
rinse mouth after use (boy inhaler)



Cryptococcus neoformans – Crypt for Cryptococcus

1. Mummy sarcophaguses – Cryptococci are heavily encapsulated
2. Repeating pattern of circles on sarcophagus – repeating polysaccharide antigen that is the main virulence factor for making it antiphagocytic and basis for the diagnostic test
3. Pigeons pooping everywhere and archeologist is coughing - Transmitted by pigeon droppings and found in soil – then inhaled into the lungs
4. Ammonia spray bottle – urease positive
5. Mummy holding a cane - Opportunistic infection, **HIV**, High dose steroids, Malignancies
6. Archeologist coughing - Pulmonary symptoms – cough, dyspnea, and other lung infections
7. Neck brace - Spread to CSF and cause meningitis, this is no Bueno and very often will lead to permanent neuro deficits
8. Archeologist sweating – fever
9. Red and silver sarcophaguses - Bronchopulmonary washings of lung tissue that resemble soap bubbles, tissue samples can be stained with mucicarmine red or methanamine silver stains
10. Bubbling tar with skull - Diagnose by lumbar puncture then use India ink, and will have wide encapsulated halos
11. Latex gloves near repeating pattern - Latex agglutination test that detects polysaccharide antigen and causes agglutination
12. Soap bubbles on the mummy - Distinct pathology of the brain having soap bubble lesions
13. Flute player, frogs, and pine cone - Treatment joint therapy with ampho B and flucytosine, then fluconazole after

4-10ym yeast with a broad, slimy capsule



Mucormycoses – Mu Car Auto Shop

1. Cain – Immunocompromised
2. Jar of candy – Diabetes patients are susceptible
3. Baguette – Rhizopus is a bread mold
4. Mechanic is coughing from fumes in exhaust pipe - Transmitted via spore inhalation
5. Ketone auto parts - **Diabetic Ketone acidosis** predisposes infection of this fungus
6. **Tire iron - Hyphae are non-septate and have 90 degree angle branching**
7. Red jumper cables - Fungus like to proliferate in blood vessels
8. Oil pan that has several holes it is leaking through - Invade through cribriform plate in the skull then will continue to cause necrosis of tissues and frontal cortex abscesses
9. Mechanic with oil dripping on face – will present as a black eschar and necrosis of nasal cavity and eyes, causing neuro deficits and death
10. Treatments – debridement first
11. Frog car – Amphotericin B
12. Biopsy is needed for diagnosis



Pneumocystis jiroveci – PCP Ping Pong

1. Aid for Aids – Associated with Aids CD4 counts below 200
2. 20-0 – CD4 counts below 200
3. Immunocompromised Cane player and young player – Symptoms are evident in immunocompromised individuals
4. Cracked glass ping pong tables - Will have a ground glass appearance in both lungs
5. BAL water bottle - Broncheolavar lavage for diagnosis
6. Silver discs on the table and ovoid ping pong balls - Methamine silver stain to identify fungus that looks like disc shaped yeasts
7. Backhand, and the jar of ping pong sulfa bottle- Prophylaxis begins when CD4 count is below 200, Bactrim (TMP/SMX)
8. Pentagon paddles – Pentadamine can be used with sulfa allergies

Opportunistic in premature infants



Entamoeba histolytica – Entering the Historical Dig

1. Red stool - Bloody Diarrhea
2. Do not **ent**er **hist**orical site – Entamoeba Histolytica
3. Liver shape –
4. 2 main life cycle stages
    a. Bubbles in a puddle – Cyst form ingested from contaminated water
        i. Men drinking water holding hands – gay men get disease from anal oral transmission
    b. Liver shape dig site and hole in right side of liver – Right lobe is most common involved site of amoebic liver abscess
        i. Map is a ct scan of liver and a man holding his right upper quadrant – RUQ pain w/ enlarged and tender lover
        ii. Anchovy paste truck - Abscess described as having “anchovy” paste consistency
5. Sewer pipe w/ out pouches like haustra to represent the colon - Causes intestinal amebiasis
6. Rust spots - Can cause ulcerations along the colon
7. Erlenmeyer flasks - Flask shaped ulcers
8. Red stools – bloody stool
9. Puddle w/ floating red cups - Stool O&P looking for cysts or trophozoites, stool will contain **trophozoites that contain endocytosed RBC’s**
10. Flask in colon - An elisa antigen test or serology
11. Metra – Metronidazole
12. Drugs that work in lumen of intestine
    a. Pair of mice near metro - Paramycin
    b. Sign labeled queen iodos tomb – Iodoquinol



Giardia Lambia – Giardia Jungle Ride

1. Poop in water and bubbles - Amongst travelers or campers drinking unfiltered or unpurified water that contains cysts of giardia from feces
2. Backpacking backpacks – remind of backpackers and campers
3. Campers holding noses - Bloating, flatulence, and foul smelling diarrhea
4. Yellow stool - Steatorrhea (fatty diarrhea) due to excessive mucus production that impairs absorption of intestine (A,D,E,K will be deficient)
5. Shields on the boat - Trophozoite form that is flagellated
6. Shields in the water and OP guy pointing at the water - Attach but do not invade intestinal wall, so only cause diarrhea. If found in stool they are diagnostic
7. Elisa stool antigen to detect
8. Metra – Treat with metronidazole



Cryptosporidium – Tales from the Crypt

1. Brown water - Aids patients Cryptosporidium causes profound diarrhea
2. Immunocompromised cane – HIV Population
3. Red poncho and cowboy hat - Unicellular partially **acid fast** creating oocytes released fecally and absorbed orally
4. Bubbles – infectious cysts that get passed through watery stool
5. Gems scattered in water (amethyst) – acid fast and under staining looks like amethyst in water
6. Small Broken pipe in background - Cysts contain 4 motile sporozoites that will attach to small intestinal wall and cause damage.
7. Knitted sock – nitazoxanide treatment in immunocompetent
8. Water dripping out of sock – oocysts can be removed via filtration
9. Spirit crow – spiromycin txt (not FDA approved in US)



Toxoplasma gondii – Oh Hi, IZ makin sum Toxo

1. Crazy cat lady kneeling down taking a picture – Pregnant women at risk due to transplacentel transfer
2. Transmission – consumption of raw or undercooked meat containing tissue cysts, water contaminated with oocytes shed in the feces of infected animals, through placenta from mother to fetus in utero
3. Kitty litter box - Pregnant women should not change kitty litter box
4. Eggs in box – oocytes can also cause transmission
5. Immunocompromised cane on poor wrinkly cat w/ rings on glasses – HIV are at risk, toxoplasma will cause ring enhancing lesions on MRI.
    a. Red encephalitis turban – toxoplasma encephalitis
    b. Large pin – biopsy needle to differentiate from CNS lymphoma
    c. Bubbly looked meat – cysts in undercooked meat
6. Clinical symptoms – fly in healthy people
7. Cat with a torch – one of the TORCH infection that can cross transplacental barrier
8. Cat drinking milk and is on head – brain calcifications, cranial calcifications
9. Shaking off bowl – seizures
10. Bowl of water on cats head - hydrocephalous,
11. Giant flash bulb looking like fundus – Chorioretinitis
12. Cat dressed like Beethoven – deafness (Beethoven was deaf)
13. Sulfa dyed eggs – Sulfadiazine
14. Pyramid shapes on eggs – pyramethamine
15. Benjamin franklin w/ $100bill - Prophylaxis when CD4 counts less than 100 when positive for IgG for toxo
16. Kite w/ Key – positive for IgG
17. Sulfa egg under Benjamin franklin – TMP/SMX for prophylaxis



Trypansoma brucei gambiense and rhodesiense – Prince Bruce to the Rescue

1. Princess PTFO – sleeping sickness
2. Teapot an cup of tea – tiny fly – Tsetse fly vector from Africa
3. Map of Africa – gambia and rodesia locations
4. Ruffles on shoulder and pearl necklace - After biting the parasites move from blood to lymph nodes causing cervical and axillary lympaenopathy
5. Rolling undulating fevers - Recurrent fevers
6. Sleeping sickness is a problem of CNS an Spinal fluid
7. Tickle of blood holing a goat - from finger tip trypomastogotes on blood smear for diagnosis
8. Multicolor tents – variable surface glycoproteins coats undergoing constant antigenic variation leading to recurrent fevers
9. Single pink ribbon in hair - Motile w/ single flagella
10. Prince bruce holding some serum an soap – Melarsoprol for CNS infection, Suramin treatment for blood infection



Naegleria Falls – Naegleria fowleri

1. Niagra falls and fresh water – Associated with fresh water
2. Barrel ride down the falls in cribs– High Mortality due to entry through the cribriform plate
3. Barrel rider on ground w/ neck brace and red turban - Causes primary amoebic meningoencephalitis
4. Dead guy – High Mortality that's rapidly fatal
5. Happy go lucky wind surfer – association with water sports
6. Water bottles - Nasal irrigation bought over the counter may have nigleria as well. (stagnant water)
7. Corkscrew that looks like a spinal needle - Lumbar puncture to diagnose
8. Frogs – Amphotericin treatment



Trypanosoma cruzi – Cruizin' through Che's gas

1. Located in South and central America – like Che' Guerva
2. Gas station Che's gas – Chagas disease
3. Guy kissing GF – from kissing bug 's feces - Tunnels into tissue and feeds on blood an lymph of its victim, T. cruzi is transmitted through the vector, reduvid bug, an gets in when the victim scratches the infected area.
4. Large bugs on the bottom – transmitted by reduviid or kissing bug
5. Infection may be asymptomatic, but 10-20 years later Chagas disease may set in.
6. Gas tank w/ large intestine that's swollen – Megacolon w/ extreme constipation
7. Saddle bag shaped like a heart – dilated cardiomyopathy
8. Snake recently fed and sunning itself – megaesophagus
9. Blood on ground - Diagnosed by blood smear during an active infection
10. Red bug on heart bag – red for reduvid
11. Mole on the right - Burrows into endocardium
12. Knee high furry moccasins - Nifurtimox treatment



Babesia – The Vampire Babes

1. Blood related symptoms, and blood red stained glass windows that are broken – Blood related symptoms, more specifically hemolytic anemia
2. Coat of arms with shield tick and antlers - Ixodes tick, the longer the attachment, the more likely the babesia infections. Found on deer
3. Yellow vampire babe – Hemolytic anemia can lead to jaundice
4. Robin of Ixodes – Ixodes tick
    a. Sweating – fever
    b. Torn sweaty shirt – irregularly cycling fevers
    c. Sickle – Higher risk of severe disease in sickle cell disease
    d. Hole in tunic – asplenia
5. Blood on the floor with maltese cross– Babesioisis diagnosed by a thick blood smear
6. Maltese cross – appearance in red blood cells.
7. NE on cross – predominance is in the North east US
8. ATOVA and crows – Atovaquone and azithromycin

Scarcely symptomatic

Parasites



Plasmodium malariae, Plasmodium vivax, Plasmodium ovale, and Plasmodium falciparum – The queens and warlords of Plasmodium

1. African wilderness – Plasmodium location
2. Box of gems – Blood smear Giemsa stain for diagnosis
3. 4 Warlords – different plasmodium species
4. Bad smelling warlord – **Plasmodium malariae**
5. Buttons – quartan fever cycle, fever is highest on days 1 and 4
6. Warlord with shield and axe – **Plasmodium vivax and ovale**
7. Swinging balls – produce dormant hypnozoites in the liver
8. Cowhide w/ liver spot on shield – Liver
9. Every other circle on the balls - Tertian fever
10. False mask - **Plasmodium falciparum**
11. Torn shirt – irregular fever pattern
12. Red headdress, gold chest plate and belt - Neurologic symptoms as parasitized RBC occlude the brain, kidney, and lungs.
13. Headdress looks like bananas – Banana shaped under microscopy
14. Color queen – Chloroquine – Blocks plasmodium heme polymerase
15. Primal queen – Primaquin w/ Chloroquine for hypnozoites in the liver, be careful w/ G6PD deficiency
16. Me fly queen in palanquin – Mefloquine – for Caribbean
17. Top of palanquin w/ backpacks – prophylaxis for Caribbean travelers
18. Ato-vampire queen in palanquin and iguana, backpacks– atovoquone w/ proguanil for travelers in caribbean
19. Artist painting a picture of ato vampire queen - Artimesians to txt P. falciparum w/ atovaquinw
20. Sickle cells in artists hand – these drugs used to txt sickle cell anemia patients
21. IV artesonate for severe malaria infections
22. Dining queen w/ tin cans – quinidine for resistant P. falciparum, can cause cinchinism.
23. Ivy wrapped around arm – IV delivery
24. Cow with liver spot, mushrooms – Anopholese mosquito carry sporozoites in saliva, bites human host and mature to trophozoites in liver, then divide into merozoites which burst from hepatocyte and infect RBC's. life cycle continues in RBC's.
25. Ring shape – immature form has a ring form Merozoite can also form a gametocyte



Leishmania donovani and baziliensis – Desert Mania

1. Man coming out of sand wearing green – Leshmania Braziliensis – vertebrates are hosts
2. Green suit – Cutaneous leishmaniosis – zombie character leading to cutaneous leishmaniosis
3. Sand fly's – vector of leishmanial
4. Macrophage cage and goats inside (amastigote) - Transmission – flies carry the promastigote and becomes an amastigote in the host that ends up in the macrophage
5. Purple spots on animals – purple stained nuclei are filed with tiny stained nuclei of amastigotes infect Spleen, skin lesions
6. Guy on bottom (Donavon) w/ hyper pigmented spots – Black fever, aka visceral leishmaniosis caused by leishmanial donovani – 100% fatal if left untreated
7. Pan filled w/ partially eaten meat looking like RBC and Platelets – Pancytopenia caused by Leishmania donovoni
8. Cow w/ liver and spleen spots – hepatosplenomegaly
9. T-Bone steak – Stibogluconate for cutaneous leishmaniosis
10. Frogs – Amphotericin B for visceral leishmaniosis



Trichomonas vaginalis – Tricks for Money

1. Master Magician pulling strawberry out of hat – Causes cervicitis that a speculum reveals a super red color due to vascular perfusion and punctuate lesions
2. Hat opening – shaped like a cervix
3. Burning fire, homeless lady itching, green color everywhere - Burning, itching, and malodorous yellow green discharge
4. Moving Car rounding the corner splashing water - Diagnosed with a wet mount showing motile trophozoits
5. Vagina paintings artist - pH of vaginal fluid 4.5 and up with infection
6. People kissing - Sexually transmitted infection, treat both partners
7. Metro – metronidazole

Parasites



Enterobius vermicularis Ancylostoma and necatar ascaros lumbridcoides strongyloides stercoralis trichinella spiralis

1. **Vermine lady – Enterobius vermicularis (pinworms)**
2. Round hole – female worms migrate to anus and lay eggs.
3. Rats eating the rocks – fecal oral route
4. Tape cape - Diagnosed with scotch tape on anus, eggs deposited will stick to it. Visible on microscope
5. PAM! - Treatment – Pyrantel pamoate
6. Bent metal bars – treatment – Albendazole
7. **American Dude – Ancyclostoma duodenale and Necator americanus**
8. Grappling Hook and red boots - Hookworms Found in rural southern US that ended the blood stream when you walk barefoot.
9. Arrow pointing up to lungs then GI tract - The larvae will go straight to the lungs and ascend to bronchiole tree and then get coughed up and mature in the intestine
10. Iron hanging - Can develop severe iron deficiency anemia
11. Round grenades in water – look for eggs in stool
12. Eo slingshot boy - High eosinophil count
13. Pyrantel pamoate and albendazole as TXT
14. **Lumberin tree man Ascaris lumbricoides** large worm
15. Spandex suit w/ reverse arrow - Eat the eggs and then they migrate to lungs through gut wall and blood stream then come back to gut to become adults then go into feces.
16. Leaf on chest that looks like bronchiole tree - Malnutrition and respiratory symptoms.
17. Lumber man blocking the tunnel - Intestinal instruction at ileocecal valve
18. Eggs in puddle and eoslingshot granules – eggs in water and eosinophilia
19. Txt w/ albendazole
20. Don't give microtubule inhibitors to pregnant women
21. **Strong Guy – Strondyloides stercoralis**
22. Big red boots – penetrate skin on bottom of feet, then goes to lungs then gi tract
23. Round rocks in the hole he kicked - Autoinfection of host by laying eggs on intestinal wall
24. If immunocompromised can lead to hyper infection
25. Larvae in the puddle - Eggs don't get passed to stool so only find larvae in stools
26. Pink granules – eosinophilia
27. Txt albendazole
28. No dumping drains to river – Ivermectin
29. Porky trickster – spirals – trichinella spirals
30. Found in pork or bear
31. Large red glasses – periorbital edema
32. Sweating and green vomit– vomiting and fever
33. Round things on wall - Form cysts in striated muscle cells
34. Fire – inflammation of muscle

Eosinophil granules – eosinophilia



Tissue Nematodes – Dracunculus medinensis, Onchocerca volvuluv, Wucheria bancrofti, Toxocara canis, Loa Loa – Screamatodes III: return of the Flesh eaters

1. Dracula: **Dracunculus medinesis**
2. Water cooler: D. Medenensis transmitted by water contaminated with copepods containing larvae
3. Stack of paper cups – copepod design – larvae in copepods
4. Untied shoelaces with red ulcers - Diagnosed via worms coming out of the skin
5. Treatment – pull out with spinning matchsticks
6. Phil with eosin slingshot – peripheral eosinophilia
7. Fly guy – **Onchocerca volvulus**
8. Stains on lab coat and pants - Black fly bite human host and the larvae burrow down into the host and make micro filarial that come back out making hyper and hypo pigmented spots
9. Human hand covering eyes - Can cause blindness (river blindness)
10. Stray pink granules – eosinophilia
11. Microscope- Microfilaria on skin biopsy under microscope
12. No dumping drains to river – Ivermectin for txt
13. Witch - **Wucheria bancrofti**
14. MC Hammer Pants – Elephantiasis
15. Ruffled collar and around armpits – Lymphadenopathy
16. Coughing – Microfilariae travel to the lungs and cause hypersensitivity reaction
17. Mosquitos around the witch - Mosquito is intermediate host
18. Thick blood smear on hat – Organisms seen on thick blood smear
19. Stray granules around witch –Eosinophilia
20. Diet and carb magazine – Diethylcarbamazine
21. Wolfman – **Toxicara canis**
22. Stinky dog poop bag - Transmitted from dog or cat feces
23. Covering eyes - Parasitic larvae never mature out of larvae stage and never mature, can get into eye and cause blindness
24. Pink granules – eosinophilia
25. Bet chairs – albendozole
26. Swamp creature – Loa Loa
27. Bumps along legs - Transient angioedema, localized subcutaneous swellings
28. Worms wriggle across the eyeball – African eye worm
29. Blood on face- Diagnose with blood smear
30. Flies – transmitted by deer flies
31. Pink granules – eosinophilia
32. Diet and carb magazine - Txt with diethylcarbamazine
33. Bent chairs - albendozole



Cestodes: Tapeworms – Cestode County Carnival

1. Tents: **Tinnea Soleum and Sagginatum**
2. Cattle w/ saggy tent and Pig w/ sun (sold sign): Intermediate for solium is the pig and intermediate for Sagginatum is the cow
3. Hooks on Pigs tent: Hooks on proglottid heads of T/ Solium seen on O&P
4. Cows or pigs on carousel: Neurocysticcercosis, found in tinea eggs found in poop water
    a. Poop water – tinea eggs found in Poop water
5. Girl in cheese stand: seizures and neurocysticsarcosis looks like swiss cheese on MRI found in immigrants or farmers. Lesions in brain (neurocystosarcosis), eyes, and skin. Ingestion of eggs lead to cystosarcosis. Symptoms of hydrocephalous
6. Cheese wheels – Ingestion of eggs leads to cystocarcosis
7. Pretzel stand in front: TXT is Paraziquantal
8. Circus sign with strong man named “Al” bending a bar: neurocystisarcosis is treated w/ abendozle
9. Guy running to the bathroom: **Diphyllobothrium latum** - Fish Tapeworm
10. Must B12 to buy fireworks: Fish tapeworm causes diarrhea and associated w/ B12 deficiency leading to megoblastic anemia, Cobalamin = B12
11. Cobalt Blue firework- Cobalamin
12. Fireworks Blasting: Megaloblastic Anemia
13. Guy leaving toilet paper with long toilet paper stuck to shoe: Largest tapeworm, up to 10 feet long
14. Broken tapeworm in mud: Proglottid segments seen on stool O&P
15. Pretzel guy and coin box on portapotty: TXT Praziquantal or Niclosamide
16. Cocker Spaniel winning the dog show: **Echinococcus granulosus**
17. Second place dog, sheep dog: sheep are intermittent host
18. Poop behind winner: transmission to humans via dog feces, causes hydatid cysts:
19. 1st place trophy w/ a giant egg : "eggshell calcifications" in liver on CT.
20. Guy removing ribbon that is red and puffy - when cysts rupture they can cause an anaphylaxis reaction when attempting removal, must inject w/ solution to kill cysts before removal
21. Eoslingshot kid: Eosinophila

Parasites



Schistosomas: causes shistomiasis

1. San FanSCHISTO ocean park – **Schisotsoma - schistomasomiasis**
2. Swimmer w/ snails: Free living aquatic organism that gain entrance through the skin and enter the bloo stream and carried to liver where they mature into the adults. Then we poop and pee in water and snails become intermediate hosts. Then the adult migrates to another organ.
3. Snails – Intermediate host
4. Red fish going against blue fish in the port hole: All Schistosoma migrate against portal flow to reach destination. Blue fish represent normal flow of blood through the portal veins.
5. Merman statue fish with large dorsal fin in port hole: **Schistosoma mansoni**, large lateral spine on the side of the body of egg
6. Japanese tourists w/ red fish smooth small spine in port hole: **Schistosoma japonicum**, small spine or almost absent on eggs, so mostly round
7. Swimmers Itch where larvae penetrate the skin
8. Crack to porthole: Portal HTN leading to GI distension and abdominal pain caused by parasite
9. Coral: Liver and cirrhosis
10. Yellow Coat: Causes Jaundice
11. Red Swordfish**: S. haematobium** - Large terminal spine seen on stool O&P
12. Swordfish piercing a jellyfish that looks like a bladder: Hematuria in bladder
13. Swordfish piercing a crab: Risk of bladder cancer
14. TXT: Praziquantal (pretzel)
15. **Orca - Clonorchis sinensis:** Chinese liver fluke
16. Snails: intermediate host, then transferred to fish. We will eat uncooked fish and lead to biliary track fibrosis
17. Seagulls with rope hanging down and crab hanging down: (gull bladder) biliary fibrosis and cholangiocarcinoma
18. Black rocks: Pigmented Gallstones
19. Eggs out of birds nest w/ yamica type hats: Operculated eggs on O&P
20. TXT: Praziquantal (Pretzel) for all three
21. Penguin exhibit: **Parogonimus westermonti:**
22. White lungs w/ red: can cause chronic cough w/ bloody sputum
23. Snails: intermediate host
24. Eating Crab legs: transmitted through undercooked crab meat containing larvae
25. Eggs: operculated eggs on stool O&P
26. TXT: Praziquantel (Pretzel



This page intentionally left blank





Picornavirus Family – The Peak-orna Animal Nursery

1. Sun w/ positive sign – Pos sense single strand RNA
2. Peak – Picornavirus
3. Statue of David – Naked Viruses
4. Feces all over - Fecal oral transmission
5. Rhinovirus is respiratory. Don't get confused
6. Coin machine – insert and you get an output, everything is inside the coin machine to make it work - POS Sense RNA Replication uses the host transcription factors, since it is the same sense as host cell, it only needs host RNA polymerase.
7. Tickets start together but break up at the end - Viral RNA is transmitted into long protein product that contains viral proteases to cleave it.
8. only going to illustrate when in nucleus - All RNA positives replicate in the cytoplasm, Host cell RNA polymerase is in the cytoplasm. So this makes sense.
9. Hep A hippos –hippo arm labeled with "A" tag and Liver sign
10. Aviary – enterovirus – polio (flamingo) – Cocksackie And B cockatoos, Mockingbirds (echovirus)
11. Aviary shaped like a head w/ "100% aseptic inside" – Aseptic meningitis
12. Bags of food to represent lab findings
13. No sugar added – glucose levels normal
14. No roganisms – nothing found when plated, aseptic
15. Source of protein – protein is elevated
16. Space helmet - meningitis
17. Rhino – Rhinovirus – common cold – not transmitted fecal oral.
18. Mud on rhino face to symbolize a URI





Poliovirus – The Flamingo Breeding Pool

1. Sun w/ orange hue and Pos sign – Positive sense RNA virus SS
2. Naked David – Naked virus
3. Flamingos in a breeding pool that is yellow
4. Pico flamingos – picornavirus
5. Pool of acid – acid labile so Fecal oral transmission
6. Eggs and orange rings - Virus replicates in peyers patches found in the submucosa in the ileum
7. Peyer's flamingos sign – replication occurs in peyer's patches and takes 2-3 weeks
8. Bird w/ large anterior horn – infection of Anterior horn of lower motor neuron cell bodies and causes paralysis
9. Bird with one leg up, puffing air - Causes an asymmetric paralysis concentrated in lower legs, myalgia's, and respiratory deficiency due to paralysis of diaphragm
10. Meningitides kid with space helmet - Aseptic meningitides
11. Sulking emo kid with skull and crossbones – Salk is killed vaccine that injected
    a. Bypasses gi tract and only forms IgG antibodies, not IgA
12. Savin a live" flamingo - Sabin vaccine that is live and attenuated
    a. Makes IgA since goes through stomach mucosa

Viruses – RNA POS Sense



Coxsackievirus – Coxsackie Cockatoos

1. Orange Hues with Sun – Pos Sense SS RNA virus
2. Pico- Picornavirus
3. Statue of David – Naked virus
4. A and B cages – 2 flavors of cocksackie virus
5. David red hands, foot, and mouth – hand, foot, and mouth disease
6. Red seeds – red vesicular rash
7. Kid with meningitis helmet – aseptic (no bacteria on gram stain) meningitis
8. Little girl in swimsuit – summertime
9. Cocksackie B
10. Heart seed bags – dilated cardiomyopathy
11. Zoo keeper grabbing cockatoo by chest- devils grip, Bornholm's disease – extreme unilateral sharp pain in chest – pleurodynia
12. Txt is supportive care



Rhinovirus – Rhino Petting Zoo

1. Sun w/ pos sign and orange hue – Pos RNA Single Strand
2. Small rhinos – pico virus
3. Statue of David – Naked
4. Camera in David's hand
5. Lemon w/ rhino sneezing - **Transmitted via inhalation** due to it being **acid labile**
6. Please wash hands – transmitted through fomites
7. One camera w/ strap wrapped around horn – Mechanism: attaches to I-CAM1 to enter host cells
8. Hanging out under shade tree with thermometer – needs to keep to cool temp and grows best in 33c of the upper respiratory tract
9. Rhino playing in mud that is dripping down chin onto the chest - Upper respiratory tract
10. Multicolor canopy - Ridiculous number of serotypes, 113 total, so no vaccine



Hep A – Hungry Hungry Hep A hippos

1. Sun w/ pos sign and orange hue – Pos SS RNA virus
2. Statue of David – Naked RNA virus
3. Hepatitis – hippotitus
4. Hippo w/ A tag – Hepatitis A
5. Baby Hippo – Pico
6. Brown liver spot – affects liver
7. Feces and bubbling acid - Acid stable, allowed to be transmitted fecal oral
8. Giant purification machine – how to eliminate HEP A
9. Sign – what is needed to kill HEP A during the purification process
10. Contaminated water is a source in DEVELOPING countries
11. Shellfish snack bar - can be transmitted from shellfish in contaminated sources. Pulled from poop contaminated pond
12. Large backpack- common in travelers in endemic areas
13. Clinically silent w/o jaundice usually
14. Tables where everyone is puking
    a. **Bright yellow outfit – jaundice**
    b. **Puking – vomiting**
    c. **Child w/o yellow – less likely to have jaundice**
    d. Extinguishing cigarette – smoking aversion
15. Sign on shellfish stand – treatment – one month duration, self-limiting, no carrier state or chronic state
16. Tranquilizer gun – inactivated vaccine because tranquilizers inactivate animals



Calicivirus – Cali Sea Cruise

1. Three dragons – Calici cruise
2. Sun w/ orange in the background glare is plus sign – Pos SS RNA virus
3. Naked Statue of David – Naked virus
4. Cruise line attendant checking tickets that are long strand into single tickets - Calici produces one long single protein that is cleaved by viral proteases into smaller active constituents
5. Replicates in the cytoplasm like all positives
6. Narwhal – breaking out of the water - Most common type is NOROVIRUS (Norwalk virus)
7. Commonly happen with people in closed quarters, 90% of all diarrhea outbreaks on cruises
8. Children – common in daycare
9. Consumption of shellfish or a situation where food is touched by people – can contain the virus
10. Aft is shooting shit everywhere – Explosive Diarrheal illness



Flavivirus – Flavor Packed Flavi

1. Sun w/ Orange hue – Pos Sense RnA virus
2. Partygoers in togas – enveloped virus
3. Togas
4. **Hep C drink stand – Hep C is a flavi virus**
5. Straw in juice box – only a single segment of RNA, Non segmented RNA
6. Brown rubber dingy – Dengue fever
    a. Guy in boat that's sweating w/ mosquitos – Aedes egyptei mosquito
    b. Oar of Bone broken into 2 pieces - Infects bone marrow, type 2
    c. Red blood cells – increased risk of bleeding, hemorrhagic fever
    d. Blue and red ribbons – renal failure is common, septic shock and even death
    e. Treatment – on your own, supportive and well hydrated
7. Yellow African water buffalo – yellow fever
    a. Transmitted w/ mosquito – aedes egyptei
    b. Yellow w/liver shaped mud spot – jaundice
    c. Exaggerated hump – back ache
    d. Red stool – bloody stool and diarrhea, possible vomiting
    e. Vaccine – live attenuated
8. West Nile virus – birds are the reservoir
    a. Mosquitos – vector
    b. Red brain shaped feathers – encephalitis
    c. Myelitis and neck brace – meningitis and flaccid paralysis
    d. Bird passing out – coma
9. This way to the sea – hepatitis C w/ yellow hippo and earring shaped like a C



Hepatitis C – the Hep Sea

1. Sun w/ pos sign and orange hue – POS sense RNA Virus
2. Togas – Enveloped
3. Flavorful Hep C Fruit punch – Hep C
4. Yellow hippo – jaundice hippo w/ ear tag
5. Common mode of transmission
    a. Blood water - Exposure to infected blood
        i. Blood transfusions in 70's – 90's,
        ii. Needle in ear – IV Drug use
        iii. Placental, sex, and breast feeding transmission
6. Multicolor tent - Variation of antigenic structure
7. Sign that is misspelled and no viewing 3-5 - Virion coated exonuclease lacks proofreading capacity in the 3'-5' so the RNA is prone to frequent mutations
8. Liver shaped mud patch – inflammation of the liver
9. Yellow hippo – jaundice
10. 60-80 sign - 60-80% of HEP C will become chronic
11. Washed up piece of dead coral - Lymphocytes infiltrate portal tract killing hepatocytes, leading to fibrosis and cirrhosis,
12. Crab - Or liver can go into a frenzy and become malignant leading to hepatocellular carcinoma
13. ALT in the Sea - Acute infection RNA is in serum in the 1st 6 months, ALT is up rising and falling
14. Salt precipitating on shore – 5 sided like IgM molecules - HEP C is associated with cryoglobulins that precipitate out in colder temp that contain IgM
15. Hippo ribs and walkie talkie alpha antenna - Treated with ribavirin w/ interferon Alpha
16. Meat cleaver - Polymerase inhibitor – protease inhibitor used for treatment

Viruses – RNA POS Sense



Togavirus – Toga-Toga-Togavirus

1. Sun w/ orange hues – Pos Sense RNA Virus
2. Togas – Enveloped
3. Dome in the background – not in the nucleus
4. Man on the horse, hitting head on arbor w/ red turban falling off – 3 types of Arbovirus – mosquitos vector
    a. Compass on the horse, red turban - Western equine encephalitis
    b. Venezuelan
    c. Eastern equine encephalitis
5. Young child emperor – Rubella is a childhood disease
    a. 3 presentations
        i. Congenital – Torches - TORCHeS infection
            1. Crosses placental barrier leading to congenital pathology
                1. Mental retardation, microcephaly, deafness, blindness, cataracts, jaundice, PDA, pulmonic stenosis, blueberry muffin rash
                2. MC triad – Congenital cataracts, Sensory-neural Deafness, PDA
                3. Open Roman aqueduct arteriosus w/ blueberry muffin shapes– PDA
                4. Yellow Babies sculptures w/ creepy eyes covering ears- cataracts and sensorineural deafness - Jaundice
        ii. Childhood – Crown of rubies, rubella
            1. Chains of rubies on ear and back of neck – post-auricle and occipital lymphadenopathy
            2. Rubies falling off face - Distinct pattern maculopapular rash that starts on face and spreads downward, moves faster than measles lasts 3 days
            3. Servants fanning king w/ water droplets – respiratory droplet transmission
                iii. ADULT – lymphadenopathy and seizures
            1. Kneeling on ground – knee pain, arthritis
            2. Live puppet show with three puppets - No treatment but vaccine, MMR, live attenuated vaccine. Don't give to pregnant women or immunocompromised individuals
            3. Ticket booth w/ 200 – HIV Pts should receive a vaccine only w/ CD4 count above 200
6. Produce one long polyprotein protein precursor that is cleaved by proteases
7. Big buzzword – IMMIGRANT





Coronavirus – Kingdom of SARS

1. Bright Pos Sun – RNA Pos SS
2. Crown – Corona
3. King with crown wearing a robe – Encapsulated virus
4. Missing statue of David – not naked
5. Long spiraling road with helical trees – helical virus
6. Sneezing and blowing nose – causes common cold
7. Kings respiratory tract design - SARS and Middle east respiratory syndrome, acute bronchitis
8. Castle with king outside – Castle (nucleus) king outside -Replicates in the cytoplasm

Viruses – RNA POS Sense



Retrovirus – One Cane to rule them all

1. Sun w/ orange hues – Pos Sense RNA Single strand start -> DNA due to reverse transcription
2. Wizard – HIV
3. Staff – Immunocompromised
4. Large robe – Enveloped
5. 2 orange dragons – diploid nature RNA virus
6. 3 important genes –
   a. Sundial on brim to remind you of time (24 hours in a day) - **Gag** = p24, which is the capsule for the RNA strands
   b. Pipe smoking w/ marijuana suggestion – **Env** protein that codes for gp41 and 120, 41 is transmembrane protein, 120 is outer protein –sticking out an away
   c. Reverse transcriptum book - Pol – reverse transcriptase
7. Transmission – primarily through sex, blood transfusion,
8. Torch – TORCHeS infection
9. Busting out of jail – HIV initially infects macrophages
10. Squire that is wearing white and 4 in hat – Helper T Cells, targeted by HIV, white for white blood cells
11. Viral wizard casting a spell
12. Kneeling and grabbing back of neck, red faced, and sweaty – prodromal like flu with cervical lymphadenopathy, tonsils may be enlarged. Fever.
13. Sleeping squire – latent for 10 years, replicating in lymph nodes
14. Squires falling off cliff, 200 ft drop - Cd4 below 200 – progresses to AIDS
15. Evil giant fighting crab marching up to archer castle – Archers are B cells shooting antibody like arrows - B Cell lymphoma, diffuse large B Cell lymphoma
16. Banners on the back of backpacks that are CCr5 or CXCR4 logos - Enters the macrophages T Cells via CCr5 and CXCr4 co-receptors, then will enter, uncoat, undergo reverse transcriptase, and enter host genome and mess with machinery
17. She elf with Elisa shield - screening test looks for antibodies using eliza tests
18. Western blot tapestry – Western blot is used for confirmation
19. Measure viral load and cd4 count using PCR, all neonates will positive, but may not have the disease. Use HIV RNA or HIV DNA amplification tests
20. Treatment HART – combination therapy is always better than monotherapy.
21. Pregnant she elf - NRTI's backbone of any HART therapy – flail is a nucleotide analog, halting prolongation.
22. Z - Zidovudine – best for pregnant patients
23. HE elf w/ mace w/o a chain - NNRTI's – does not incorporate in chain, inhibits reverse transcriptase
24. Both are on the reverse transcriptase book
25. Squire trying to pull sword from stone – Protease inhibitor, prevents cleavage of proteins for viral replication
26. Mare that is rearing up and about to crush the squire w/ CCR5 banner - CCR5 inhibitor – miravoroc

Everyone gets treated

Viruses – RNA NEG Sense



Otrhomyxovirus – Night Shift at the Orthodontist's

1. Moon w/ orange hues – RNA NEG Single Strand virus
2. All RNA Negs Bring along their own Polymerase
3. Babies in the helmet - Replicates in the nucleus
4. Orthodontist in the coat – Enveloped
5. FlU-oride poster w/ ABC – most common cause of the flu, strains ABC
6. Octopus w/ 8 arms – 8 segments, so there is 8 places where it can mutate. Antigenic shift and drift
7. DOKTAR DRIFT- **Antigenic drift** is **point mutations** in the viral genome leading to changes in the hemagglutinin (HA) and neuraminidase (NA) molecules. Seasonal flu and epidemics
8. Night Shift, h is falling down to symbolize assortment of genes. - **Antigenic shift** is when segments are shared to form a new species. Segment changes and pandemics.
9. Multiple color curtains – antigenic shift
10. Three main influenza viruses – A causes epidemics and pandemics (Antigenic shift) – B causes epidemics (antigenic drift)
11. Heme Aquarium, Octopus sitting on RBC's, and sialic chains on the helmet – Hemagglutinin (HA), this is a glycoprotein that binds to sialic acid found in membranes in Upper respiratory and RBCs causing them to clump.
12. HA Antigens, H1, H2, H3, - define cell tropism (cells that can be affected) – HA molecule will bind to sialic acid on the cell membrane, then endocytosed into the cell, pH needs to be changed by M2 protein to allow for uncoating.
13. Shell with octopus and 2 M's – M2 Protein
14. Manta ray – Amantadine, Rimantadine inhibit M2 so no uncoating. But allows increased dopamine release in CNS
15. Octopus w/ knife that is missing from **N**urse **A**ssistants tray - Neuraminidase (NA) – allows break virus free from sialic acid inside the host cell
16. Nurse name is TamV(Tamiflu) she is capping all of the scalpels: trade name for Oseltamivir/Anamivir: NA inhibitors blocking release of virus
17. Droplets coming off the aquarium – Flu spread by respiratory droplets
18. Pirates skeleton – killed virus IM
19. Bubbles in nose – Live vaccine
20. Orthodontist inspecting mouth w/ gold staff - Staph aureus pneumonia
21. Sun with rays - Reyes syndrome – aspirin associated with treatment causing encephalitis, and hepatomegaly. Will uncouple mitochondria proton gradient along the electron transport chain in the hepatic cells.
22. Stuffed bear on boys back - Guillen Barre syndrome – ascending paralysis – Finding high protein with low WBC's

Viruses – RNA NEG Sense



Paramyxovirus – Paranormal Mixer

1. Moon w/ orange hues - Single stranded Negative Sense RNA Virus
2. Replicates in the cytoplasm – only exception is orthomyxovirus
3. Ghosts in sheets and envelopes – Enveloped
4. Droplets in sprinkler – respiratory droplets transmission
5. Live Puppet show w/ pregnant women running away– Live MMR vaccine, do not give to pregnant women
6. Ghost weasel on left and ruby dress – **Measles and Rubeola** (same Name)
7. 4 C's on the vest - 4 C's to diagnose measles, Cough, Conjunctivitis, Koplic Signs, Coryza
8. Coughing, drippy nose, red eyes on weasel
9. Bowl of blue marbles - koplic spots (blueish spots on a red background near the molars on the mucosa)
10. Sweat drops on Poppa weasel – fever of 104
11. Rubies falling down the head downwards - Maculopapular rash late, starts on the head and works down
12. Solid dress – confluence rash
13. 2 lungs bow tie – complications, pneumonia
14. Weasel with turban - Subacute sclerosing pan encephalitis – look for anti measles antibodies in the CSF – no treatment
15. Tales of SSPEnce – SSPE
16. Tentacles w/ Berries stuck together - HA (causes RBC's to stick together), and
17. Hand stuck together - fusion proteins causes multinucleated giant cells, found in lymphoid tissue, causes red inclusion bodies.
18. Party hat to weasel friend w/a look - Vitamin A to reduce mortality and complications
19.
20. Mumps mummies w/ big cheeks – **Mumps** replicates in salivary glands, can cause
21. Single orchid - orchitis w/ impaired fertility and testicular atrophy
22. Neck brace - Meningitis can also happen
23. Vaccine puppet show – MMR Vaccine
24. Fusion protein, Neuraminidase (scapel), And HA
25. Tombstone on the right w/ little baby ghosts - Respiratory Syncytial Virus (RSV) –
26. Baby holding Letter G - Attaches to G protein to infect respiratory epithelial cells
27. Ghost baby tree and infiltrates - Bronchiolitis, pneumonia, Most common cause of these in infants
28. Ghost baby w/ sticky hands - Virulence factors – syncium – Fusion protein causing them to stick together
29. Ribs surrounding baby kids - Ribavirion can be used to treat in adults
30. Extra Pale w/ IgG rattle covered in fusion slime - Palivisumab – monoclonal antibody,
31. Seals in the background - Parainfluenza – seal bark cough
32. 3 wolves – all 3 virulence factors, NA, HA, Fusion
33. Church w/ steeple – steeple radiographic sign on xray,

Croup – inspiratory strider a howling noise (church door open) - laryngeotracheobronchitis



Viruses – RNA NEG Sense



Rhabdovirus – Rabid Wrecking Yard

1. Moon w/ orange hues– Neg Sense RNA Virus
2. Doggy hoodie – enveloped
3. Bullets added to dog collar - Capsule looks bullet shaped
4. Helical tail - Helical nucleocapsid
5. Bats, fox, squirrels - Zoonotic virus, these are the most common symptoms
6. Nicotine cigar w/ crumpled cola cans - Glycoprotein that binds to nicotinic acetocholine receptors in the membrane in the NMJ junction and will replicate there
7. Socket w/ cover plate – Initial infects synaptic receptors in the motor end plate
8. Junkyard bulldog foaming at the mouth – rabies
9. Rusted out car with an exposed motor – bulleted leash is virus moves in a retrograde fashion
10. Litter of puppies – replicates in motor neurons
11. Exposed roots – dorsal roots
12. Thief trying to break into the junk yard with big red encephalopathy turban and fever – symptoms
13. Diagnosis is clinical and can be confirmed with negri bodies, eosinophilic cytoplasmic inclusions found in hippocampus or cerebellum
14. Beat up boat on the stack of cars with pink rust spots – Negri bodies
15. i**N**t**EGRI**ty – eosinophilic negri bodies
16. little creature seahorse w/ pyramid – hippocampus pyramidal cells infected
17. Bungee cords hanging from the tree - perkinje cells hold negri bodies
18. Keychain w/ antibody like keys - Antidote w/ passive preformed antibodies IgG prior to symptoms and killed vaccine
19. Tranquilizer gun w/ skull and crossbones – Killed Vaccine – give the treatment even if you just wake up with a bat in the room.





Filovirus – Soccer Field'o Virus

1. Moon w/ line through – NEG Sense SS Helical RNA virus
2. Helical orange wrapping around the goalpost – Helical RNA
3. Replicates in the cytoplasm like all RNA virus (not orthomyxovirus)
4. Big jersey – Enveloped
5. Marburg and eGOOOOALA – Ebola virus
6. Goalie with jersey spots and sweaty – infected w/ filovirus and demonstrating hemorrhagic fever, petechial rash
7. Guy on ground – hemorrhagic fever
8. Kidneys and liver – end organ failure
9. Dead – Fatal
10. Blood pool – Severe blood loss
11. Lightning bolt on jersey – Shock
12. Monkeys or fruit bat – vectors
13. Healthcare – healthcare workers more likely to get the virus



Bunyavirus – paul bunyavirus

1. Moonlight w/ orange glow mountains – NEG sense RNA Virus
2. Robe – Enveloped virus
3. Gold coat - Obtains the envelope from Golgi body of host cells
4. Three segments of a tree w/ rings inside - Segmented – 3 circular segments
5. Wooden arbor – arborvirus – mosquito virus
6. Hantavirus – transmitted through rodents, Deer mouse urine and pellets
   a. Ghosts above mice – hauntavirus – can cause death
   b. Wet marks on chest in shape of lungs w/kidney shaped canteen leaking water - Causes pulmonary edema via capillary leak and prerenal azotemia
   c. Fever and sweating w/ blood form axe - Hemorrhagic fever
7. California rift valley elementary school - Rift Valley Fever, California encephalitis – from ades mosquito
   a. School children shaking in fear – Seizures
   b. Red turban – encephalitis
   c. Mosquitos around kids – aedes mosquito vector



Arena Virus – Welcome to the arenavirus

1. Moon w/ neg sign– SS NEG sense RNA
2. replicates in the cytoplasm
3. Champion gladiator in roman robe – Enveloped
4. Challenger wielding 2 swords (ambidextrous) - Has the capacity to encode neg and positively
5. Spiral banners – helical shaped capsid
6. 2 large rings in the floor of arena - Segmented virus, only 2 can reassort
7. Arena of sand - Characteristic granular sandy outer capsid on EM
8. Rodents on the floor - Rodent transmitted diseases in humans
9. LCV roman numerals – LCV lymphocytic choriomeningitis virus – febrile aseptic meningitides
10. Red turban around head and neck – meningitides
11. Sweating – fever
12. Spear on fire, moonlight into opponents eyes (irradiation) - Inactivated by heating, low PH, irradiation and detergents, just really know it's capable of being inactivated.





Reovirus – A Race on the Rio

1. Orange Hues – RNA virus
2. DNA floatation rope in the middle of the river, no sun or moon - Double stranded
3. Replicates in the cytoplasm
4. David in the back – Naked
5. 11 boats on the river – 11 Segments
6. **Propeller - Rotavirus**
7. Water flying up behind - Toxic mediated secretory diarrhea
8. 9 speed 4 stroke – NSP4 causes secretory diarrhea
9. Boat name is CHLO-RIDER – Chloride permeability is increased
10. Snow caps – classic outbreak is in the winter
11. Children racing boats, maybe in daycare - Population most at risk is children
12. #1 sign - #1 cause of severe diarrhea in young children
13. Welcome to Colorado - Colorado tick virus
14. Kid emerging from water with myalgia, fever, and vomiting
15. Treatment is supportive care and oral rehydration therapy
16. Camera team shooting live w/ vaccine near mouth - Live attenuated oral vaccine
17. Telescope - 1st dose before 3 months of age due to decreased efficacy and may increase risk of intussusception



HSV1 an HSV2 – Hermes, the god of herpes

1. Blue Hues – DS DNA Virus
2. Torch – TORCHeS Virus
3. Robe – Enveloped
4. Replicates in the nucleus
5. Straight lines on road – Double stranded and linear
6. Dry Cowhide – Cowdry bodies, intranucleur inclusion virus look like targets
7. Transmitted via Sex and Saliva, and verticallyas a torch infection
8. 2 strains HSV1 and HSV2
   a. Inflamed lips - HSV1 upper half of body – 1st infects as gingiva infantitis
      i. Ulcers on lips – Lip herpes
      ii. Red eyes and 2 snakes – snake like ulcers and Keratoconjuctivitis
      iii. Helmet w/ temporal lobe red wings - Temporal lobe encephalitis w/ bizarre behavior
      iv. Crazy look in eyes - Most common cause off sporadic encephalitis
      v. 3 gems – latent in trigeminal ganglia
      vi. Tossing roses w/ dew drops falling off roses – dew drops on a rose petal appearance
      vii. Dew drop Finger herpes – herpetic whitlow
      viii. Post it stamps tracking up the arm - Erythema multiform forming target lesions on hands and feet that move inwardly
   b. HSV2
      i. Transmitted by any action in the genital regions
      ii. Tufting around skirt - Painful vesicular lesion, w/ inguinal lymphadenopathy
      iii. Plate on belt - Dormant in the sacral ganglia
      iv. Neck brace - Can cause meningitides
9. Tank - Tzanc smear looking for multinucleated giant cells
10. Violet recycle bin - TXT: no cure, prevent breakouts w/ acyclovir and valcyclovir



Epstein-Barr virus – Ye Olde Epstein Bar

1. Blue hues – Double stranded DNA
2. Causes infectious mononucleosis.
3. People trying to kiss – spread through mouth secretions – Kissing disease
4. **Guy sweating w/ fever – has infectious mono**
5. Knocking over the drink onto the knight, the night is furious and grabs on the back of neck – **tender lymphadenopathy in posterior cervical**
6. **Armor w/ T on it – T cell**
7. **8 on shoulder and sword – cytotoxic T cells TH8**
8. Knight is reacting in a violent way – **reactive lymphocytosis, aka downy cells**
9. Stains on coat – look like a downy cell w/ oval or folded in nucleus
10. Random cow behind bar w/ spleen spot - T Cells proliferate **causing splenomegaly**
11. Archer asleep w/bow next to him in white - Targets B lymphocytes (white cells) in a new host, EBV remains Latent in B Cells
12. Must B 21- EBV Envelope (glycoprotein) binds to CD 21, that is a receptor for compliment component CD3, to infect B Cells
13. Man's mouth w/ tonsillar exudates – Pharyngitis
14. Differs from strep pharyngitis (more often seen in children), mono occurs in late teens and adulthood (most likely asymptomatic in children)
15. Red pencil - Develop a maculopapular rash w/ penicillin treatment
16. Amoxicillin and ampicillin – reaction is not an allergic reaction
17. **Crab - Increased risk factor for 3 cancers**
    a. **OWL picture in the background - Weakened immune systems develop B cell lymphoma, Hodgkin's lymphoma mixed cellularity.**
    b. **Kid in Africa clothing w/ mouthful of crab puffing out cheeks - Non Hodgkin's lymphoma, Burkett lymphoma, Most common translocation is t8:14**
    c. **Crab pinching nose - Asian people nasopharangyel carcinoma**
18. **Old guy w/immunocompromised cane and hairy beard - Oral hairy leukoplakia – not a precancerous lesion, in HIV pts**
19. Medieval dart board – Monospot IgG test - Diagnosed during acute infection secretes heterophile sheep antibodies that agglutinate

No contact jousting allowed in the bar - Must **avoid contact sports due** to the risk of splenic rupture



Cytomegalovirus – Cyto "Mega-Lo" Virus

1. Mega lo virus – cytomegalovirus
2. Blue tones – DNA virus, replicates in Nucleus
3. Hermes messenger – Herpes virus family
4. Sleeping man – Latent in mononuclear cells, Leukocytes
5. Archers and Knights – B and T cells
6. Castle w/bar and cages – macrophages.
7. Guy being woken up with a cane - Virus can be inactivated when immunosuppressed
8. Torch - Transmitted in many things, TORCHeS infection
9. Little guy driving into blueberry muffin - Most common fetal viral infection, presents with blueberry muffin rash (thrombocytopenia) petechial rash like congenital rubella
10. Spotted yellow cow – hepatomegaly and jaundice
11. Covering ear – sensonueral hearing loss
12. Covering the sides of the helmet (looks like large ventricles of brain) – ventruculomegaly, Calcifications around ventricles, periventricular calcifications. Toxoplasmosis also does this
13. Man slipping on milk - Mental retardation and seizures from intracranial calcifications
14. 80-90% off - Most of the time (80%) asymptomatic
15. Highest risk of congenital CMV, 2nd trimester
16. Balloon animal showing swelling and edema on water - Hydrops fetalis – heart failure leading to severe edema
17. #1 on shirt - #1 cause of mental retardation from viral infection, #1 sensonueral hearing loss
18. Immunosuppression, HIV, Transplant patients
    a. Butcher w/ many meats coughing - Organ transplant patients infected w/ CMV pneumonia
        i. Use a buffy coat culture w/ anti CMV antibodies
    b. Old man w. cane "charity drive for CD 50"- AIDS patients w/ CD4 counts less than 50
19. CMV retinitis looks like a Pizza pie - CMV retinitis
20. Conveyer belt, ling deep ulcerations, Red bags w/ red dot (colon inflammations) - CMV esophogolitis and colitis, differ from herpes because CMV is singular deep and linear
21. Owls O cereal - Owls eye inclusion bodies
22. Recycle bin cans only-Ganciclovir
23. Fast car w/ net and UL 97 sticker - Foscarnet when UL97 gene mutation
24. Mom w/ red throat - CMV mononucleosis, similar to reg mono. Monospot test would be negative
25. No Mo Spot detergent – Negative Monospot



Varicella Zoster Virus – Varicella "Zeus" ster virus

1. **Blue** – DS DNA Virus
2. Hermes – Herpes Virus family
3. Togas and robes – Enveloped
4. **Chickens running around – Chicken pox – Xanthan**
5. Sweat beads on kids and holding heads – Headache and fever
6. Kid squirting droplets – respiratory droplets
7. Dew drops on rose petals – vesicular rash described as dew drops on a rose petal
8. **All ages welcome – all rashes are at different stages of healing**
9. **Tank – tzank smear shows multinucleated giant cells**
10. **Adult with respiratory droplets - Adults who get chicken pox can get pneumonia**
11. Red turban – encephalitis
12. Immunocompromised cane – easier to get the virus complications
13. Live show – Live Vaccine
14. Recycling bin - Drug to treat – Acyclovir
15. Tree roots extended into the background and a guy taking a nap - Virus remains latent to dorsal root ganglia
16. Senior citizen w/ canes - VCV can become reactivated in older individuals
17. **Shingles on the senior citizen area – Shingles in old individuals**
18. Shirtless dude throwing a bouquet w/ trail of roses – Dew drop like vesicles on an erythematous base, reactivates and travels down dorsal root in a dermatome pattern. Rarely cross the midline, if it crosses it means it is disseminated VCV
19. Rash is painful – shot with the lightning bolt,
20. Shirtless guy is angry – post herpetic neuralgia – pain after shingles
21. Red eye patch - Can infect the trigeminal nerve and lose vision – herpes zoster opthalmicus
22. Seniors only sign - Zoster vaccine for shingles vaccine, recommended for adults over 60
23. Seats at least 200 - HIV Patients can get vaccine if CD4 >200
24. Txt w/ acyclovir or (family recycling) Famcyclovir, or Valcyclovir (violet recycle bin)
25. Torches – congenital infections
26. Congenital varicella syndrome
    a. Limb hypoplasia
    b. Cutaneous scarring in a dermatomal pattern
    c. Blindness



Human Herpes Virus 6 – A roseola by any other name would smell as sweet

1. Blue hues – DS DNA Virus
2. 6th disease "roSIXola"
3. Squire following horse w/ rosaries – Roseola
4. Squire w/ 4 feathers and 4 on belt = helper t cell = squire helps knight
5. HHV-6 infects CD4 cells and kills them off
6. Hermes – Herpes virus
7. Roseola is an illness that occurs between 6 months and 2 years of age, high fever, then diffuse maculopapular lacy rash that spares the face.
8. Squire sweating profusely w/ 4 sun flag – **4 day fever over 104 degrees**
9. Squire trembling w/ awe – febrile fevers
10. Timing, fever lasts 4 days, then a rash appears
11. Blue flames and pink lace – **fever has subsided and now there is a rash that spares the face**
12. Child in arms – 6 months to 2 years
13. No FDA treatment, just keep the patient cool.



HHV 8 – ring around the Kaposi

1. Kates Posies – Karposi
2. Blue Hues – DS DNA Virus
3. Hermes on door – Herpes Family
4. Elderly women on a cane – immunosuppression
5. Aids ribbon – infects aids patients
6. Holding flowers and marks on nose and extremities - Erythematous violaceous lesions on nose, extremities, and mucous membranes and may be present as a plaque, patch, macule, or nodule. These rise from primitive mesenchymal cells involving angiogenesis causing the violaceus color.
7. Irrigation hose – remind us of proliferation of vasculature
8. **VEG fertilizer w/ red branching plant - Causing the dysregulation of vascular endothelial growth factor**
9. Plastic covering on plants in the back - Intrintestional lesions
10. Arched ceiling of greenhouse w/ violet posies - Most common lesions are the hard palate
11. **B rating and medieval archer - HHV8 can cause a B Cell Lymphoma called primary enfusion lymphoma**
12. Transmission kissing, population
    a. Geographical plants (Russian rhododendrons) - Elderly Russian men
    b. African azaleas - Endemic areas of Africa
13. **Leopard – Confused w/ bartonella hensleae**
14. Differentiated from bartons w/ lymphocytic infiltrate, Bacillary angiomatosis has a neutrophil infiltrate
15. Just use Aids therapy



Polyomavirus JC and BK – Et Tu, BK?

1. Blue – DS DNA virus
2. Naked David – Naked Virus
3. Circular room – polyolyoma is a Circular DS DNA Virus
4. **JC Virus** – toga is falling off because its naked (john Cunningham virus)
5. Bust of Julius Cesare is labeled PML - Causes progressive multifocal leukoencephalopathy (PML), happens to immunocompromised people.
6. Senator count 200 - CD4 Counts less than 200 in AIDS
7. Julius Caesar being killed with white laurel leaves - Demyelination disease and is multifocal. ½ who get it die in a few months, leaves are white to remind of leuko (leukoencephalopathy) which are non-enhancing multifocal brain lesions in white matter
8. wood grain that is coming off the Legs of the table with bust – meant to look like neurons being demyelinated
9. Think AIDS patients with motor neuropathy
10. **BK Virus – Brutus and his knife**
11. Knife wound - BK Virus causes nephropathy
12. Cherubic virus peeing red - Causes hemorrhagic cystitis
13. Large serving platter of organs falling to the floor - Commonly transplant patients – kidney nephropathy and bone transplant
14. Renal patients on immunosuppressant's that has hematuria



HPV – Pilloma Bugs

1. Pill bug on chair – pilloma
2. Blue hues – DS DNA virus
3. Naked David – Naked Virus
4. Ages of characters represent numbers
   a. Kids with warts - HPV 1 and 4, verruca Vulgaris = cutaneous common wart
   b. 6 and 11 year old, one eating a bug, one dropping one down the pants – HPV 6 and 11, Laryngeal Papillomatosis (recurrent respiratory papillomatosis), anal genital warts (condo Loma accumulata) (condyloma lata = syphilis)
   c. HPV 16 and 18 year olds enjoying a crab dinner and pillbug on chair – HPV 16/18 cause anogenital carcinoma (Squamous Cell Carcinoma), HPV 31 and 33 also cause it. Add 15 to the 16 and 18 to remember 31 and 33.
5. Syringe looking spikes enclosing 6,11,16,18 - Gardasil, inactivated quadrivalent vaccine
6. Most common STD
7. Virus is able to upset the cell cycle, tumor suppress or proteins p53 and RB stop the advancement from G1 to S phase, HPV encodes E6 and E7 to promote the proteolysis of p53 and RB. This will increase the risk of cancer
   a. E6 and crab cracker – E6 cracks p53 like a crab cracker cracks shells.
   b. Dark blue table – p53stops the progression of transition to G1S phase (crab cracker w/ railroad checkpoint symbol)
   c. E7 is fork w/ E shaped prongs, straw coming out of a root beer – Straw forming 7 – E7 attacks RB to prevent it.
8. Key buzz phase – bleeding after sex for cancer
9. Girl w/ smear on face - Pap smear anc cervial cancer screening
20. Plate w/ weird sunny side up eggs - Sampled from the transformation zone to detect morphological changes, looking for koilocytes
10. Broken leg w/ cane and AIDS awareness - Important risk factor is immunosuppression, especially in HIV population Anal or penile cancer



Parvovirus B19 – Bombs Away

1. Blue hue – DNA Virus
2. B19 Bomber – Parvovirus B19
3. Naked David – Naked Virus
4. Small city – Parvovirus is the smallest virus
5. **Single strip – Single stranded Virus**
6. Kid spraying water gun in the back - Transmitted via respiratory droplets
7. Statue of liberty Torch - Transferred from mother to fetus
8. **Kid slapping a kid, 5 fingers in a slap - Causes slapped cheek disease or fifths disease or erythema infectiosum** (low grade fever that lasts a week, then becomes a lacy reticular pattern that goes down the body)
9. **Plane kid is holding, fire starts on the engine then moves down** – Erythema starts on the face and moves downward
10. Adult kneeling - schoolteacher becomes will with joint pain, arthritis, and soreness
11. Communist plane in the cupboard w/ sickle and bone – leads to aplastic anemia in sickle cell patients has a cobweb look
12. Balloon baby sprayed with water gun - Baby in utero exposed to parvo virus the consequences are severe, may lead to hydrops fetalis. Massive edema leading to fetal demise.



Adenovirus – A den of lions

1. Cold dark shades of blue with some red – DNA Virus (Blue), Adenoids and oropharynx (red)
2. Lions are all yawning exposing tonsils – tonsillitis
3. Naked David – Naked virus
4. Dripping stalactites - Transmission via respiratory droplets
5. Feces – Fecal oral transmission
6. Children in cam, kid swimming in red pool - Most at risk is little children, military recruits, and public pools
7. Blood dripping from David crotch – causes hemorrhagic cystitis
8. 3 major disease processes
   a. Tonsillitis
   b. Hemorrhagic cystitis
   c. Lions w/ red glowing eyes – viral conjunctivitis
9. Tranquilizer gun w/ “live lions” sign - Soldiers will always get a vaccine, a live one, for military recruits



Pox Virus – Pox in a Box

1. Blue – DS DNA Virus
2. Boxing and shipping company – Pox comes with everything it needs inside of it, even making their own envelopes
3. Workers making their own envelopes – Makes it own envelopes
4. **Working stuffing packages - Replicates in the cytoplasm and brings its own RNA polymerase to produce all of the proteins it needs, including DNA pol**
5. Bunch of G's on the map to represent the Guarneri inclusion bodies (where the cirrus will replicate in the cytoplasm) and the HQ is the nucleus - Forms intracytoplasmic bodies in cells they infect, type B are the most important. Finding on a biopsy is diagnostic. **It does not need to go into the nucleus**
6. Dumbbells in boxes - Dumbbell shaped core
7. "World's Largest" - Largest known DNA virus
8. Small Box w/ same day shipping - **Small Pox virus raised skin on surfaces, Variola, lesions are the same age**
9. Udder shaped peanut dispenser - Cow Pox – causes symptoms similar to small pox
10. **Snail Mail area - Molluscum contageosum virus**
    a. Child with a bunch of post it stamps on trunk - **Flesh colored, dome shaped, umbilicated lesions on trunk**
    b. Sexual transmission in adults, usually a single lesion.
    c. Immunosuppression cane - If spreads diffusely it is due to immunosuppression



Hepatitis B – "Hep B Love"

1. HEp B hippy Hippo Van – Causes Hepatitis
2. Hippy dome "hippy pad" – Hepadnavirus family
3. Blue Hues – DS DNA Virus
4. Hippys in garb – Enveloped virus
5. Hippy's inside and outside of the dome - Replicates in the nucleus and outside of it "far out"
6. Circular stand of hippies and one area is not complete - Circular and partially double stranded DNA, and becomes fully double stranded during replication
7. Reverso transcriuptum book w/ fortune teller - Goes from SS DNA to SS RNA then to DS DNA, because it contains its own reverse transcriptase
8. Hippie w/ sex drugs and rick and roll sign - Spread via sex and drugs
9. Mother pushing baby w/ red shirt – vertical transmission when blood during child birth
10. Tiki Torches – Torch infection
11. Cookie sharing, baby w/ larger part - Hep B only about 5-10% develop into chronic infection in adults, newborns will be about 90-95% chance of development
12. Hippy lady w/ beads on a string - Most common disorders w/ rash and arthritis, and poly arteritis nodosa (beads on a string appearance)
13. Body covered with henna – rash, purpuric
14. Kneeling – arthralgia
15. Bead boxes shaped like kidneys – Kidneys are damaged by polyarteritis nodosa
16. 2 big knots on this string - Membranous, and membranoproliferative glomerulonephritis (3 strings "tram track" appearance)
17. Clinical picture – diagnose what stage its in
18. ALT Balloon – ALT is rising in acute HEP B infection
19. Baby w/ deflated ball – initial phase of HBV infection, serum ALT will be normal in neonates
20. Lines in rainbow represent titer levels during course of infection
    - **a.** Species
    - **b.** S = Hep B Surface antigen 1st one (leads to ground glass appearance)
    - **c.** E = Hep B E antigen (has not been enough time to create antibodies) spikey things look like antigen hanging off of a virus
    - **d.** Flat tire – these two above are during the symptomatic
    - **e.** C on the window = Anti-HEP B Core antibody is positive in the window period,
    - **f.** E = anti Hep B E antibody – means low infectivity
    - **g.** S w/ blue curve wrapped around the syringe = Anti Hep B Surface antibody – indicates recovery – this is the value that is checked for immunization, and will be the only one that is positive
    - **h.** Immunized people will be **not be positive** for HEP B Core, or HEP B E antibodies.
21. Magical tarot card table made of stone and card - Long term sequelle of long term infections – Liver cancer (hepatocellular carcinoma)
22. Children in orange, wearing flowy hippy garb, moon necklace, circular headband - HEP D (Circular RNA NEG, Enveloped) needs HEP B surface antigen to cause infection
23. Hippy mom adding hippy flair to children – need HEP B Sag to become infection
24. Holding hands – co infection
25. Kid on shoulders – Superinfection when Hep D is transmitted on top of existing hep B infection
26. Grimacing dad – Hep D (kid on shoulder) post infection has worse outcomes
27. Make peace (Lamb) not war (She elf) - Treatment – Lamivudine and NRTI's
28. Twisted hippy van antennae - Interferon Alpha can be used

Keys to hippy van - Ig w/ HEP B vaccine to neonates who are at risk

29. Ground glass appearance on histology



Penicillin G & V: Princess Ellen's New Hope

1. Princess Ellen – Penicillin
2. Purple Lightsaber pencil – Penicillin
3. Ringed Planet: Beta Lactam Ring interferes with transpeptidation reaction of bacterial cell wall synthesis
4. Purple coccoid space stations: activity against gram positive organisms (Staph and Strep)

   <u>MOA</u>
5. Armored space station w/ D-Ala architecture motif: Death coccus wall: Peptidoglycan cell wall with repeating D-alanyl-D-alanine oligopeptides
6. Planetary building project worker: penicillin binding protein forms peptidoglycan cross links, penicillin's will halt peptidoglycan synthesis in the cell walls: bactericidal

   <u>Delivery</u>
7. V Winged Ship attacking Penicillin binding proteins workers: Penicillin V (oral)
8. Acid Nebula: Acid Stable and only used in minor infections due to poor bioavailability.
9. Royal G-Shaped Hair on Princess Ellen: penicillin G
10. Ivy: administered IV (pen G)

    <u>Used to Treat</u>
11. Red bandanna: Oral Penicillin V treats streptococcal pharyngitis
12. Heart Shaped Planet Sydenham: Penicillin G or V treats rheumatic fever
13. Emperor viridians w/ bicuspid hat: Strep Viridians causes left sided endocarditis caused by strep viridians or strep bovis
14. Galactic Baby: Group B baby, Penn G given intrapartum for GBS prophylaxis
15. Israeli Flag and purple rod shaped carrier: Activity against Actinomyces Israeli
16. Perforated spacesuit: Activity against Clostridium Perfringens causing gangrene
17. Space Dog: pastuerella infections commonly caused by dog bites. Treated with pen g
18. Red gloves and boots on running astronaut towards spiral galaxy: single dose of benzathine pen g treats syphilis (spirochete)
19. Red helmeted bounty hunter w/ diplococci balls: penicillin G treats Neisseria meningitides

    <u>Resistance</u>
20. Beta Trooper shooting down a ship: Beta Lactamases are immune to penicillin
21. Circular shape: beta lactamases expressed by plasmid genes

    <u>Adverse Reactions</u>
22. Astronaut shutting eyes w/ IgE missiles on ship: Type 1 IgE mediated hypersensitivity reaction
23. Exploding asteroids w/ IgG: drug-induced autoimmune hemolytic anemia (positive direct coombs test)
24. Kidney shaped nebula: Drug induced interstitial nephritis



Nafcillin, Oxacillin, Dicloxacillin: The Staphyloocci Strike Back

1. Ringed Planet: beta-lactam ring
2. Death coccus wall: Peptidoglycan cell wall with repeating D-alanine-D-alanine oligopeptides → D-ALA-D-ALA
3. Planetary building project worker: penicillin binding protein forms peptidoglycan cross links
4. Inactivated PBP worker: beta-lactam antibiotics covalently bind PBP's
5. Protective armor on rebel ships: bulky R-groups prevent beta-lactamase binding
6. Purple pencil staff: Nafcillin
7. Horned creature: oxacillin
8. Purple coccoid space station cluster: Narrow spectrum, only activity against staphylococci
9. Red hump: empiric treatment for skin and soft tissue infections (folliculitis, abscesses)
10. Tricuspid pyramids: treatment for staph endocarditis
11. Fish bones: treatment for Staph osteomyelitis
12. Same AE's as penicillin
13. Altered wall builder: altered penicillin binding proteins resistant to beta-lactams
14. Gold Emperor: MRSA is resistant to beta lactamases



Extended Spectrum Penicillin's: Beta Lactamase inhibitors

1. Ringed planet: Beta Lactam ring
2. Unfinished Death Coccus: binds PBP's halting peptidoglycan wall synthesis
3. Purple coccoid space statins: activity against gram positive organisms (staph and strep)
4. Red Color: improved activity against gram negative bacteria
5. Prism: broad spectrum (amped up penicillin's ready to party)
6. Ammo box: amoxicillin (oral bioavailability)
7. Open Mouth: amoxicillin – oral bioavailability
8. Red bandanna: amoxicillin and ampicillin to treat strep throat
9. Plugged ears: amoxicillin treats otitis media and sinusitis caused by strep pneumoniae, Haemophilus influenza, moraxella catarrhalis
10. Rusty chest plate: amoxicillin and ampicillin treat pneumonia caused by strep pneumoniae, H. influenza
11. H Wing ship: activity against Haemiphilus influenza
12. Helicopter: amoxicillin is part of the triple therapy (with clarithromycin and a PPI) for helicobacter pylori infection
13. Robin of Ixodes: amoxicillin treats Lyme Disease caused by Borrelia burgdorferi
14. Amp: Ampicillin
15. IVY: Ampicillin – IV administration
16. Gas mask: ampicillin treats anaerobic infections (enterococcus)
17. Purple double base rock drums: Gram Positive enterococcus treated by ampicillin
18. Knocked over amp: ampicillin resistant strains of Enterococcus due to beta-lactamase production
19. Meningitis helmet w/ set list: ampicillin treats meningitis caused by Listeria monocytogenes
20. Intestine taps: activity against gastrointestinal and urinary tract gram negative rods
21. Beta Bouncer: sensitive to beta-lactamases (typically used with clavulinate)
22. Distracting Clarinet: Clavulanate – beta lactamase inhibitor
23. Back to back tambourines: tazobactam and sulbactam – beta lactamase inhibitors
24. Spleen hole: amoxicillin prophylaxis against encapsulated bacteria (s. pneumo, H. Flu) in asplenic patients
25. Tooth is flying out: Amoxicillin prophylaxis before dental procedures in patients at high risk for endocarditis
26. Red mask sloughing off: stevens johnsons syndrome (cause a rash)
27. Trampled liver spot: Drug induced liver injury
28. Red Lights: antibiotic induced rash in the setting of viral illness (EBV-infectious mononucleosis)
29. Piper: Piperacillin
30. Tiger stripes: tigeracillin
31. Paired with beta lactamase inhibitors to prevent cleavage of beta lactamases
32. Gas mask: piperacillin and ticarcillin treat anaerobic infections,
33. Mona lisa: active against pseudomonas infections



Cephalosporin's: Revenge of the Ceph

1. Ringed planet: Beta-Lactam ring
2. Unfinished death coccus: binds PBP's halting peptidoglycan wall synthesis
3. 5 separate generations: "5 Generals"
4. **1st General Lex: 1st generation cephalosporin's include cephalexin and cefazolin**
5. Flex: cephalexin
6. Fez: cefazolin
7. Purple coccoid space stations: activity against gram positive organisms (staph and strep) 1st gen
8. Puffy red gloves and Patches: treats cellulitis, abscesses caused by staph and strep
9. Red Bandana: treats S. pyogenes
10. Red Bladder cup: activity against gram negative UTI bugs (proteus, E Coli, Klebsiella) 1st gen
11. Bloody surgical instruments: cefezolin for surgical prophylaxis
12. **2nd General Fox: 2nd generation cephalosporin's include cefuroxime, cefotetan, cefoxitin**
13. Furious: cefuroxime
14. Tea cup: cefotetan
15. Fox: cefoxiitin
16. Red space stations: same coverage as 1st gen with extended gram negative coverage (2nd Gen)
17. Red Hens teapot: activity against H. flu, Neisseria, Serratia (HENS)
18.
19. **3rd general Taz: 3rd generation cephalosporin's include ceftriaxone, cefotaxime, and ceftazidime**
20. Mostly red space stations: extended gram negative coverage beyond 2nd gen (3rd gen)
21. 3 axes: ceftriaxone and cefotaxime (used to treat meningitis)
22. Mohawk helmet: empiric treatment for meningitis (3rd Gen)
23. H-wing ship: activity against H Flu
24. Rusty chest plate: treats community and hospital acquired pneumonia (3rd gen)
25. Taz: Ceftazadine
26. Mona Lisa: ceftazidime treats pseudomonas infections
27. Emperor viridians: ceftriaxone treats endocarditis caused by Strep Viridians and HACEK organisms
28. Intestine battle suit: activity against gram negative GI bugs (3rd Gen)
29. Dripping chandelier: single dose of IM ceftriaxone is first line txt for gonorrhea
30. Robin of Ixodes: ceftriaxone treats Lyme disease caused by Borrelia burgorferi (3rd gen)
31. **4th General Prime: 4th generation cephalosporin's include cefepime**
32. Prism: broad spectrum
33. Mona Lisa: Pseudomonas coverage
34. Red and purple space stations: broad spectrum
35. Mohawk helmet: cefepime treats bacterial meningitis
36. **5th General Tara: 5th generation cephalosporin's include ceftaroline**
37. Prism: broad spectrum
38. Lord MRSA: crftaroline treats MRSA infections
39. Same adverse effects as penicillin, nephritis, hemolytic anemia, hypersensitivity reaction, cross reactivity with penicillin allergies
40. Ineffective beta guards: Beta-lactamases ineffective against cephalosporin's
41. Resistance is gained by altered PBP's and extended spectrum beta lactamases



Monobactams, carbapenems – The coverage is strong with this one

1. Ringed planet: Beta-Lactam ring
2. Unfinished Death Coccus: Binds PBP's halting peptidoglycan cell wall synthesis (D-ALA-D-ALA)
3. **One Eyed AZ-3M: Monobactam – aztreonam**
4. Bellows: monobactam has activity against aerobic gram negative rods
5. Red rod robot: monobactam has activity against gram negative rods
6. Mona Lisa: monobactams and carbapenems treat Pseudomonas infections
7. Red Mohawk helmet and rusty lungs: monobactam treats serious systemic infection with gram negative pathogens (meningitis, pneumonia, sepsis)
8. Pencil Wound: monobactams can be used in patients with a H/O penicillin allergy
9. Ineffective beta guard: monobactams are resistant to beta-lactamases, ring shape on gun to remind us that beta lactamases are encoded by plasmid genes. Gun because they cleave beta lactams
10. **Hover Car: carbapenems – imipenem, ertapenem, meropenem, doripenem**
11. Mona Lisa: monobactams and Carbapenems treat pseudomonas infections
12. Prism: broad spectrum carbapenems
13. Gas mask: carbapenems treat anaerobic infections (aspiration pneumonia, intra-abdominal infections)
14. "when others fail we get the job done": use of carbapenems with bugs resistant to other available treatments
15. Red Mohawk helmet and rusty lungs: monobactam treats serious systemic infection with gram negative pathogens (meningitis, pneumonia, sepsis)
16. Amy: imipenem inactivated by dehydropeptidase in renal tubules
17. Cilastin oil: cilastin inhibits dehydropeptidase in the renal tubules preventing degradation of imipenem
18. Mud puddle: GI side effects of carbapenems
19. Rust spots: carbapenem may cause skin rash
20. Shaking Droid: imipenem lowers the seizure threshold
21. Ineffective rainbow beta guard: monobactams are resistant to extended spectrum beta-lactamases



Vancomycin: MRSA… why did it have to be MRSA?

1. Purple coccoid temples: activity against gram positive bacteria
2. No Mercy pharaoh: activity against methicillin resistant Staph aureus (MRSA)
3. Golden Staph: Staph aureus
4. Van: Vancomycin
5. Temple wall hieroglyphs: inhibition of cell wall synthesis by directly binding D-ALA-D-ALA oligopeptides
6. Altered wall builder: altered penicillin binding proteins resistant to beta-lactams
7. Ineffective altered wall builder: altered PBP's ineffective against vancomycin
8. Ineffective guard: beta-lactamases ineffective against vancomycin
9. Ivy Whip: IV administration
10. Meningitis Mohawk: CNS penetration – activity against penicillin-resistant strep pneumo
11. Fish skeletons: Bone penetration – treats MRSA osteomyelitis
12. Nurse: activity against nosocomial MRSA infections (hospital acquired pneumonia, lung stains on her uniform)
13. Mechanic working on car and Biofilm on lines and valves: activity against S. epidermidis
14. Heart shaped headpiece: empiric treatment of endocarditis
15. Diplococcus rock drums: activity against Enterococcus
16. D-LAC hieroglyph: altered peptidoglycan structure (D-ALA-D-LAC) confers resistance to vancomycin
17. Temple of flowing chocolate: oral vancomycin treats Clostridium difficile colitis
18. Red Statue: red man syndrome due to histamine release
19. Beehive: mast cell
20. Blue vines: thrombophlebitis at injection site
21. Broken ear on Anubis: ototoxicity
22. Falling kidney on Anubis: nephrotoxicity
23. Slingshot native in dress: Drug reaction with eosinophilia and systemic symptoms (DRESS) syndrome
24. Vans in the distance: undulating plasma levels that must be monitored



Daptomycin: Let my chicken go

1. Police Dept: DAPTomycin
2. Purple wall of protesters: activity against gram positive cell wall (staph, strep, enterococcus)
3. Taser: inserts lipid tail into membrane to depolarize cell
4. Resisting Van: Activity against vancomycin resistant bacterial strains
5. Diplococcus rock drums: activity against enterococcus
6. No Mercy pharaoh: activity against methicillin resistant S. Aureus (MRSA)
7. "its in our blood": treats MRSA bacteremia
8. Tricuspid peaks: treats Staph endocarditis
9. Protestor with protective rusty chest place: ineffective for pneumonia
10. Chicken leg bite: myopathy and rarely rhabdomyolysis
11. CrisPy chicken: monitor creatine phosphokinase (CPK) levels



Tetracycline's: Le Tour de Cyclines

1. Bicycle: tetracycline
2. Typewriter: acts on bacterial ribosome, inhibiting translation. 30s
3. 30 sec timer: bind irreversibly to 30s ribosomal subunit
4. Prism: broad spectrum
5. No mercy pharaoh: activity against MRSA
6. Ticks: activity against tick borne bacteria (Rickettsia, Erlichia, Francisella, Borrelia)
7. Bruce the cow: activity against Brucella
8. Sheep with heart bell: treats culture negative endocarditis caused by coxiella
9. Squirrel with fleas: activity against yersenia
10. Clam seat: treats chlamydial cervicitis and urethritis
11. Uterus shape bicycle: treats chlamydial pelvic inflammatory disease
12. Clam bra: treats chlamydial bronchitis and atypical pneumonia
13. Cross country skier: treats atypical "walking" pneumonia by Mycoplasma
14. White capped mountains: treat acne
15. Medals: multivalent cations (calcium, iron, magnesium) decrease absorption
16. Child grabbing medal: Causes tooth discoloration in young children
17. Tarrantula: deposits in fetal teeth and bone
18. Mud puddle: GI side effects (nausea, vomiting, diarrhea)
19. Sensitive photo: Photosensitivity
20. Fane cone: Fanconi syndrome (type 2 RTA) associated with use of expired tetracycline's
21. Bike pump: resistance via efflux pumps, and alteration of ribosome
22. Sewage pipe: eliminated fecally, safe in renal failure patients



Macrolides: The Crow

1. Crow: Macrolides
2. Typewriter: acts on bacterial 50s ribosomal subunit, inhibiting translocation
3. Paper jam: bacteriostatic
4. Azithromycin and Clarithromycin
5. Boarded soldier: treats Bordetella pertussis
6. Family photo: prophylaxis for Bordetella pertussis for family members
7. Rusty chest plate: azithromycin and clarithromycin treat community acquired pneumonia caused by Strep pneumoniae, H Flu, and Moraxella catarrhallis
8. pencil wound: macrolides can be used in patients with a H/O penicillin allergy
9. Cold walking snowshoer: azithromycin treats atypical pneumonia caused by M. Pneumoniae
10. Legion of ships: treats walking pneumonia caused by legionella
11. Clam lady: azithromycin treats atypical chlamydia pneumoniae, and urethritis and cervicitis caused by Chlamydia
12. Clam lady holding a baby: oral erythromycin treats neonatal conjunctivitis can pneumonia caused by chlamydia trachomatis
13. Red crow: erythromycin drops treat neonatal conjunctivitis caused by N. Gonorrhea
14. Vampire babe: clindamycin plus atovaquone treats babesiosis
15. Bull neck: erythromycin treats diphtheria
16. Bart the leopard: azithromycin treats infections with Bartonella
17. Caged mockingbird: azithromycin and clarithromycin have activity against mycobacterium avium
18. A-Z: azithromycin less cyp450 interaction than clarithromycin
19. Paper under bird with 50: Azithromycin prophylaxis for patients CD4<50
20. Brown puddle: increased GI motility
21. Yellow complexion: Acute cholestatic jaundice
22. Torsades strip: prolonged QT interval
23. Broken chrome bumper: CYP450 inhibit think ë metabolism of warfarin
24. Keep Clear: clarithromycin
25. Helicopter: clarithromycin, amoxicillin, and PPI are triple therapy for H. Pylori



Clindamycin: keeping it clean at the Anaerobix gym

1. Keep Clean: Clindamycin
2. Typewriter: Typewriter: acts on bacterial 50s ribosomal subunit, inhibiting translocation
3. Paper Jam: Bacteristatic
4. Purple Coccoid Weights: Activity against staph and strep
5. Pie and red puffy glove: treats S' Pyogenes (GAS) and soft tissue infections (cellulitis)
6. No Mercy tattoo: Activity against MRSA
7. Gas Mask: Anaerobe activity
8. Lung stains with holes: excellent penetration into abscesses
9. Choking on Bacteraid: trats oral infections and aspiration pneumonia caused by Bacteroides fragilis
10. Perforated pants: activity against clostridium perfringens
11. Snow-capped mountains: topical clindamycin treats moderate to severe inflammatory acne
12. Uterus Machine: clindamycin plus gentamicin (gently cleaning the uterus) treats polymicrobial female genital tract infection.
13. Judo practitioner with Sai: gentamicin paired with clindamycin for broad coverage
14. Venus fly trap garden: treats bacterial vaginosis from gardenella vaginallis
15. Brown puddle: Diarrhea
16. Brown geyser: pseudomembranous colitis caused by C.Diff



Chloramphenicol: A splash of grey

1. Typewriter: binds reversibly to 50s ribosome, inhibiting peptide bond formation and halting translation
2. Paper Jam: bacteriostatic
3. Meningitis space helmet: empiric treatment for meningitis in developing countries (S. Pneumo, H Flu, N Meningitidis)
4. Earth Ball: used in developing countries
5. Spotted hand and foot rock climber: alternative agent in serious rickettsial infections (rocky mountain spotted fever) useful in pregnant women
6. Deflated red inner tubes: anemia due to dose related reversible suppression of RBC production
7. Clear plastic bone: aplastic anemia
8. Grey Baby: accumulation of the drug in newborns (due to ineffective glucuronic acid conjugation system) causes flaccidity, hypothermia, shock (floatation device looks like a liver)

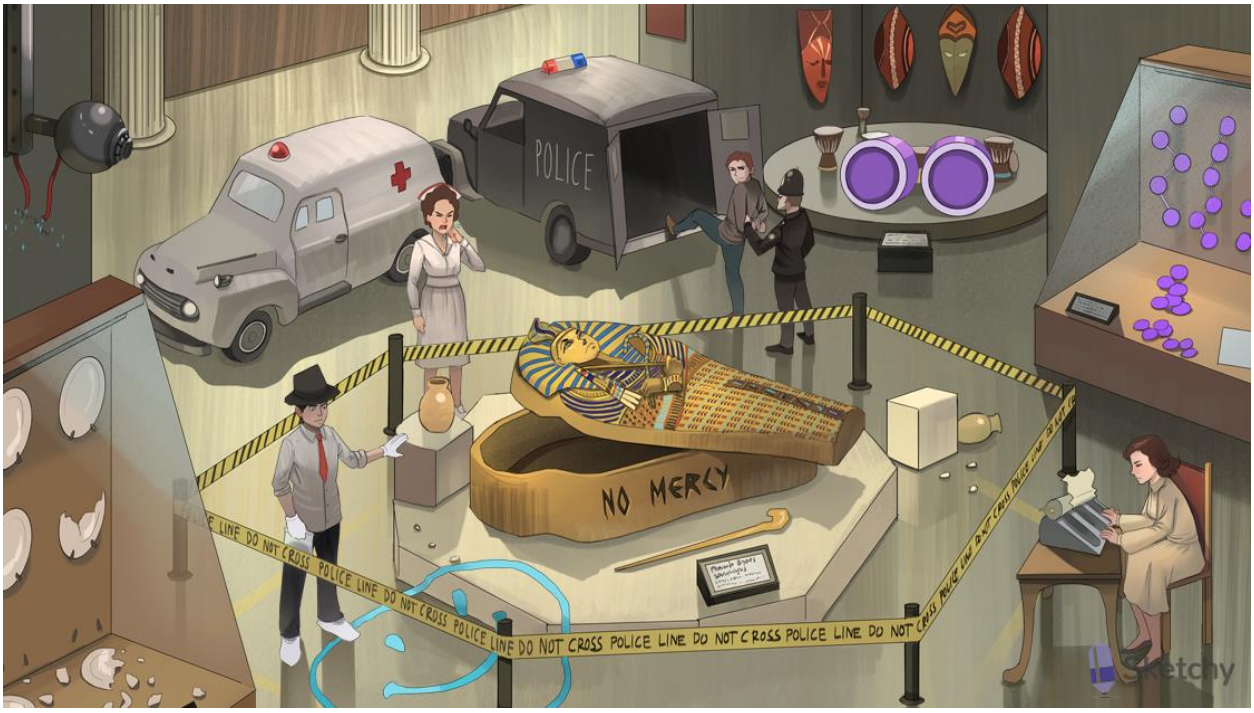

Linezolid: Do Not Cross

1. Police Line: linezolid
2. Typewriter: binds reversibly to 50s ribosome, inhibiting peptide bond formation and halting translation
3. Purple jewels in cluster and chains: activity against gram positive bacteria (staph, strep, enterococcus)
4. For treatment of serious gram positive infections
5. No mercy pharaoh: MRSA activity
6. Coughing nurse with lung stains: treats nosocomial MRSA infections (hospital acquired pneumonia)
7. Resisting van: activity against vancomycin resistant bacterial strains
8. Purple double bass drum: activity against vancomycin enterococcus
9. Broken plates: thrombocytopenia
10. Cut security camera wire: optic neuropathy (and peripheral neuropathy)
11. Gloves and shoe covers: stocking-glove peripheral neuropathy
12. Happy face: serotonin syndrome (weak inhibitor of MAOI, so can cause serotonin syndrome)



Aminoglycosides: Feudal Assassins

1. Kanji translator: acts on the bacterial ribosome, halting translation
2. 30 min: binds irreversibly to the 30s ribosomal subunit, inhibiting formation of initiation complex
3. Dead translator: bactericidal
4. Smeared Kanji: misreading of MRNA
5. Sai: aminoglycoside
6. Ninja suspended from minute hand:" binding to the 30s ribosomal subunit
7. Red bacilli bricks: activity against aerobic gram negatives, actively transported cell membrane
8. Beta-lactam bomb: coupled with cell wall active drugs (beta-lactams, vancomycin) to allow entry into the cell
9. Bellows: transported into bacteria via an oxygen dependent process (aerobic bacteria)
10. Ivy rope: ivy administration
11. Ninjutsu master: neomycin
12. Secret colon tunnel: neomycin remains active in the GI tract until secreted with feces
13. Scalpel shuriken: neomycin used in bowel prep before colorectal surgery
14. Pair of mice: paromycin, luminal agent active against parasital infections
15. Sai master: streptomycin
16. Rabbit ears: streptomycin treats tularemia caused by Francisella tularensis
17. Squirrels with fleas: streptomycin treats the plague caused by Yersinia pestis
18. Judo master: gentamicin treats resistant gram negative infections (Enterobacter, serratia, Klebsiella)
19. Red Shogun: systemic gram negative infections (septicemia, nosocomial RTI, complicated UTI, intra-abdominal infection)
20. Mona Lisa: activity against pseudomonas (aerobic gram negative)
21. Cobra ninja: tobramycin (activity similar to gentamycin)
22. Double purple taiko drums: activity against enterococcus when coupled with a cell wall active agent (penicillin, vancomycin)
23. Inactivating ninja stars: inactivated by an acetylation enzyme (E. faecium against tobramycin)
24. Katana master: amikacin (Activity against E. faecium w/ acetylation enzymes)
25. Mona Lisa: activity against pseudomonas (gentamycin, tobramycin, amikacin)
26. Cracked gong from flying sai: ototoxicity (vestibular or cochlear damage)
27. Sai in flank armor: nephrotoxicity (due to acute tubular necrosis)
28. Rusty downspout draining brown muddy water: acute tubular necrosis (brown casts)
29. Peaks and troughs in undulating terrain: monitoring of serum drug levels
30. Grave with post synaptic outlet: myasthenia gravis is an absolute contraindication to aminoglycoside use, due to post NMJ Blockade
31. Tarantula and pregnant women with ears covered: Teratogenic – deafness in newborn



TMP/SMX and Pyramethamine/sulfadiazine: Trick or treat, smell my sulfa drugs

1. Panda: PABA – intermediate in folate synthesis
2. Cookies resemble purines: this is the step that PAPA is beginning of the folate pathway to make purines and then DNA
3. 2 leaves on first step: dihydrofolic acid
4. 4 leaves on second step: tetrahydrofolic acid
5. Rotten sulfa eggs: sulfamethoxazole
6. Panda dropping: MX is a paba analog that blocks dihydropterate synthetase
7. Toilet paper: TMP
8. 2 leaves ducking: TMP blocks dihydrofolate reductase
9. Bladder cup and Porta Potty: 1st line treatment for UTI
10. Egg down pants: Treats acute prostatitis
11. Red porta potty: activity against gram negative GI and urinary tract bacteria
12. No Mercy: activity against MRSA
13. Card dealing cowboy: activity against nocardia
14. Purple fence: activity against gram positives MRSA and Nocardia
15. Old ping pong man in PJ's w/ cane: treats pneumocystis jirovecii pneumonia (PJP)
16. Cane: immunocompromised
17. Address 200: PJP prophylaxis for cd4<200
18. Ghandi cat: Prythemain/sulfadizine treat toxoplasmosis caused by toxoplasma gondii
19. Address 100: toxoplasmosis prophylaxis with TMP/SMX for CD4 <100
20. Dyed suldur eggs: sulfadiazine
21. Pyramid withc hat: pyramathamine
22. Empty pan: pancytopenia
23. Red fireworks: megaloblastic fireworks
24. Tarantula: teratogen in the 1st trimester anti-folate effects cause neural tube defects
25. Sweaty itchy red devil: sulfa allergy – fever, urticarial, rash
26. Broken G6PD-Free fruit: Hemolytic anemia in G6PD deficiency
27. Bites and seeds: Bite cells and Heinz bodies seen in RBC's
28. Red mask sloughing off: stevens-johnson syndrome
29. Mad scientist with 4 tubes of acid: type IV renal tubular acidosis
30. K shape: Type IV RTA leads to hyperkalemia
31. Kidney bag with little blue candies: interstitial nephritis
32. Flash Photo: photosensitivity
33. Yellow candy corn: kernicterus in the neonate (sulfonamides when used in the lath month of pregnancy displace bilirubin in the neonate)
34. Displaced photos from album: sulfonamides displace drugs from albumin (warfarin)
35. Bloody mom: warfarin displaced from albumin caused over anticoagulation and bleeding
36. Vandalized Chrome bumper: inhibition of cytochrome 450
37. Wolf Head – causes drug induced lupus



Fluoroquinolones: A Nordic Spring

1. Flowers: Fluoroquinolones
2. Mostly red: mainly indicated for gram negatives
3. Unwinding braid: inhibit bacterial DNA gyrase (Topoisomerase)
4. Red bladder cup: treat gram negative UTI's (E. coli and proteus)
5. Mona Lisa elevating (levo) and sipping (cipro) from Bladder cup: Complicated UTI's, levofloxacin and ciprofloxacin treat UTI caused by Pseudomonas
6. Milky kidney flask: empiric treatment for pyelonephritis
7. Flower bulb down pants: treat acute prostatitis
8. Gastrointestinal feast: treat gram negative causes of gastroenteritis (shigella, E. Cola, Salmonella)
9. Salmon: treat salmonella gastroenteritis
10. Fish Bones: treat gram negative salmonella osteomyelitis
11. Sickle: sickle cell patients are at increased risk of Salmonella osteomyelitis
12. Purple flowers and Lung axe: treat anthrax caused by B. Anthracis
13. Rusty lung chest plate: respiratory quinolones treat community acquired pneumonia (s. Pneumonia)
14. Cold walking snowshoed: respiratory quinolones treat atypical "walking " pneumonia caused by mycoplasma pneumonia (levofloxacin an moxifloxacin)
15. Legion of ships: respiratory quinolones treat atypical pneumonia caused by Legionella
16. Medals: divalent and trivalent cations (calcium, iron, magnesium, decrease absorption
17. Torsade's strip: risk of prolonged QT interval
18. Puking guy: GI Side effects N/V
19. Old kin gnawing on tendon: risk of tendon and cartilage damage in the elderly
20. Moon facies shield: risk of tendon rupture in steroid users
21. Tarantula: teratogenic – damage to growing cartilage
22. Child gnawing cartilage: not recommended for children under 10 years of age



Metronidazole

1. Mr. Fragillis stabbed in the abdomen: Coverage of polymicrobial anaerobic infections (intra-abdominal infections)
2. Broken helix: free radical metabolites disrupt bacterial DNA (form free radicals) Bacteriocidal
3. Do not enter: activity against Entamoeba histolytica (liver abcess)
4. Colonel giardia with the protozoan shield: activity against giardia
5. Mr. trichomonas with the strawberry: treats vaginitis and cervicitis caused by protozoal infection
6. Mrs. Trichomonas: treat both patient and partner
7. Mrs Gardner with the fly trap: treats bacterial vaginosis caused by gardenella
8. Helicopter: substitute for amoxicillin in the triple therapy for helicon pylori infection in penicillin allergic patients
9. Mlle. Clostridium with the gas mask: activity against anartobic bacteria (bacteroides, prevotta, fusobacterium, clostridium)
10. Clindamycin above the diaphragm, metronidazole below
11. Chocolate fondu fountain: treats pseudomembranous colitis caused by clostridium
12. “no drinking on metro”: concurrent ingestion of alcohol results in a disulfuram like reaction (flushing, tachycardia, nausea, vomiting)
13.



RIPE: The Magnificent 4 – used against mycobacterium infections

1. RIPE: Combination of rifampin, isoniazid, pyrazinamide, and ethambutol used to prevent development of resistance
2. 2 phases of treatment: 4 drugs for 2 months followed by 2 drugs (isoniazid and rifampin) for 4 months
3. **Isolated ranger: Isoniazid – can be used as a single agent treatment for latent TB**
4. Middle lobe bullet hole: primary TB (often presents as middle lobe cavity)
5. Sleeping: INH can be used alone to treat latent TB infections
6. Mycolic acid cacti on wall: INH works at the bacterial cell wall inhibiting mycolic acid production
7. Mycobacteria cowboy shot off wall: INH acts on the mycobacterial cell wall by inhibiting mycolic acid production
8. Aggravated G Tailed Cat: INH is activated by catalase-peroxidase (KatG) (tail makes a G Shape)
9. Silenced G tailed cat: resistance to INH by downregulating KatG
10. Bandit in stockings and gloves: INH may cause peripheral neuropathy
11. Slow acetyl-gunslinger: INH metabolized by the liver enzyme N-acetyltransferase – slow acetylators have higher risk of side effects
12. Pair of dices (sixes) Neuropathy is caused by a Vit B6 excretion promoted by INH, INH promotes and excretion
13. Ungloved hand holding dice: administration of INH and pyridoxine prevents peripheral neuropathy
14. Motion lines: INH may cause seizures
15. Cow liver spot: hepatotoxicity associated with all RIPE therapy drugs
16. Raised LFT Flag: INH causes an asymptomatic rise in aminotransferases
17. WOLF: INH may cause drug induced lupus
18. MUD PILES: INH may cause anion gap metabolic acidosis
19. Broken chrome bumper: INH inhibits cytochrome P450
20. **The Rifle: Rifampin**
21. Speeding Chrome bumper: rifampin activated cytochrome P450
22. Shot RNA track switch: rifampin bind to bacterial DNA dependent RNA polymerase deactivated by Rifampin, this is where resistance will develop if used alone.
23. Guy clutching close to carriage driver: Rifampin prophylactic monotherapy in close contacts of H. FLU and N. Meningitides
24. Meningitis Mohawk: N. Meningitids
25. H Plane: H. flu prophylaxis
26. Liver spot on cow: Hepatotoxic in RIPE therapy
27. Guy hurling orange: Rifampin may produce orange body fluids
28. **Ethyl the cow girl: ethambutol**
29. Arabian horse at the carbohydrate wall “ethambutol at the wall”: ethambutol blocks arabinosyl transferase, inhibiting carbohydrate formation at the cell wall
30. Halt: ethambutol is bacteriostatic
31. Red-green blinders: optic neuritis (loss of visual acuity, red green color blindness)
32. **The Pyro: pyrazinamide**
33. Needles: pyrazinamide may cause hyperuricemia and needle shaped uric acid crystal formation
34. Yell ball on toe: pyrazinamide may precipitate gout attacks

Cow liver spot: can be hepatotoxic



Leprosy Drugs:

1. Caged mockingbird: mycobacterium avium complex (MAC)
2. Crows: a macrolide (azithromycin or clarithromycin) combined with ethambutol for MAC infections
3. Sherrif ethel: ethambutol
4. Immunocompromised cane: MAC is a common cause of disseminated disease in AIDS patients
5. Speed limit 50: macrolide prophylaxis for MAC when CD4 <50 above 50, most likely "ordinary" TB, even in HIV pt.
6. Buttes: rifabutin (may be added as a third agent to combat MAC infections)
7. Rifle: rifampin
8. Speeding chrome bumper: rifampin and rifabutin activate CYP450
9. Leaping armadillo: mycobacterium leprae
10. Deputy zone: Dapsone
11. Multi lobed sand time: agranulocytosis
12. Bite and seeds: bite cells and Heinz bodies seen in RBC's
13. Brocken G6PD-free fruit: hemolytic anemia in G6PD deficiency
14. Cloth: clofazamine treats lepromatous leprosy
15. Lion bandanna: leonine facies seen in lepromatous leprosy
16. Rifle rifampin treats leprosy caused by mycobacterium leprae



5.1 Amphotericin, flucytosine, nystatin

1. **Amphibian: amphotericin**
2. Glass separator: represent fungal outer cell wall
3. Non sterol: fungal cell membrane composed of ergosterol, not your usual cholesterol
4. Holes in the aquarium: Amphotericin and nystatin bind to ergosterol to form holes in the cell membrane leading to cell death
5. Resistance to amphotericin will revolve around changing components to the cell membrane, ie decreasing the amount of ergosterol
6. Organ systems: amphotericin treats severe systemic fungal infections
7. Ivy on aquarium: IV administration
8. Frog bull neck: liposomal drug formation
9. Cholesterol necktie: Amphotericin toxicity results from non-selective binding to mammalian cholesterol membranes
10. Fainting: hypotension and headache
11. Frog that is red hot on fire: “Shake and bake” fevers and chills
12. Tongue on brain: intrathecal administration of amphotericin to treat fungal CNS infections
13. Motion lines: seizure and other CNS side effects
14. Blue brainy pattern: thrombophlebitis
15. 1 shaped graduated cylinder of acid: renal tubular acidosis type 1
16. Banana peel: hypokalemia
17. Magnet in sink: renal magnesium wasting
18. Emergency Saline wash: volume expansion with IV normal saline before drug expansion
19. Drained kidney: anemia due to decreased EPO production by kidney
20. **Flute: flucytosine**
21. C turned to U: cytosine deaminase converts flucytosine (a fluorinated cytosine) into 5-Flourouracil
22. Frog smeared double helix and single strand: Flucytosine halts fungal DNA and RNA synthesis, fungal dna replication or fungal protein synthesis is inhibited
23. Flucytosine and amphotericin combo used treats Cryptococcus
24. **Nyce: nystatin (same MOA as amphotericin) binding ergosterol to form holes in the cell membrane**
25. Canada: nystatin is active against Candida
26. Snow on crotch: typical nystatin treats mucocutaneous candidiasis (vaginal candidiasis)
27. Drinking fountain: nystatin is used as a rinse for oral candidiasis
28.



5.2 Azoles

1. Pine cones: cone-azoles antifungals
2. Emerald perimeter: ergosterol comprises fungal cell membrane
3. Munchkins walking: Inhibition of ergosterol synthesis from linosterol
4. Crushed emerald builder: inhibition of ergosterol synthesis
5. Lane closed: lanosterol conversion to ergosterol is inhibited by azoles
6. Broken chrome bumper: inhibition of cytochrome CYP-450
7. All azole drugs are prone to drug interactions
8. **Car crushing cortex: Voriconizole** inhibition of CYP-450, dose reduction of cyclosporine, tacrolimyus and statins is required
9. Blurry flashes: vorconazole may cause visual disturbances, blurry or flashes of light
10. Sepia tone: voriconazole may cause changes in color vision
11. Aspiration scarecrow with lung hyphae: voriconazole treats invasive aspergillosis
12. Canada: voriconazole treats candida infections (esophagitis with AIDS patients)
13. **Flying monkey: fluconazole**
14. Canada: fluconazole treats Candida infections
15. White patches: easily scraped off patches of mucocutaneous candidiasis
16. Snow on crotch: one time oral dose of fluconazole treats vaginal candidiasis
17. Snow in gutter: systemic fluconazole treats candida stomatitis and esophagitis
18. Crypt: fluconazole treats cryptococcal meningitis
19. Menegitis Mohawk helmets: fluconazole has high high levels of CNS penetration
20. Good witch: itraconazole
21. **Butterfly wings: itraconazole treats systemic infections with dimorphic fungi (histoplasmosis, blastomycosis, coccidoidomycosis, sporothrix) itraconazole for those with two iterations**
22. Tarnished ruby slippers: itraconazole treats onchymycosis and dermatophytosis
23. Tin man: tinea
24. **Close trim: topical clotrimazole treats tinea infections**
25. **My cone: topical miconazole treats tinea infections**
26. Snow on crotch: clotrimazole and miconazole treat vaginal candidiasis
27. Tinman's key: topical ketonazole treats dermatomycosis
28. Adrenal lock: Ketoconazole inhibits 17,20-desmolase, the first step of steroid synthesis from cholesterol
29. Male and female symbols: ketoconazole inhibits production of androgens and estrogens
30. Moon face: ketoconazole inhibits overproduction of adrenal cortisol
31. Ketoconazole can have anti-androgenic side effects, including gynecomastia



5.3 Griseofulvin, terbanifine, echinocandins

1. Rusty tin man: dermatophytic infections (tinea corpis, tinea pedis, tinea cruris)
2. **Grease in mouth: oral griseofulvin** treats dermatophytosis
3. Tin man hat: oral griseofulvin and terbanifine are first line therapy for tinea corpis in children, this combination an also be used to treat dermatophyte infections of the nails.
4. Broken spindly vines: griseofulvin binds fungal cell microtubules, halting metaphase
5. Greases up chrome bumper: griseofulvin activates cytochrome P-450
6. Turban: terbanifine
7. Little tin man: topical terbanifine is used to treat dermatophytes
8. Tin man hat: oral griseofulvin and terbanifine are first line therapy for tinea capitis in children
9. Biting nails: oral terbinafine treats onchymychosis
10. Non sterol: fungal cell membrane composed of ergosterol. Not your usual cholesterol
11. Squealing pig pen: terbinafine inhibits fungal squalene epoxidase causing accumulation of squalene.
12. Mud puddles: Gi Side effects
13. Liver spot: terbinafine leads to hepatotoxicity
14. **Echino-Canadian fur cap: echinocandins (caspofungin, micafungin, anidulafungin)**
15. Crumbling brick wall: echionocandins inhibit beta 1-3 glucan of the cell wall
16. Poly saccharide shaped wall;: echinocandins inhibit the synthesis of beta 1,3 glucan in the cell wall. NOT THE CELL MEMBRANE, and inhibition of POLYSACCHARIDE synthese NOT ERGOSTEROL
17. Canada: Echinocandins have excellent activity against candida
18. Ivy: echinocandins are delivered IV for systemic candida infections
19. Exhaust pipe with snow: echinocandins treat esophageal candidiasis
20. Scarecrow with lung hyphae: echinocandins treat invasive aspergillus
21.



6.1 – NRTI's

1. Knights of the round table: NRTI's
2. Revverso transcriptum: reverse transcriptase
3. Nucleoside shaped mace: NRTI's are nucleotides or nucleosides
4. Broken spike: absent hydroxyl at 3' end
5. 3 and 5 on page: Inhibition of 3'→5' phosphodiester bond formation
6. Broken double helix bookmark: incorporation into growing viral DNA strand causes premature chain termination
7. Activating P scroll: nucleosides need phosphorylation by cellular enzymes in order to be activated.
8. Woodgrain Cisternae: mitochondrial toxicity
9. Sour milk: NRTI's may cause lactic acidosis
10. Feast: -Dine is the suffix used
11. **Sir lancelot: lamivudine**
12. Stockings and gloves: Lamivudine, stavudine, and didanosine may cause peripheral neuropathy
13. Hippie hippo sigil: lamivudine and tenofovir treat hep B infection (peace sign theme)
14. **Sir Tristan: tenofovir**
15. Actively sailing the tide: tenofivir is a nucleoside and does not need activation by phosphorylation
16. Hippie Hippo symbol: lamivudine and tenofovir treat Hep B infection
17. **Princess Izoide and dove sigil: Zidovudine**
18. Zidovudine is used during pregnancy and breastfeeding to reduce vertical infection
19. Devoured marrow: zidovudine may cause myelosuppression
20. White dress: Zidovudine may cause anemia
21. Multilobed sand timer: zidovudine may cause agranulocytopenia
22. Central adiposity: zidovudine and stavudine may cause lipodystrophy
23. **Sir steeve: stavudine**
24. Central adiposity: zidovudine and stavudine may cause lipodystrophy
25. Stockings and gloves: Lamivudine, stavudine, and didanosine may cause peripheral neuropathy
26. **Sir dan: Didanosine**
27. Squeezed sponge: didanosine cause dose dependent pancreatitis
28. Stockings and gloves: Lamivudine, stavudine, and didanosine may cause peripheral neuropathy
29. **Abaracadabra: abacravir**
30. Spell book opened to HLA-b Pg 57:01: hypersensitivity associated with the HLA-B 57:01 allele
31. Delayed reaction to rash: abacavir may cause a delayed type 4 hypersensitivity reaction
32. **Excalibur: emtricitabine**
33. Dark Gloves: emtricitamine may cause hyperpigmentation of palms and soles.



6.2 NNRTI's

1. Elven pine forest: nevarapine
2. Queen Elfavirenz: elfavirenz
3. Princess delavir: delaviridine, can NOT be used in pregnancy
4. Outside Camelot: not nights of the round table and do not need a phosphorylation signal
5. Fleeing P signal: NNRTI's bind directly and are not phosphorylated by intracellular enzymes. Resulting in allosteric inhibition preventing replication of DNA
6. Arrow in reverse transcriptum: direct binding and allosteric inhibition of HIV reverse transcriptase
7. Broken double helix bookmark: halted DNA polymerase activity
8. Jaundiced yellow glow and liver spot on stag: Liver failure can occur within 6 weeks of starting therapy.
9. Mesmerized by hallucinations: side effects of CNS symptoms (dizziness, drowsiness, headache, and psychosis)
10. Dark moon: side effect of insomnia and nightmares
11. Tarantula: teratogenic
12. Chrome bumper: varying effects on the cytochrome P-450 system
13. Sloughing off mask: side effects of stevens Johnson syndrome
14.



6.3 Protease inhibitors

1. Guinever: -navir suffix of protease inhibitors
2. Camelot in the distance: these are not knights of the round table and do not need a phosphorylation signal
3. Knight riding furiously to castle, fleeing P signal: protease inhibitors are not phosphorylated by intracellular enzymes
4. Sword in the stone: protease inhibitor
5. Immature knight: virion remains immature, blocked by the protease
6. Paul the village blacksmith: POL gene codes for production of HIV enzymes, resistance mechanism will be developed in varying POL genes. Protease inhibitors are never used as monotherapy.
7. Elevated candy jar: side effect of hyperglycemia in diabetes sue to insulin resistance
8. Elevated butter: side effect of dyslipidemia
9. Central adiposity: side effect of lipodystrophy
10. Indigo princess: indinavir
11. Stones in kidney fountain: indinavir may cause nephrolithiasis
12. Adequate hydration helps to prevent nephrolithiasis
13. Brocken chrome bumper due to village kids: inhibition of cytochrome CYP-450
14. Right on!: Ritonavir has greatest cytochrome P-450 inhibitory effect and boosts concentration of other protease inhibitors
15. Speeding rifle: rifampin activates cytochrome P-450 and deceases the concentration of protease inhibitors.



6.4 Miraviroc, fusion inhibitors, integrase inhibitor

1. Seized castle with T shaped crosses: HIV infects CD4+ T cells, macrophages and dendritic cells
2. Invading ship: budding virion invades the next cell
3. Gagged prisoners in the core of the ship: gag structural gene codes for virion core proteins
4. 24 hour sundial: gag structural gene codes for virion core proteins (p24, p7)
5. Envoy coming ashore: env structural gene encodes viral envelope proteins for infiltration (gp41 and gp120)
6. 120 battering ram: surface glycoprotein gp20 allows HIV to gain entry
7. Helper squire and CCR5 banner: gp120 binds to the host CD4 molecule and chemokine receptor (CXCR4 and CCR5)
8. **Mare with CCR5 banner: the entry inhibitor maraviroc binds to CCR5, must determine virus type**
9. 41 grappling hook: surface glycoprotein gp41 facilitates HIV fusion
10. Fusion hook deflector: fusion inhibitor enfuvirtide binds gp41
11. All of these surface proteins came from the ENV protein, unloaded from the envoy
12. Endoplasmic reef: env encoded surface proteins are first sent to the endoplasmic reticulum
13. Doblin army: reverse transcriptase transcribes viral RNA into soluble stranded DNA
14. Reverso tanscriptum spell: reverse transcriptase
15. King Arthur and the elf queen elfavir: NRTI's and NNRTI's inhibit reverse transcriptase
16. Resistance is due to viral POL gene, if POL gene is mutated it will be immune to NRTI's, NNRTI's, Protease inhibitors, and Integrase inhibitors
17. Paul the blacksmith producing swords, spell books, and keys: POL gene encodes for protease, reverse transcriptase, and integrase
18. Double helix staircase behind keyhole: integrase allows viral DNA to integrate with host cell DNA
19. Key deflector: the integrase inhibitor raltegravir binds viral integrase
20. Crispy chicken with bite: integrase inhibitors may cause rhabdomyolysis
21.



7.1 Interferon alpha, beta, gamma

1. Infected manager releasing cyto-coins: interferons are immunomodulatory cytokines released from virus infected cells
2. Luke: interleukins upregulate interferon synthesis in infected cells
3. **Interferon alpha: placoderm man**
4. Hippo: interferon alpha treats hepatitis B and C infections
5. Hairy creature interferon treats hairy cell leukemia
6. Melanotic ghost: interferon alpha treats malignant melanoma
7. Posies: interferon alpha treats Kaposi sarcoma from HHV 8
8. Accumulated tokens: interferon alpha treats condyloma accuminata caused by HPV
9. Plush cancer crab in kidney machine: interferon alpha treats renal cell carcinoma
10. Kid passed out at arcade: Interferon alpha may cause a Flu like syndrome, or more severe symptoms including profound fatigue, retinopathy, and confusion
11. Devoured marrow: interferon alpha may cause myelosuppression with zidovudine
12. Plush wolf: interferon alpha may cause Lupus
13. **Beta invaders: interferon beta**
14. "time and space" interferon beta treats MS
15. **Gammaga: Interferon gamma**
16. Asteroids: destroyed granulomas asteroids: interferon gamma treats chronic granulomatous disease (GCD)
17.



7.2 ribavirin, sofosbuvir, simeprevir

1. Sea hippo: hepatitis C
2. Genotype?: Identify the HCV Genotype to select treatment
3. Stony liver under microscope: liver fibrosis is assessed before beginning treatment
4. Photographic evidence: all patients with virologic evidence of chronic HCV infection should be considered for treatment
5. Sustained search for 6 months: sustained viriologic response (SVR) – HCV RNA not detected by PCR for 6 months after stopping treatment
6. Alpha shaped antenna: once weekly pegylated interferon alpha is the traditional; standard treatment (with daily ribavirin)
7. [RIBS: daily ribavirin is the traditional standard treatment (with once weekly pegylated-interferon alpha)
8. Purine shaped stakes: ribavirin is a guanosine nucleoside analog
9. 3 pepper shakers: ribavirin is phosphorylated 3 times by intracellular enzymes into its active form.
10. Red cell fruits tumbling off the plate and lysing: Dose dependent hemolytic anemia
11. Tarantula: ribavirin is teratogenic
12. RXV grave: ribavirin is classically used for RSV txt
13. **Sofa with a nucleoside pattern: sofosabuvir a nucleoside analog that inhibits the NS5B rna polymerase**
14. Disrupts RNA rope: sofosbuvir inhibits NS5B RNA production
15. Fatigued explorer: side effects of sofosbuvir include fatigue and nausea
16. **Stuck machine: NS3/4 protease inhibitor**
17. Simmering: simprevir (a protease)
18. Flash photo: side effects of simeprevire include phototoxity and rash
19. Broken chrome bumper: simprevir is a cyp450 inhibitor
20. North Sea under investigation: new investigational drugs include second generation NS3/NS4A protease inhibitors and NS5A inhibitors



8.1 Acyclovir, valacyclovir, famiciclovir

1. Hermes: herpes simplex virus
2. Recycling: acyclovir
3. Purine shaped luggage: guanosine nucleoside analog
4. Hermes with “P” luggage tag: converted to acyclovir monophosphate via virus encoded thymidine kinase
5. Bag checkers with P tags: converted to acyclovir triphosphate by cellular kinases
6. Branching double helix conveyer belts: viral DNA dependent polymerase
7. Baggage jam: acyclovir triphosphate incorporates into replicating DNA, halting synthesis
8. Herpesvirus-encoded thymidine kinase is the rate determine activation
9. Closed baggage check: Absence of thymidine kinase in a herpes strain confers resistance.
10. **Security officer: Cid: Cidofovir**
11. “P”access badge: cidofovir does not require phosphorylation by the viral kinase – active against acyclovir or ganciclovir resistant HSV, CMV, VZV. This may be important with immunocompromised patients
12. Luggage car net: foscarnet is active against acyclovir or ganciclovir resistant HSV, CMV, and VZV
13. Conveyer belt stop switch: Cidofovir and foscarnet directly inhibit viral DNA polymerase
14. **VALet parking: Valacyclovir**
15. Daily rate for frequent flyers: daily valcyclovir suppresses therapy for yearly multiple episodes of recurrence
16. Open mouth: valcyclovir has improved oral bioavailability
17. **Ivy: IV acyclovir treats serious HSV and VZV infections**
18. Red winged helmet: IV acyclovir treats HSV encephalitis
19. Baby Hermes helmet: IV acyclovir treats neonatal infection
20. Zues: varicella zoster virus
21. Shingles: reactivates varicella virus
22. Family value: famcuclovir and valacyclovir are preferred over acyclovir sue to superior activity and less frequent dosing for VZV
23. 3 days: during active shingles infection, valacyclovir and famcyclovir are most effective if given within 3 days of symptom onset
24. Prepare: HSV prophylaxis
25. Cane: HSV prophylaxis important in immunocompromised states
26. Pregnant: HSV prophylaxis important in pregnant women with active recurrent genital herpes
27. Kidney sharps: IV acyclovir can cause interstitial nephritis crystalline nephropathy
28. Adequate hydration prevents renal side effects
29. Uncommon CNS side effects: delirium, confusion, vertigo, hallucinations
30.



8.2 Gancyclovir, Valganciclovir, Foscarnet, cidofovir

1.1 Mega-Lo market: cytolomegalovirus (CMV)

1.2 Can recycle bin: ganciclovir

1.3 Used for organ transplant prophylaxis

1.4 Pizza: hemorrhages and infiltrates of CMV retinitis: ganciclovir

1.5 50 items of less sign: pts will usually present with CD4+ count less than 50 when they have a CMV infection

1.6 G purines in the background: Ganciclovir is a guanosine analog,

1.7 Market worker with P label gun: converted to ganciclovir monophosphate by a virus encoded kinase (UL97) 1st phos step

1.8 Customers with p label guns: converted to ganciclovir triphosphate by cellular kinase

1.9 Grocery jam: ganciclovir triphosphate incorporates into replicating viral DNA, halting synthesis

1.10 Branching double helix conveyer belt: Viral DNA dependent DNA polymerase

1.11 Open mouth: valganciclovir has better oral bioavailability

1.12 Value: valgancyclovir

1.13 Organs on ice: valgancyclovir or ganciclovir is indicated in high-risk solid organ and bone transplant recipients

1.14 Eaten marrow: ganciclovir and valgancyclovir are associated with bone marrow suppression

1.15 Princess Izoide: myelosuppression may be additive in patients receiving zidovudine

1.16 Bypassed P labeler: foscarnet does not require phosphorylation by the viral kinase – active against ganciclovire or acyclovir resistant CMV, HSV, and VZV

1.17 Car net: foscarnet

1.18 Spilled kidney beans: foscarnet may induce renal insufficiency

1.19 Broken milk bottles: foscarnet may cause hypocalcemia

1.20 Falling magnets: foscarnet may cause hypomagnesium

1.21 Banana peel: Foscarnet may cause hypokalemia

1.22 Shaking: foscarnet may cause siezures

1.23 Security officer Cid: Cidofovir

1.24 P access badge: cidofivir does not require the phosphorylation by the viral kinase – active against acyclovir or ganciclovir resistant HSV, CMV, VZV

1.25 Conveyer belt stop switch: cidofovir and foscarnet directly inhibit viral DNA polymerase

1.26 Broken kidney: cidofovir nephrotoxicity, leading to proteinuria, azotemia, and metabolic acidosis

1.27 Probation officer cid stoping the kidneys from falling and pteventing the drug punk from getting alcohol: probenecid blocks the tubular secretion of cidofovir, limiting its toxic effects

1.28 No drugs touching kidney: Probenacid prevents excretion and increases plasma concentrations of many different drugs (penicillin's, methotrexate, NSAIDS)





1.1 Cholinomimetics: I'd Like to buy the world of Acetyl-cola

1. Called a cholinomimetic because they mimic the effects of acetylcholine, the primary NT pf parasympathetic nervous system
2. Acetyl-Cola: Acetylcholine receptor agonists
3. Mime drinking cola: cholinomimetics
4. Smoker: nicotinic acetylcholine receptor
5. Ganglia-like transformers near smoker: nicotinic acetylcholine receptors are found on autonomic ganglia
6. Outlet near smoker: nicotinic acetylcholine receptors are found on skeletal muscle motor end plates
7. Adrenal beanie on smoker: nicotinic acetylcholine receptors are found in the adrenal gland
8. Motorcycle parking spots: Muscarinic acetylcholine receptors (M1, M2, M3)
9. Ion channel news behind smoker: nicotinic receptors act as ion channels that will influx positive ions to polarize a muscle
10. QIQ store: M1, M2, and M3 are coupled to Gq, Gi, and Gq respectively
11. 3 "dags": M1 and M3 are coupled to Gq proteins which activate the IP3-DAG cascade leading to increased intracellular calcium
12. Packed up tent: M2 is coupled to a GI protein which decreases cAMP, notice the down arrows
13. Brain helmet: M1 receptors are found in nerves and the CNS
14. Top of heart with jewels: M2 receptors are found in the atria, the SA and AV node
15. Glandular sponge: M3 receptors are found on the glands,
16. Dilated Nitric Oxide exhaust: M3 receptor activation → nitric oxide release in vascular smooth muscles → increased cGMP and vasodilation
17. Constricted clogged ppe exhaust pipe: atherosclerosis → vascular epithelial damage → direct muscarinic receptor activation → vasoconstriction
18. In average patient muscarinics will cause a drop in blood pressure, all muscarinic can cross to work on other M receptors in high doses
19. Beth with cola: bethanechol (cholinomimetic)
20. Cement pouring from colon spout: muscarinic agonists (bethanechol) increase secretion and motor activity of the gut
21. [Do not obstruct] sign: bethanechol is used to treat non obstructive (non active) gastrointestinal dysmotility (post op ileus, neurogenic ileus)
22. Beth using bladder hose: bethanechol treats urinary retention (neurogenic bladder from spinal cord injury, post pregnancy)
23. Pile o' carp: pilocarpine (cholinomimetic)
24. Dripping carp mouths: pilocarpine increase salivation (sjogrens, radiation damage) dry mouth treatment
25. Round glass: muscarinic agonists (pilocarpine) cause accommodation of the lens, parallel fibers on net represent ciliary muscles
26. Smooth muscle crane with net zonules: pilocarpine contracts the ciliary muscle, increasing aqueous humor outflow (used to treat glaucoma)
27. Constricted hood: pilocarpine causes meiosis, activates the sphincter pupillae muscle to cause pupillary constriction (useful in acute angle glaucoma)
28. Constricted hood blocking carbon fumes: carbachol causes pupillary constriction (useful in acute angle glaucoma)
29. Carbon fumes from smoker: Carbachol is <u>both</u> a muscarinic and nicotinic agonist
30. Marathon challenge: methacholine (cholinomimetic) challenge
31. Challenge: methacholine challenge instigates asthma for pulmonary testing
32. Wheezing man: cholinomimetics (methacholine) contract bronchial smooth muscle which may exacerbate asthma or COPD, also all cholinomimetics can cause peptic ulcers
33. 1-800-Very-Clean: varenicline (nicotinic receptor partial agonist) is used for smoking cessation



1.2 Acetylcholinesterase Inhibitors: Stigmata gravis

1. Indirect view of Acetyl-cola mime: Indirect Cholinomimetics (inhibit acetylcholinesterase) bind either reversibly or irreversibly to acetylcholine to either raise acetylcholine, or increase the length of time acetylcholine is at the synapse
2. Dumpster of acetyl-cola bottles: acetylcholinesterase degrades acetylcholine (aCh)
3. Knocked over dumpster with acetyl-cola spilling out: acetylcholinesterase inhibitors increase synaptic concentrations of Ach
4. Anti-ESTablishment: anti-cholinesterase, AKA acetylcholinesterase inhibitor
5. STGMA: -"-Stigmine" drug suffix of acetylcholinesterase inhibitors
6. Skeletal muscle brick wall: acetylcholinesterase inhibits effects of Ach at the NMJ (increase activity of NICOTINIC Ach receptors) leading to increased strength of contractions
7. Electrical end plate: Motor end plate (at the NMJ)
8. GRAVIS graffiti: myasthenia gravis (MG) → antibodies against nicotinic Ach receptors at motor end plate (skeletal muscle NMJ)
9. Graffiti covering motor end plates: MG causes progressive muscle weakness, Ptosis, diplopia (inactivated nicotinic receptors at motor end plate)
10. **Community PRIDE: PYRIDOstigmine (acetylcholinesterase inhibitor used as long term treatment for MG**)
11. Removing graffiti on end plates: Acetylcholinesterase inhibitors increase Ach at NMJ endplate to outcompete MG antibodies
12. **Neon sign STIGMA: neostigmine (acetylcholinesterase inhibitor used to treat MG)**
13. **Phone Booth: edrophonium (acetylcholinesterase inhibitor that transiently reverses symptoms of MG)**
14. Quarters only: pyridostigmine, neostigmine and edrophonium are quaternary amines and do not penetrate into the CNS (only relives symptoms for 5-15 minutes)
15. Phone in working order: edrophonium REVERSES muscle weakness in undertreated MG patients (POSITIVE tensilon test)
16. Phone Wire tension: tensilon test → edrophonium reverses (positive) or fails to reverse (negative) muscle weakness
17. Phone out of order with anti-esterase graffiti: edrophonium FAILS to reverse muscle weakness during cholinergic crisis (NEGATIVE tensilon test)
18. CURARE crayons stuck in end plate: non-depolarizing neuromuscular blocking agents (tubucurarine, pancuronium, cisatracurium) inhibit nicotinic Ach receptors are NMJ endplate
19. Neon sign store owner kicking out CURARE crayon kid: acetylcholinesterase inhibitors (neostigmine) reverse non-depolarizing neuromuscular blockade
20. SUCKS: Succinylcholine is a depolarizing neuromuscular blocking agent (Nicotinic Ach receptor AGONIST), that overstimulates the NMJ, causing muscles to remain depolarizes and unable to respond to stimulus
21. PHASE-1 cleanup crew getting shocked: initial PHASE-1 of depolarizing blockade is IRREVERSIBLE (acetylcholinesterase inhibitors potentiate blockade)
22. Bladder hose: acetylcholinesterase inhibitors can be used to treat urinary retention (muscarinic activation)
23. PHYS ED center: PHYSostigmine (acetylcholinesterase inhibitor with CENTRAL effects)
24. Atropine in Wonderland: Atropine overdose → "mad as a hatter, Hot as a hare, Blind as a bat (reversed by physostigmine)
25. Deadly nightshade: belladonna flower is a naturally occurring form of atropine (overdose treated by physostigmine)
26. GYM Weeds: Jimson weed is a naturally occurring form of atropine (overdose reversed by physositgmine) "Gardeners mydriasis"
27. PHYS ED teacher reprimanding atropine "artist": physostigmine reverses atropine overdose (peripheral and central effects)
28. "your brain on drugs": physostigmine (and organophosphates) enters CNS to cause central cholinergic effects
29. DUMBBELS: acetylcholinesterase inhibitor toxicity (diarrhea, Urination, Miosis, Bronchospasm, Bradycardia, Lacrimation, salivation, sweating)
30. Weak nicotine kid: Acetylcholinesterase inhibitor toxicity includes flaccid paralysis (NMJ nicotinic Ach receptor over-activation)
31. THIOL spray: insecticides (parathion, maltion, echotiophate) are organophosphates, a type of acetylcholinesterase inhibitor (also includes nerve agents and herbicides)





32. Green fumes: organophosphates are a major cause of acute cholinergic toxicity (DUMBBELSS) 33. "your brain on drugs": physostigmine (and organophosphates) enters CNS to cause cholinergic effects 34. Closing LID on TOXIC spray: praLIDoxime reverses organophosphates toxicity (DUMBBELSS) by hydrolyzing the covalent bond 35. New toxic waste dumpsters: pralidoxime regenerates Acetylcholinesterase at muscarinic and nicotinic receptors (reverses cholinergic toxicity INCLUDING FLACCID PARALYSIS) 36. Atropine Alice on the side of the dumpster: Atropine reverses both peripheral and Central muscarinic toxicity from organophosphate poisoning (pralidoxime is peripheral only) 37. Old Pest control man: Aging of the organophosphate-cholinesterase complex leads to irreversible binding	38. Corroded dumpster: pralidoxime is ineffective once aging of organophosphatecholinesterase complex has occurred **39. Alzheimers GALA: galantime (acetylcholinesterase inhibitor used to treat Alzheimer's disease** **40. Reverse the Stigma: Rivastigmine (acetylcholinesterase inhibitor used to treat Alzheimer disease)** **41. Done with the Puzzle: Donepezil (acetylcholinesterase inhibitor used to treat Alzheimer's disease)** 42. Brain puzzle: galantine, rivastigmine, and donepezil penetrate the CNS





1.3 Anti-muscarinic Drugs: Atropine in Wonderland

1. Motorcycle parking spots: Muscarinic acetylcholine receptors (M1, M2, M3)
2. M3 spot: Reversing into motorcycle parking spot: muscarinic antagonists reversibly block muscarinic receptors
3. Blocked tweedle DUMBBELSS: antimuscarinics block the muscarinic effects of diarrhea, urination, miosis, bronchospasm, bradycardia, lacrimation, salivation
4. Blocked acetyl-cola bottle: anti-muscarinics block the action of acetylcholine at M receptors
5. **Alice: atropine (atropine) prototype**
6. Belladonna flower (deadly nightshade) a natural antimuscarininc flower
7. Jimson weed – natural antimuscarinic alkaloid
8. Large pupil gazing into the distance: antimuscarinics cause pupillary dilation (mydriasis) and cycloplegia (inability to accommodate the lens for near vision)
9. **Seasick sailor outfit: scopolamine is used to treat motion sickness (vestibular nausea) needs to be used prior to feeling sick**
10. Eyepatch: scopolamine transdermal patch is used to treat motion sickness
11. CNS Hat: antimuscarinics (scopolamine) cross the blood-brain barrier and inhibits central M1 receptors
12. Heart with jewel nodes: Antimuscarinics block parasympathetic activation of M2 receptors on the SA and AV nodes (increased HR, and Increased AV conduction)
13. Elevated heart watch: antimuscarinics (atropine) increase HR (useful in the treatment of bradycardia)
14. Heart shield: Heart block (AV block)
15. Falling heart shields: antimuscarinics (atropine) increase AV conduction (useful in the treatment of heart block)
16. **Cat-Ipa-Tio-Tropillar: iprarioprium and tiotropium (M3 muscarinic antagonists**
17. Puffing: ipratropium and tiotropium are inhaled antimuscarinic bronchodilators
18. Blue bloater with punk puffer: ipratropium and tiotropium are useful in the management of COPD (antagonize M3 receptors → bronchodilation, decreased secretions)
19. Long lasting TIO smoke rings: tiotropium dissociates more slowly from the M3 receptor (longer bronchodilator action)
20. **Ox butler: Oxybutynin (M3 muscarinic antagonist) used to relieve bladder spasm after urologic surgery** Or urge incontinence (can't go, but sometimes leak)
21. **Turtle butler: Tolterodine (M3 muscarinic antagonist) used in adult urinary incontinence**
22. Turning off bladder: oxybutynin and tolterodine treat incontinence (antagonize M3 receptors → relax smooth muscle in ureters and bladder wall
23. CENTER over M1: M1 muscarinic receptors are found in the CNS
24. PARKING over M1: M1 receptor antagonists can reduce tremors and rigidity in Parkinson's disease
25. **BENZ parked in M1: Benztropine (centrally acting M1 muscarinic antagonist)**
26. **Tri-Hex car parked in M1: trihexyphenidyl (centrally acting M1 muscarininc antagonist)**
27. Shaking antennae: centrally acting antimuscarinics (benztropine, trihyxyphenidyl) treat tremor and rigidity in Parkinson's (block excess cholinergic activity)
28. Cogwheel: excessive M1 activation is associated with cogwheel rigidity in Parkinson's disease
29. Falling "esxtra parking" cone: antimuscarinics treat extrapyramidal; side effects caused by antipsychotics e.g. dystonia, akathisia, parkinsonism (re-establish dopaminergic-cholinergic balance)
30. Side Effects of Antimuscarinics / anticholinergics
31. Heart with jewel nodes: Antimuscarinics block parasympathetic activation of M2 receptors on the SA and AV nodes (increased HR, and Increased AV conduction)
32. Elevated heart watch: antimuscarinics (atropine) increase HR
33. Hot as a Hare: antimuscarinics inhibit M3 receptors; sweat glands → decreased sweating → hyperthermia
34. Dry as a cracker: antimuscarinics decrease salivation and lacrimation → dry mouth and eyes
35. Blind as a bat: antimuscarinics cause mydriases and cycloplegia → blurred vision
36. High pressure as a kettle: antimuscarinics cause mydriasis → decreased outflow of aequeous humor → acute angle closure glaucoma
37. Mad as a Hatter: antimuscarinics cross BBB and antagonize central M1 receptor → sedation, agitation, hallucination, coma (especially in elderly patients)



2.1 Sympathomimetics: Drugs that mimic the effects of Epinephrine and Norepinephrine

1. Sympathetic Mime: Sympathomimetic Drugs
2. QISS: alpha1, alpha2, beta1, beta2 receptors are coupled to Gq, Gi, Gs, Gs, respectively
3. Alpha scouts: alpha receptor agonists
4. **Single lit candle: alpha 1 agonist**
5. 3 dags: alpha1 receptor coupled to Gq → IP3-DAG cascade
6. "Dag" with bone: IP3-DAG cascade → increased intracellular calcium (smooth muscle cell)
7. Alpha1 scout pulling Red leashes alpha1 activation increases peripheral arterial resistance (vasoconstriction at small arteries, arterioles, precapillary sphincters)
8. Alpha1 scout elevating MAP: alpha1 activation increases mean arterial pressure (MAP)
9. Alpha1 scout pulling blue leashes: alpha1 activation increases venous return (venoconstriction)
10. Alpha 1 scout binoculars: alpha1 activates pupillary dilator muscle causes mydriases (dilation)
11. Alpha1 scout pulling drawstring: alpha 1 activation causes urethral sphincter and prostatic smooth muscle contraction
12. Full bladder canteen: alpha1acticvation causes urinary retention
13. **Two lit alpha candles: alpha2**
14. "No sympathy": alpha2 agonists are sympatholytics (act centrally to decrease sympathetic tone)
15. Packed up alpha2 camp tent: alpha2 receptor coupled to Gi → IP3-DAG cascade leading to decreased cAMP
16. Alpha2 scout packing up presynaptic wire: presynaptic alpha2 receptors cause inhibition of neurotransmitter release
17. Welcome inside mat: Insulin
18. Rolled up welcome inside mat: alpha2 activation at pancreatic islet cells decreases insulin release
19. Alpha2 scout dousing roasting pig: alpha2 activation inhibits lipolysis and release of fatty acids
20. Alpha2 scout emptying water from eyeball hat: activation of alpha2 at ciliary body decreases aqueous humor production
21. Brim of eyeball hat: Brimonidine is an alpha 2 agonist used to treat chronic open angle glaucoma (decreases aqueous humor production)
22. Band cAMP: beta receptor agonists against increase cyclic AMP (cAMP)
23. **Beta1 bugle: beta1 agonist**
24. I <3 Band cAMP shirt: beta1 receptors are found on cardiac myocytes (including SA and AV nodes) causes increase cyclic AMP → increased intracellular calcium which increases contractility and accelerates the heart
25. Elevated heart clock: beta1 activation increases heart rate (SA node)
26. Buff contracted bicep: beta1 activation increases cardiac contractility (cardiac myocytes)
27. Heart hydrant: beta1 activation results in increased cardiac output
28. Open rain umbrella: beta1 activation increases renin release (JGA cells) renin = rainin
29. **Beta2 tuba: beta2 activity**
30. Beta2 camper taking big breath: beta2 activation leads to bronchoDILATION (increased cyclic AMP → activates PKA)
31. Beta2 camper with dilated sleeves: beta2 activation causes coronary and skeletal muscle vasoDILATION → decreases systemic vascular resistance (SVR)
32. Beta2 camper with dangling DIAmond earrings: beta2 activation decreases diastolic blood pressure
33. Beta2 camper roasting pig: beta 2 activation Expressed on human fat cells stimulates lipolysis and release of free fatty acids
34. Beta2 camper producing marshmallows from liver shaped bag: beta2 receptor activation at the liver promotes gluconeogenesis
35. Welcome INSIDE mat: insulin increased, beta2 activation at pancreatic islet cells will cause an increase of insulin release
36. Banana peels: beta2 activation can cause hypokalemia (due to increased insulin activity)
37. Beta2 camper filling eyeball balloon: beta2 activation at ciliary body increases aqueous humor production.





2.1 Sympathomimetics: the drugs

1. **Flannel friends: phenylephrine (alpha1 agonist)**
2. Flannel friend holding single burning candle: phenylephrine is an alpha1 agonist, smooth muscle activation
3. Flannel friend's nasal spray: phenylephrine treats nasal congestion (alpha1 mediated vasoconstriction) reduces edema of nasal mucosa
4. Flannel friends binoculars: phenylephrine causes mydriasis (activates pupillary dilator muscle)
5. Map: Phenylephrine increases MAP (alpha1 increases SVR), increases systolic pressure (alpha1 arteriolar constriction), increases diastolic pressure (alpha1 venous constriction)
6. Flannel friends low dangling heart watch: phenylephrine causes reflex bradycardia (response to alpha1 increase in MAP), this is a baroreceptor mediated mechanism
7. **North compass scout leader: NORepinephrine (alpha>beta1 agonist**
8. North scout blowing beta1 bugle: norepinephrine has some beta1 activity (primarily an ALPHA AGONIST)
9. Norepinephrine increases MAP (alpha1 increase in SVR), increases systolic pressure (alpha1 arteriolar constriction), increases diastolic pressure (alpha1 venous constriction
10. North scouts low dangling heart watch: norepinephrine causes reflex bradycardia (response to alpha1 increase in MAP)
11. North scouts buff contracted bicep: norepinephrine increases cardiac contractility (activates Beta-1)
12. Septic Tank: septic shock (phenylephrine and norepinephrine increase SVR and venous return to treat distributive/hypovolemic shock)
13. Norepinephrine increases PULSE PRESSURE difference between systolic and diastolic (beta1 increase in contractility)
14. "ROL" call sheet held by beta2 tuba player: beta 2 agonists used for bronchodilation have –rol suffix (albuterol, formoterol, salmeterol)
15. **EPIC kiss between alpha and beta camps: EPInephrine (beta>alpha agonist) it's an effective dose dependent vasoconstrictor and cardiac stimulator**
16. Low side of EPIC raft: at LOW doses, epinephrine's BETA Agonist effects predominate
17. Beta2 tuba girls EPIC inhaler: epinephrine caused bronchodilation (beta2 effects)
18. EPIC DIAmond falling off LOW side of raft: at LOW doses, epinephrine decreases DIAstolic pressure (beta-2 vasodilation and decreased SVR)
19. EPIC elevated heart watch and Buff contracted bicep: epinephrine increased heart rate and cardiac contractility (beta1 effects)
20. High side of EPIC raft: at high doses epinephrine's ALPHA AGONIST effects predominate, Vasoconstriction, increased SVR
21. MAP in front of EPIC kiss: Epinephrine increases systolic pressure and decreases diastolic pressure causing an INCREASE IN PULSE PRESSURE, but get an increase in MAP (alpha 1 increase in SVR)
22. Ana + Phil on raft: For anaphylactic shock epinephrine is preferred because alpha 1 counteracts vasodilation, Beta 1 improves blood flow to tissues, and beta 2 opens up the airways
23. **"Just DO Bugling": DOBUtamine (beta1>beta2 agonist)**
24. Beta1 Bugle: dobutamine is primarily a beta 1 agonist "do beta 1 = do but amine"
25. "just do bugling" winding up heart flashlight: dobutamine increases heart rate, contractility, and cardiac output (beta1 effects) to treat refractory heart failure
26. "Just DO Bugling" friend's Beta2 tuba: dobutamine has some beta2 activity (primarily a BETA 1 AGONIST)
27. Map being held by dobutamine character: Dobutamine increases PULSE PRESSURE, difference between systolic and diastolic (beta1 increase in contractility), increases systolic pressure (beta1 increase in CO, decrease diastolic pressure (beta2 arteriolar dilation)
28. Batteries fallen out of heart flashlight: dobutamine can be used in cardiogenic shock
29. Dead heart batteries: cardiogenic shock (dobutamine increases contractility and CO to treat cardiogenic shock)
30. Dobutamine will also be used to induce a heart stress test in people who are unable to physically, this will help to identify areas of ischemia.
31. **"iso-pro-tunnel" between beta1 and beta2 camps: Isoproterenol (beta1 = beta2 agonist)**
32. Tunnel camper's elevated heart watch and contracted bicep: Isoproterenol increases heart rate and contractility (beta-1 effects)
33. Tunnel campers dilated sleeves: isoproterenol causes vasodilation → decreases SVR (beta2 effects)
34. Tunnel Campers Dangling DIAmond earrings: isoproterenol decreases DIAstolic pressure (beta 2 activation and decrease SVR)
35. Tunnel with decreasing lines: Isoproterenol decreases MAP (beta2 decrease in SVR), decreases DIAstolic pressure (beta2 arteriolar dilation), since it has potent beta1 activity it will increase PULSE PRESSURE, difference between systolic and diastolic,
36. Sleeping beta2 camp counselor: beta2 agonists relax uterine smooth muscle tone
37. **"Do not disturb" TERButaline prevents premature labor (beta2 relaxes the uterus)**
38. **"I DREAM of band camp": ritoDRINE prevents premature labor (beta2 relaxes the uterus)**





2.2 Indirect Sympathomimetic: Catecholamine catch and release

1. Indirect view of sympathetic mime: indirect sympathomimetic
2. Catfish: catecholamine's (epinephrine, norepinephrine, dopamine) sympathomimetic will increase the activity of these substances
3. Dock: adrenergic nerve terminal (site of action of indirect sympathomimetics)
4. Retrieving TIRE: tyrosine (the amino acid precursor to catecholamine's) is transported to the nerve terminal
5. L-shaped rope handle: tyrosine is converted to L-DOPA
6. Dope rope: L-DOPA is converted to Dopamine
7. Camp counselor Mitch yelling "My TIRE!": metyrosine (a tyrosine analog) prevents conversion of tyrosine to L-DOPA
8. Sea Vessel: vesicle containing neurotransmitters in the presynaptic neuron
9. North-facing compass on sea vessel: dopamine is converted to norepinephrine in the vesicle, by using dopamine beta hydroxylase.
10. Hauled in catfish NET: norepinephrine transporter (NET) transports norepinephrine (and dopamine) back into the presynaptic neuron
11. NET DAT catfish: dopamine transporter (DAT) transports dopamine back to the presynaptic neuron, NET and DAT are targets for many antidepressant drugs and also cocaine
12. Hot cocoa: Cocaine
13. Hot cocoa scout ignoring catfish net: cocaine inhibits the norepinephrine transporter (NET), Peripheral NET inhibition leads to sympathetic stimulation which can manifest as hypertension, tachycardia, and mydriases. Central dopamine transporter (DAT) inhibition leads to increasing concentrations in the CNS contributing to arousal, addiction, and the development of seizures.
14. Stimulated hot cocoa scout: cocaine can cause agitation, mydriasis, hypertension and tachycardia.
15. Bloody nose: cocaine can cause nasal mucosal atrophy or septal perforation due to vasoconstriction
16. Constricted red crown: cocaine can cause coronary vasospasm and myocardial ischemia
17. Constricted net on anvil: cocaine induced coronary vasospasm can cause angina, look at the tethers that simulate tight constricted arteries.
18. High pressure blocked bugle: beta blockers can cause sever hypertension in cocaine intoxication (unopposed alpha 1 stimulation)
19. **Atom next to empty net: Atomoxetine (NET inhibitor)**
20. Scout distracted watching HD TV: atomoxetine treats attention deficit and hyperactive disorder (ADHD)
21. "V"mat: vesicular monoamine transporter (VMAT)
22. Catfish transported to sea vessel: catecholamine's are transported by VMAT into presynaptic vesicle
23. **Serpent blocking V mat: reserpine and tetrabenazine inhibits VMAT, depleting neurotransmitter stores, SE: DEPRESSION**
24. A FRIEND of MINE releasing catfish: amphetamines displace catecholamine's (Norepi, dopamine) into synapse
25. Distracted by HDTV while catfish are released: amphetamines can be used to treat ADHD
26. **Friend Date on HDTV: methylphenidate (an amphetamine derivative) treats ADHD**
27. **Sleeping scout hitting "sleep mode": modanifil is a stimulant used to treat narcolepsy**
28. Untouched dinner: stimulants (amphetamines, methylphenidate, modafinil) suppress appetite
29. Dope Rope **Swi**ng: D1 and D2 are coupled to Gs and Gi respectively. At low doses dopamine stimulates D1 receptors in the renal vasculature thereby increasing renal blood flow, GFR, and sodium excretion.
30. **Single rope swing: D1 receptor**
31. Low kidney tied to single rope: low doses of dopamine act on D1 receptors to increase RBF
32. Beta Bugler in the middle: medium doses of dopamine activate beta1 receptors (cardiac activation)
33. Alpha1 scout w/ single candle up high: high doses of dopamine activate alpha1 receptors (pressor effects)
34. This is why it can be used as a pressor in heart failure or in shock that has failed treatment with norepinephrine
35. **Double rope swing: D2 receptor**
36. Brain helmet on double rope swing: D2 receptors are found in the CNS





2.3 – Alpha Drugs

1. **Raul with the "law weapon Claw": Clonidine (alpha-2 agonist)**
2. 2 lit alpha candles: alpa-2 receptor agonist
3. Brain –shaped platform: alpha-2 agonists affect the CNS (inhibition of sympathetic tone → reducing blood pressure)
4. Crossed out "sympathy": alpha2 agonists (clonidine) are sympatholytic in txt of HTN
5. High pressure pipes: clonidine treats HTN (reduced sympathetic tone) reducing CO
6. Urgent pressure: clonidine is useful in HTN urgency
7. Distracting mirror: clonidine can be used to treat ADHD
8. Tourette's marionette: alpha2 agonists(clonidine) are useful in the management of Tourette's syndrome
9. **Alpha-shaped rope: alpha methyldopa (alpha2 agonist) methylRopa**
10. 2 lit alpha candles: alpha 2 receptor agonists
11. Brain shaped platform: alpha 2 agonists affect the cns (inhibition of sympathetic tone → reduced BP)
12. High pressure pipes: Alpha methyldopa treats HTN
13. Pregnant: alpha methyldopa is primarily used to treat gestational HTN
14. Lupus wolf: alpha methyldopa can cause a lupus like syndrome
15. **To X-tine: tizanidine (alpha-2 agonist)**
16. 2 alpha candles next to chailr: alpha 2 receptor agonist
17. Relaxing chair: tizanidine (alpha 2 agonist) is a central acting muscle relaxant
18. Extinguished candles: antagonists
19. **Phantom: phentolamine (reversible alpha-1 and alpha-2 receptor antagonist**
20. Extinguished single and double alpha candles: alpha 1 and alpha 2 receptor antagonist
21. Dilated sleeves: phentolamine causes vasodilation (alpha 1 antagonist effect)
22. **Irreversible phoenix tattoo: phenosybenzamine (irreversible alpha 1 and alpha 2 receptor antagonist)**
23.
24. Hot Cocoa: alpha antagonists (phentolamine) can be used to treat cocaine toxicity (avoid beta blockers due to unopposed alpha vasoconstriction
25. Wine and aged cheese contain the sympathomimetic tyramine (metabolized by MOA-A)
26. Mousetrap protecting wine and cheese: MAO inhibitors can prevent the metabolism of tyramine → HTN crisis (treat with alpha blockers, phentolamine)
27. Frozen colorful dessert: pheochromocytoma (catchecholamine secreting tumor of the adrenal medulla)
28. Brain Freeze: catecholamine excess in pheochromocytoma causes headaches, hypertension, palpitation, sweating, use alpha blockers (phentolamine) preoperatively and interoperatively to control blood pressure, Phenoxynenzamine will be given days in advance
29. Tilt table: alpha receptor antagonism can cause orthostatic hypotension
30. Heart reflex reflex hammer: alpha blocker induced hypotension causes reflex tachycardia
31. **Opera singer: "osin" suffix of alpha 1 selective antagonists (prazosin, terazosin, doxazosin, tamsulosin)**
32. Extinguished single alpha candle: alpha 1 receptor antagonist
33. Banister compressing prostate: alpha 1 antagonists (terazosin) treat BPH (relax smooth muscle in the urethra and prostate)
34. Dilated sleeves: alpha 1 antagonists "-osins" cause vasodilation
35. Praying opera singer: Prazosin (alpha 1 antagonist)
36. PTSD dog tags: prazosin can be used to treat PTSD
37. Tilt Table: increased risk of orthostatic hypotension
38. **Mirth and misery: mirtazapine (atypical antidepressant with antagonist effects at alpha-2 and other receptors)**
39. 2 extinguished alpha candles: alpha 2 antagonist
40. Happy face/ frowning mask: mirtazpine enhances serotonin release and treats depression



2.4 Beta Blockers

1. Muted Beta 1 bugle and beta 2 tuba: beta adrenergic receptor antagonists (beta blockers)
2. Brahm's LOLlaby: "-LOL" suffix of beta blockers (propranolol, metoprolol, atenolol.
3. Weak Arm: beta blockers decrease cardiac contractility (by antagonizing effects on beta 1 receptors throughout the myocardium)
4. Music notes: beta blockers suppress at the SA and AV nodes of the heart
5. Low dangling heart watch: inhibition of SA node activity can cause bradycardia
6. Remain un-Blocked – Beta blockers can cause or exacerbate heart block (due to excessive suppression of AV node conduction)
7. Angina anvil: beta blockers are useful in the management of chronic stable angina by slowing the heart rate increasing diastolic filling and then increasing contractility decreasing cardiac oxygen consumption
8. Discarded oxygen line: beta blockers treat angina by reducing myocardial oxygen demand
9. **A-BEAM spotlight on beta 1 bugler: beta 1 selective antagonists (atenolol, betaxolol, esmolol, acebutolol, metoprolol)**
10. A-BEAM spotlight on heart: the beta 1 selective antagonists primarily suppress adrenergic stimulation of the heart (cardioselective)
11. Broken heart strings under A-BEAM spotlight: cardioselective beta blockers are useful in the acute treatment of MI and other acute coronary syndromes (ACS)
12. Failing heart balloon in the A-BEAM spotlight: cardioselective beta blockers are useful in the management of chronic heart failure to reduce excessive tachycardia and high catecholamine levels on the heart
13. **CARVED candleholder next to failing heart: carvedilol (in addition to cardioselective beta blockers) is useful in the management of chronic heart failure.**
14. Extinguished alpha candle on CARVED candleholder: carvedilol is a nonselective beta blocker and alpha 1 blocker
15. Angel: beta blockers reduce mortality in chronic heart failure and post-MI
16. Remodeling: beta blockers reduce cardiac remodeling by protecting the heart from excess circulating catecholamine's
17. High pressure pipes: beta blockers are useful in the treatment of HTN (especially in patients post MI)
18. Closed rain umbrella with blocked beta 1 bugle: beta blockers inhibit production of renin (antagonize beta 1 receptors at the JGA)
19. **Alpha and beta organ stops with extinguished alpha candle: Labetalol is a nonselective beta blocker and alpha 1 blocker**
20. Dilated sleeves: labetalol antagonizes alpha 1 receptors leading to peripheral dilation
21. Pregnant organist: labetalol treats HTN in pregnancy
22. Emergency stop: labetalol is useful intravenously for hypertensive emergency (due to combined alpha and beta effects)
23. Ivy: Used intravenously
24. Dissected organ pipe with IVY: IV beta blockers are useful in acute aortic dissection
25. Big obstructed heart bag: beta blockers are useful in the management of hypertrophic obstructive cardiomyopathy
26. Ponding head bell: beta blockers can be used for migraine prophylaxis for episodic migraines
27. Big stormy bowtie: beta blockers are useful for the sympathomimetic treatment of thyroid storm (blocks catecholamine surge) treat with 3 p's propranolol, prednisone, and propothyrouracil
28. Shaking Baton: beta blockers treat essential tremor
29. Rhythm inducing record: beta blockers have antiarrhythmic properties
30. Wheezing beta 2 tuba player: nonselective beta blockers can exacerbate asthma and COPD (antagonize beta 2 mediated bronchodilation)
31. Draining the muted beta 2 tuba: topical nonselective beta blockers (timolol) treat glaucoma (antagonize beta 2 receptors on the ciliary epithelium → decreasing aqueous humor production)
32. Droopy Tromboner: beta blockers can cause impotence in men
33. Antagonizing plastic bugle: acebutolol (a selective beta 1 antagonist with partial agonist activity)
34. Agonizing pin: pindolol (a nonselective beta blocker with partial agonist activity)
35. Young: not full agonists
36. Popping failing heart: beta blocker with partial agonist activity (pindolol, acebutolol) should be avoided in patients with heart failure or a history of MI)
37. Glucagon packets: glucagon treats beta blocker toxicity (stimulates heart via glucagon receptors)

Remember that propanolol can mask hypoglycemia



Digoxin, milirinone, nesiritide

1. DJ Foxglove: Digoxin – Derived from the foxglove plant
2. Knocked over banana vending machine: inhibition NA+/K+ ATPase
3. Obstruction salty sodium peanuts: increased intracellular sodium as a result of Na+/K+ ATPase inhibition
4. Salty peanuts sneaking in the calci-yum ice cream: increased intracellular sodium promotes calcium influx at the NA+/Ca2+ exchanger
5. Flexed arm: increased cardiac contractility due the the positive ionotropic effects
6. Deflated heart balloon: symptomatic treatment of chronic systolic heart failure. Only used for symptomatic relief, does not decrease mortality
7. Las Vegas: direct stimulation of the vagus nerve allows for treatment of Atrial arrhythmias
8. Rhythm-inducing record: antiarrhythmics
9. Patients presenting will have HF and A.Fib, labs show elevated in K+

Adverse effects

10. Pile of bananas: Hyperkalemia with acute digoxin toxicity
11. Various dances on the heart shaped dance floor: digoxin may induce various arrhythmias
12. TaSTy scoop: chronic digoxin use may cause scooped concave ST segments on EKG
13. SA music note: side effect of bradycardia due to parasympathetic activity of SA node
14. Dangling heart watch: side effect of bradycardia
15. Av MUSIC NOTE: SIDE EFFECT OF HEART BLOCk DUE TO DIGOXIN TOXICITY
16. Remain Unblocked: Digoxin is contraindicated in SA node heart block, or in use with caution in Beta Blockers
17. GI side effects include nausea, vomiting ,and abdominal pain
18. Yellow spotlight: side effect of Xanthopia (objects appear yellow)
19. Kid stuffed inside banana depleted vending machine: Hypokalemia will exacerbate digoxin toxicity
20. Loop diuretics can cause hypokalemia, along with diarrhea or vomiting may also occur
21. Kidney jukebox with long tapering flag on cracked kidney: Renal insufficiency can make digoxin toxicity worse and will precipitate digoxin rise, the long flag indicates the long ½ life of digoxin, and increasing susceptibility to toxicity
22. Records in kidney jukebox: many arrhythmics inhibit renal clearance of digoxin, increasing susceptibility to toxicity
23. Fabulous: digoxin immune fab is used to reverse toxicity

24. One in a million: Milrinone

25. Don't phoster disinterest: milrinone inhibits phosphodiesterase
26. CAMPaign: milirinone decreases CAMP breakdown
27. Flexing arms: milrinone increases cardiac contractility
28. Dilated red donkey ears: milirinon causes arteriolar dilation in HF, but watch for hypotension

29. Turn the tide: nesiritide

30. BuMP: BNP analog that increases cGMP
31. Dilated red ears and blue legs: nesiritide causes arteriolar and venous dilation, reducing afterload and preload
32. Salty peanut stream: nesiritide causes natuiresis



ACE inhibitors, ARB's, Aliskiren

1. Rain umbrella: Renin
2. JGA: is the site of synthesis, storage, and release of Renin by direct sympathetic beta 1 receptors, or decrease in serum Na+, or dec GFR
3. Loose red tie guy circulating from machine to machine: angiotensinogen is cleaved by renin
4. Tense red tie: renin converts angiotensinogen into angiotensin I
5. Lung Vest: ACE is located in the vascular endothelium of the lungs
6. Two tense red suspenders with the wining ACE: angiotensin II is converted from angiotensin I by ACE in the lungs
7. Tense red suspenders: Angiotensin II causes vasoconstriction.
8. Grounds filtration rate increased: increased angiotensin II increases GFR
9. Pinched efferent end of straw: angiotensin II constricts the efferent arteriole
10. When GFR plummets ATII preserves GFR
11. Salty sodium peanuts at the pro cart track: angiotensin II acts at the proximal tubule to increase sodium absorption
12. Suspenders at the mineral bar: ATII increases aldosterone release from the adrenal cortex,
13. Banana peels at the mineral Bar: the mineralocorticoid aldosterone acts on the collecting ducts to increase Na+ and fluid retention at the expense of K+
14. **Ace on table: ACE inhibitors**
15. APRIL showers: -pril suffix common to all ACE inhibitors
16. Suspenders with the losing hand: ACE inhibitors prevent ATI to ATII
17. Floppy Red suspenders: ACE inhib counteract the presser effects of ATII
18. Ace inhibitors and arbs decrease GFR, dilate the efferent arteriole, decrease sodium-bicarb reabsorption in the PTC, and decrease aldosterone release
19. Credit card: ACE inhibitors can cause an expected bump in creatinine
20. Fainting: ACE inhibitors can cause significant hypotension and syncope in patients with high renin levels (in heart failure)
21. Cheering single tense neck tie: ACE inhibitors increase levels of ATI and renin
22. Raised banana daiquiri: ACE inhibitors can cause hyperkalemia due to decreased aldosterone levels
23. Failing heart balloon: ACE inhibitors are first line agents for the treatment of chronic heart failure
24. Angel: Ace inhibitors reduce mortality in heart failure and MI
25. Remodeling: ACE inhibitors decrease ATII mediated cardiac remodeling
26. Broken heart strings: ACE inhibitors are used in myocardial infarction
27. High pressure pipes: ACE inhibitors are the first line agents used for HTN
28. Candy shop: ACE inhibitors slow the progression of diabetic nephropathy
29. Album: patients with albuminuria and blood pressure greater than 130/80 are started on and ACE inhibitor
30. **Adverse effects**
31. Coughing dealer: ACE inhibitors can cause a dry cough due to an increase of bradykinin
32. Braids: ACE inhibitors can increased bradykinins and substance P causing lung irritation and inflammation
33. "C" shaped ring on fat lip: ACE inhibitors are contraindicated in hereditary angioedema (due to C1 esterase deficiency)
34. Tarantula: ACE increases the risk of fetal hypotension
35. Fire extinguisher in cracked kidney glass: co-administration of ACE inhibitors with NSAIDS can precipitate acute kidney injury due to afferent renal constriction leading to decreased GFR
36. Contraindicated kidney purse straps: ACE inhibitors are contraindicated in bilateral renal artery stenosis because the ATII needs to vasoconstriction
37. Credit card: ACE inhibitors can precipitate acute renal failure in bilateral renal artery stenosis indicated by a persistent increase in creatinine
38. **SoRry Taken: -sartan suffix common to all ARB's (angiotensin receptor blocker)**
39. Braids: ACE inhibitors can increase bradykinins, this can be avoided by using ARB's
40. Raised banana daiquiri: ARB's can increase K+ retention causing hyperkalemia due to decreased aldosterone levels
41. **High Risk: aloskerin – a direct renin inhibitor**
42. Losing neck tie gambler: aliskaren prevents renin from being released preventing ATI from being converted to ATII
43. Bananas: aliskiren can increase K+ retention causing hyperkalemia due to decreased aldosterone levels



Acetazolamide, Mannitol

1. WHERE EVER SODIUM GOES, WATER WILL FOLLOW
2. Pro cart track: proximal convoluted tubule
3. Proximal convoluted tubule: site of action of acetazolamide and mannitol; sodium, Cl-, K+, glucose and amino acids will be absorbed here. Bicarb 85% is reabsorbed here
4. Banana vending machines: Na+/K+ ATPase on the basolateral membrane
5. Three P batteries: ATPase
6. Yellow track: lumen of tubule
7. Grey track: intracellular compartment
8. Wall is the basolateral membrane
9. Track worker distributing peanuts inside and letting H+ helmets out. Na+/H+ exchanger located on the apical membrane
10. biCARb race car: Bicarb in the lumen in the PCT
11. Rider with H+ helmet sitting in biCARb secreted H+ combines with the bicarb in the tubular lumen to form carbonic acid H2CO3
12. Car battery anhydrase on the inside track: lumen carbonic anhydrase (CA)
13. Battery powered car producing H2O and CO2 exhaust: Luminal CA converts carbonic acid to H2O and CO2
14. H2O and CO2 exhaust on the outside track: H2O and CO2 enters the intracellular space via diffusion
15. Water is sprayed over the wall: water is reabsorbed with solutes at the PCT (High Permeability)
16. Car battery anhydrase on the outside track: intracellular CA converts H2O and CO2 back into carbonic acid (H2CO3)
17. H+ helmet leaving the biCARb: intracellular carbonic acid disassociated back into H+ and Bicarb
18. Recycled H+ helmet: H+ transported back into the lumen by the Na+/H+ exchanger
19. biCARb taken away: intracellular bicarb is absorbed vis basolateral transporter
20. Battery acid breaking car battery: Acetazolamide inhibits carbonic anhydrase (preventing reabsorption of bicarb)
21. Spilled alkaline substance on inside track: CA inhibitors (acetazolamide) cause bicarb to stay in the tubular lumen leading to urine alkalization
22. Dropping salty peanuts on the inside of track: CA inhibitors prevent the reabsorption of sodium (with bicarb) causing naturiesis
23. biCARb taken away: CA inhibitors cause excretion of bicarb
24. Close the gap #2!: CA inhibitors cause a normal anion gap metabolic acidosis leading to a hyperchloremic state
25. Spilled eyeball cups: CA inhibitors (acetazolamide) decreased production of aqueous humor (useful in the management of glaucoma) very common to be used
26. High pressure head balloon: CA inhibitors decrease production of CSF (useful in the management of idiopathic intracranial HTN, pseudo tumor cerebri)
27. High elevation: CA inhibitors are useful in the treatment and prevention of mountain sickness, allowing the increasing ventilation decreasing hypoxia
28. Buildup of bicarb in the tubule will increase the pH of the urine, leading to prevention of uric acid kidney stone, promoting ca++ ston
29. Banana peel: CA inhibitors can cause hypokalemia (potassium wasting)
30. Two tubes of acid: CA inhibitors cause a type 2 renal tubular acidosis (defect in proximal bicarb reabsorption)
31. Rocks on the inside track: CA inhibitors promote the formation for calcium phosphate stones (insoluble at high pH)
32. Rotten sulfur eggs: CA inhibitors are sulfa drugs
33. **Tall Man: mannitol** (osmotic diuretic) acts at the PCT and descending limb of the loop of Henle, pulls water out to be excreted
34. High pressure head balloon: mannitol draws free water out of the CNS (useful in the treatment of elevated intracranial pressure) can be used urgently
35. Spilled eyeball cups: Draws free water out of the eye, (decreases intraocular pressure)
36. Tall man causing wet lungs: mannitol induced expanded extracellular volume can cause pulmonary edema and hyponatremia
37. Tall man dousing failing heart balloon: mannitol induced expanded extracellular volume can exacerbate heart failure.
38. Elevated salty peanuts: mannitol induced water depletion can cause hypernatremia
39. Spilled salty peanuts: mannitol induced expanded extracellular volume can cause hyponatremia



Loop Diuretics

1. Loop de Loop of Henle: Loop of Henle
2. Thick ascending Limb of the loop of Henle: site of action of most loop diuretics. Most relevant is sodium chloride blocks
3. Banana vending machine: Na+/K+ ATPase on the basolateral membrane, that will pump sodium into the interstitium
4. Three P batteries: ATPase
5. Yellow track: lumen of the renal tubule
6. Platform: intracellular compartment
7. Background wall is the interstitium
8. Track worker taking peanuts, bananas, and 2 chloride packets: Na+/K+/2Cl cotransporter (NKCC) reabsorbs these ions at the luminal membrane of the TAL thick ascending limb
9. Water secured in car: the TAL is impermeable to water (diluting segment)
10. **Furious kid: furosemide (loop diuretics)**

common interaction with Dig ⇒ yellow vision (any K wasting)

11. Furious kid clinging to food: furosemide selectively blocks the NKCC transporter on the luminal membrane of the TAL, keeping sodium in the lumen in the tubule representing furosemides ability to reduce reabsorption of NaCL causing naturesis.
12. Loop diuretics are the most efficacious currently
13. **Ethics: ethacrynic acid (loop diuretic)**
14. Furious kid clinging to magnets and calci-yum ice cream: by blocking the NKCC, Loop diuretics reduce the lumen positive potential, promoting the excretion of Mg2+ and Ca2+
15. Falling magnets: prolonged use of loop diuretics can cause hypomagenesmia, especially in diet deficient patients
16. Falling calci-yum ice cream: Loop diuretics can cause hypocalcemia (rare)
17. **Pro-slugger: prostaglandins**
18. Furious kid wielding pro-slugger: loop diuretics induce the expression of COX-2, synthesizing prostaglandins that enhance salt excretion and dilate the afferent arteriole
19. Kid opening a path to afferent line of coaster: Prostaglandins will increase RBF in the afferent arteriole of the glomerulus. Thus enhancing diuretic action
20. Fire extinguisher inhibiting the pro-slugger: NSAIDs decrease prostaglandin synthesis, interfering with the actions of loop diuretics
21. Failing heart balloon: loop diuretics are 1st line for the symptomatic treatment of acute decompensated heart failure with fluid overload, reduction for peripheral or pulmonary edema
22. Wet lungs: Loop diuretics cause maximal amount of diuresis in the shortest amount of time. Used 1st line in acute heart failure with orthopnea that has crackles in the lungs and JVD. Loops will help with PRELOAD function. This will not help prolong the life of the heart.
23. Yellow inner tube: loop diuretics treat ascites in liver failure
24. High pressure pipes: loop diuretics can be useful in the treatment of HTN
25. Diuretics lower blood pressure by decreasing body sodium stores
26. Banana peel: loop diuretics are potassium wasting causing hypokalemia, hypokalemia can exacerbate any underlying arrhythmias in heart failure
27. Loud gong: loop diuretics can cause dose related hearing loss
28. Stinky sulfur eggs: most loop diuretics are sulfur drugs
29. Sulfa-less ethics: Ethacrynic acid is not a sulfa drug
30. Kidney filled with blue tickets: Interstitial nephritis can be caused by loop diuretics
31. Knitting needles: loop diuretics can cause hyperuricemia, may lead to gouty arthritis
32. Park employee cleaning the floor with contracted bleach bottle: loop diuretics can cause contraction alkalosis, causing dehydration and metabolic alkalosis by many mechanisms.



Thiazides - Distal Convoluted Tube-Slide

1. Distal convoluted tube slide: Distal convoluted tubule
2. Distal convoluted tubule: site of action for thiazide diuretics
3. Banana vending machine: Na+/K+ ATPase on the basolateral membrane
4. Three P batteries: ATPase
5. Yellow tube slide: tubular lumen
6. Area outside slide: intracellular compartment
7. Sodium chloride salt scraper: NaCl cotransporter reabsorbs these ion at the apical membrane of the DCT
8. Active slider dropping the calci-yum ice cream: calcium is actively reabsorbed at the DCT (regulated by PTH)
9. **Chloro-thighs, thiodore Roosevelt on high dive: Hydrochloriathiazide and chlorothalidone (thiazide diuretics)**
10. Sodium chloride dumping into pool: thiazides inhibit NaCl reabsorption by blocking the NaCl cotransporter on the apical membrane (causing natiuresis)
11. Chloro-thighs kid dropping calci-yum: thiazide diuretic enhance calcium reabsorption, may be result at proximal and distal tubule. At the proximal tubule thiazide induced volume depletion leads to enhanced sodium and passive calcium reabsorption. At the distal tubule thiazides block sodium entry into the epithelial cell. This decrease of sodium entry enhances sodium calcium exchange at the basolateral membrane leading to the enhanced absorption of calcium
12. High pressure pipes: thiazide diuretics are one of the first line treatments for mild or moderate HTN
13. Loop diuretics are first line for acute, not thiazide
14. Floppy failing heart balloon: use of thiazides can be useful in the symptomatic treatment of heart fauilure (loop diuretics are first line)
15. Insipidus fountain: thiazide diuretics treat nephrogenic diabetes insipidus, thiazide diuretics can reduce polyuria and polydipsia in nephrogenic DI, and this paradoxical association is due to a hypovolemia induced increase in Na and H2O reabsorption in more proximal segments of the nephron where ADH is not working in the distal tubule. Thus allowing for more electrolytes to be retained.
16. Removing tube slide stones: thiazide diuretics can be used to prevent calcium stones (increased calcium reabsorption causes hypocalciurea) found in hyperparathyroidism, sarcoidosis,
17. New calcium chalk: thiazide diuretics may benefit patients with osteoporosis
18. Elevated calci-yum ice cream: thiazide diuretics can cause hypercalcemia
19. Elevated Candy jar and stick of butter: Thiazide diuretics can promote Hyperglycemia and also hyperlipidemia.
20. HIGHdroclorothiazide and the HIGH dive raises a lot of lab values
21. Yellow knitting needles: thiazide diuretic can cause hyperuricemia (can precipitate gout) due to hypovolemia and hyper absorption of urea
22. "Lift"ium balloons: thiazide diuretics decrease the amount of lithium cleared, therefore there will be increased serum lithium levels
23. Grey kid pissing in the pool: Lithium is a common cause of nephrogenic diabetes insipidus
24. Potassium depleted banana peel: Thiazide diuretics block the Na+/Cl+ cotransporter in the distal convoluted tubule, increasing sodium delivery to the collecting duct. This leads to increasing potassium secretion by the collecting duct in exchange for Na+ reabsorption leading to hypokalemia
25. Spilled peanut shells: thiazides diuretics can cause hyponatremia
26. Rotten eggs being tossed: Thiazides are sulfa drugs
27. Contracted bleach bottle: thiazides can cause contraction alkalosis, metabolic acidosis by hypovolemia induced renin production by the kidneys. Increasing aldosterone which causes increased H+ excretion at the collecting duct and more ATII leading to increased sodium bicarb reabsorption at the proximal convoluted tubule

Will increase aldosterone

Can lead to gout



K+ sparing Diuretics – Pt 1

1. Central gutter: work in the collecting duct
2. Collecting duct (site of action of the K+ sparing diuretics)
3. Mineral-O-Food court: mineralocorticoids site of action (aldosterone) in the collecting duct
4. Principal court: principle cell of the collecting duct (major site of Na+/K+/H2O transport
5. Banana vending machine: Na+/K+ ATPases on the basolateral membrane, help pump reabsorbed sodium into interstitium
6. Three P batteries: ATPase
7. Food court ground: intracellular compartment
8. Salt-E sNaC cart: epithelial Na+ channels (ENaC) reabsorb Na+ across the luminal membrane of the collecting duct and distribute to the interstitium
9. Water in gutter: tubular lumen
10. Banana stand dumping bananas: K+ channels allow the excretion of K+ across the luminal membrane of the collecting duct
11. Salt-E sNaC care toppling banana stand: reabsorption of Na+ creates a negative luminal potential that facilitates K+ excretion, this is due to the negative electrical potential caused by the absorption of sodium into the interstitium that will draw the potassium into the tubular lumen
12. Alpha intercontinental food truck: alpha intercalated cell of the collecting duct (major site of H+ excretion)
13. Batter powered acid pump: H+ATPase on the apical membrane of the alpha intercalated pumps H+ into the lumen
14. Three P batteries: ATPase
15. Mineral court services: intracellular mineralcorticoids (aldosterone) receptor
16. Mineral key: aldosterone binds to the salt-E sNaCk upregulating ENaCs on the apical membrane, increasing Na+ reabsorption
17. Mineral Key activating the banana vending machine: aldosterone upregulates Na+/K+ ATPse on the basolateral membrane
18. Mineral key activating the banana stand: aldosterone upregulates K+ channels on the apical membrane, increasing K+ excretion
19. Loops and thiazides activate renin (and aldosterone) due to hypovolemia and cause a hypokalemia because they leave all of the sodium in the tubular lumen until it gets to the collecting duct. Then there is an attempt by the ENAC to retain all of the sodium at the expense of potassium, and facilitate H+ secretion causing a metabolic alkalosis.
20. **Tangerines: triamterene (K+ sparing diuretic)**
21. Tangerines blocking the salt-E sNaCk cart: triamterene inhibits Na+ reabsorption through ENAC
22. **Almonds: amiloride (K+ sparing diuretic)**
23. Almonds blocking the Salt-E sNaC cart: amiloride inhibits Na+ reabsorption through ENaC
24. Salty sodium peanuts falling into the duct: K+ sparing diuretics inhibit Na+ reabsorption at the collecting duct, promoting natiuresis
25. **Apple with the teacher: eplerenone (K+ sparing diuretic)**
26. Teacher with apple antagonizing the mineral court services man: eplerenone antagonizes the mineralocorticoid receptor
27. **Health inspector with Spiral bound notebook: spironolactone (a K+ sparing diuretic)**
28. Health inspector antagonizing the mineral court services man: spironolactone antagonizes the mineral corticoid receptor
29. Crumbling mineral mountain: K+ diuretics (spironolactone, eplerenone) are useful in the treatment of 1 and 2 hyperaldosteronism, conn syndrome, ACTH etc…
30. Failing heart balloon: K+ diuretics (spironolactone, eplerenone) are useful in the treatment of heart failure to prevent K+ wasting
31. Remodeling: mineralocorticoid antagonists (spironolactone, eplerenone) prevent myocardial remodeling induced by high level of aldosterone
32. Angel: mineralocorticoid antagonists decrease mortality in heart failure
33. Insipidus fountain: amiloride is useful in the treatment of Li+ induced nephrogenic diabetes insipidus, this will block lithium entry into collecting duct cells increasing clearance of lithium

17-fryer… can lead to gynocomastia



K+ Sparing Diuretics - CONT

34. Little gnome blocked by almonds and tangerines: amiloride and triamterene are useful in the treatment of Liddles syndrome (overactive ENaCs)
35. Elevated banana's: K+ sparing diuretics can cause mild or even dangerous hyperkalemia, seen in renal disease when there is a decreased excretion of potassium and with drugs that decrease renin and angiotensin activity such as Beta blockers and ACE inhibitors. Use a potassium wasting diuretic with these pts
36. Acid spill: K+ sparing diuretics cause a normal anion gam metabolic acidosis (by decreasing the function of the H+ATPase) by inhibition of aldosterone's effects at the collecting duct
37. Worker holding 4 acid tubes: K+ sparing diuretics inhibit the effects of aldosterone in the collecting duct causing a type 4 renal tubular acidosis
38. Big K: type 4 RTA is associated with hyperkalemia: this is the only one associated with hyperkalemia.
39. Spironolactone is much less selective with the aldosterone receptor, spironolactone is a synthetic steroid that can bind to other steroid receptors and processing enzymes. This has anti androgenic side effects and can block testosterone synthesis.
40. Fried male symbol: testosterone produced from cholesterol
41. Health inspector inhibiting 17 aplha "fry"droxylase: spironolactone inhibits 17alpha-hydroxylase. Important in the adrenal cortex and testes
42. Bubbling ovary shaped vats: spironolactone treats the symptoms of androgen excess in polycystic ovarian syndrome, used after a trial of birth control
43. Bushy beard: symptoms of androgen excess (hirsutism) in PCOS are treated with spironolactone
44. Preventing boy from receiving onion ring: spironolactone directly antagonizes the androgen receptor
45. Lids on chest: Gynecomastia caused by spironolactone
46. Droopy churro: Spironolactone can cause impotence and decreased libido



Calcium Channel Blockers

1. L-Shaped handle: calcium channel blockers target voltage gated L Type calcium channels specifically
2. Smooth muscle tile: Dihydropyridines block L-Type calcium channels in smooth muscle
3. Cardiac muscle tile: non-dihydropyridines block L-Type calcium channels in cardiac muscle
4. **Dairy: dihydropyridines**
5. **Non-dairy: non dihydropyridines**
6. Dilated dairy nozzle: dihydripyridines cause vasodilation
7. Dippin station: -dipine suffix of dihydropyridines (nifedipine, amlodipine, nicardipine)
8. **Very vanilla: verapamil (a non dihydropyridine)**
9. Small sized nozzle: Verapimil has very minimal dilatory activity
10. **Delicious dark chocolate: diltiazem (a non-dihydropyridine)**
11. Medium sized muscle: Diltiazem has some vasodilatory activity
12. Weak kid at the non-dairy: non-dihydropyridines decrease cardiac contractility
13. Music notes on non-dairy sign: non-dihydropyridines decrease activity at the SA and AV nodes
14. Low dangling heart pocket watch: Bradycardia with SA node inhibition
15. High pressure pipes: CCB's treat hypertension
16. Emergency shut off: an IV dihydropyridine (clevidipine, nicardipine) can treat hypertensive emergency
17. **Large knife: nifedipine (a dihydropyridine)**
18. Pregnant knife lady: nifedipine is used to treat hypertension in pregnancy or post-partum
19. Angina anvil: CCB's treat stable angina
20. Dilated coronary crown: dihydropyridines vasodilate coronary arteries. Reduce coronary resistance, increase coronary blood flow and may enhance development of collaterals
21. Reduced anvil load: dihydropyridines reduce afterload by causing increased peripheral vasodilation. Reducing myocardial oxygen demand
22. Discaarded oxygen line: non-dihydropyradines decrease myocardial oxygen demand by acting as a negative ionotrope and chronotrope and by lowering systemic blood pressure
23. Anvil medal: CCB's treat prinzmetal angina, varying form of angina attributed to vasocoronary spasm. Episodes are predominantly at rest and occur at night.
24. Blue fingertips: dihydropyridines treat raynaud's syndrome, "an exaggerated response to cold temperature or stress" nifedipine and amlodipine can treat
25. Brain shaped ice cream with berries: Dihydropyridines can be used to treat subarachnoid hemorrhages commonly associated with berry aneurysms. May have a history of polycystic kidney disease
26. Need Mo'dippin with berry brain ice cream: nimodipine prevents vasospasms after a subarachnoid hemorrhage, vasodilates cerebral vessels
27. Pounding head bell: migraine prophylaxis with verapamil
28. Jukebox: Non-dihydropyridines have antiarrhythmic properties, this will help with A.Fib and A.Flutter
29. Adverse effects
30. Lightheaded patron: Dihydropyridines can cause lightheadedness, Headache, flushing,
31. Baggy pants: peripheral edema from dihydropyridines due to preferential dilation from precapillary vessels from the arterioles increased capillary hydrostatic pressure
32. Heart reflex hammer: dihydropyridines can cause reflex tachycardia, especially with nifedopine
33. Knife cutting heart: Short acting nifedipine has a high chance of side effects because of how active it is. Nifedipine can exacerbate myocardial ischemia due to reflex tachycardia – avoid in patients with unstable angina or MI
34. Clogged toilet: verapamil can cause constipation
35. Expanding gum: verapamil can cause gingival hypertrophy
36. Remain unblocked: verapamil and diltiazem care relatively contraindicated in patients with heart block
37. Verapamil or diltiazem combined with a beta blockers may produce excessive AV block
38. Failing heart balloon locked out of store: CCB'sc an worsen heart failure due to hypotension, and can increase sympathetic activity



Primary hypertension and Hypertensive emergency

1. High pressure pipes: antihypertensives
2. Primary deck: primary (essential) hypertension treatment
3. Two life preservers if >20 LBS: two antihypertensives for BP >20/10 mmHg above goal
4. Main TXT is thiazide diuretics, Long acting CCB's, ACE inhibitors or ARBS
5. **Chloro-thighs: hydrochlorothiazide is a first line agent for treating primary HTN, chlorthalodone**
6. Elderly black man with Calci-YUM ice cream: Black and elderly patients respond well to a CCB for txt of primary HTN
7. **Dippin' pool: long acting dihydropyridines (-dippin suffix) treat primary HTN**
8. Cloro-thighs: Black and elderly patients respond well to hydrochlorothiazide for treatment of primary HTN
9. **ACE-stealing dealer: ACE inhibitors treat primary HTN**
10. Ace inhibitors are first line treatment for hypertension in patients with heart failure (failing heart balloon), MI (broken heart strings), and diabetes (candy jar)
11. Emergency shut off switch: treatment for hypertensive emergency (blurry vision, lung crackles, headache)
12. 180 protractor over 12 inch ruler: hypertensive emergency (SBP>180 or DBP>120)
13. Hole in the titanic: hypertensive emergency is defined by end organ damage plus elevated BP (SBP>180 or DBP>120)
14. Muted beta bugles: Beta-1 antagonists (esmolol and metropolol) can be used for hypertensive emergencies
15. Ivy: IV beta blockers administration treats hypertensive emergency
16. Alpha and beta organ stops: Labetalol (alpha and beta antagonist) can be used in hypertensive emergency
17. Dilated red smoke stack: many agents used in hypertensive emergencies are potent vasodilators, which may result in a rebound hypotension and tachycardia, and sodium and fluid retention from renin increase
18. Heart shaped reflex hammer and rain umbrella: hypotension leads to reflex tachycardia and increased renin levels
19. Unloaded scale: vasodilation reduces afterload
20. Calci-yum ice cream lady with red floppy sleeves: IV calcium channel blockers (nicardipine, clevidipine) can be used in hypertensive emergency and to vasodilate
21. **Nice card: nicardipine (dihydropyridine CCB)**
22. **Clover Clevitipine (dihydropyridine CCB)**
23. Dilated red sleeves: dihydropine CCB's can cause arteriolar dilation to reduce systemic dilation
24. **Hydro-Boat: hydralazine treats hypertensive emergency**
25. Dilated red hose: hydralazine is a direct arteriolar vasodilator
26. Pregnant woman boarding hydro-boat: hydralazine is safe in pregnancy
27. Fainting: hydralazine can cause hypotension
28. Anvil anchoring hydro boat: hydralazine induced reflex tachycardia can worsen angina
29. Beta-1 bugler leaving to get on hydro boat: administration beta-blocker with hydralazine to prevent reflex tachycardia
30. Muted beta 1 bugler deflecting reflex hammer and rain umbrella: beta blockers minimize the reflexive sympathetic activation
31. Dynamite: nitrate (nitroglycerine)
32. Failing heart balloon: Hydralazine combined with a nitrate (nitroglycerine) treats heart failure, especially in left ventricular systolic dysfunction
33. Guardian angel: hydralazine (arteriolar vasodilator) combined with a nitrate (veinodilator) provides a mortality benefit for certain patients in heart failure
34. Lupus wolf: hydralazine can cause a drug induced lupus syndrome
35. **Nitro-prusside speedboat: nitroprusside can be used in hypertensive emergency**
36. Nitric oxide exhaust: nitroprusside causes vasodilation via nitric oxide
37. Grump: nitric oxide promotes smooth muscle relaxation by increasing cyclic GMP, causing decreased myosin activity and dephosphorylation
38. Sailor with dilated red sleeves and blue pants: nitroprusside causes arteriolar and venous dilation
39. Blue Cyanide exhaust pipe gas: Cyanide poisoning is a side effect of nitroprusside **Old lady Pam: fenoldopam treats hypertensive emergency**
40. Single rope: fenoldopam is a selective dopamine 1 receptor agonist, with no effect on alpha or beta receptors
41. Camping tent: fenoldopam (D1 agonist) increases cAMP, causes vasodilation in most arteriolar beds leading to reduced systemic resistance
42. Dilated red crown: fenoldopam causes coronary vasodilation
43. Rope connected to kidney: fenoldopam dilates renal arteries increasing renal perfusion while lowering blood pressure,
44. Salty peanuts in the water: fenoldopam (D1 Agonist) is a natriuretic, leading to increased Na+ and H20 excretion



Antiarrhythmic Class I A-C (rhythm control): **No (Class I sodium)** Bad Boy (Beta Blockers) Keeps (Potassium) Clean (calcium)

1. Soloist: class I antiarrhythmics
2. Microphone stand Phase 0: of the AP upstroke dictated by Na+
3. Wire off the microphone is Phase 2: plateau dictated by Ca2+
4. Phase 3 downslope: repolarization dictated by K+
5. Soloist holding peanut jar: Class I antiarrhythmic block sodium channels
6. Soloist tipping mic stand: class I antiarrhythmics decrease the slope of phase 0 upstroke (slows conduction of the cardiac AP) AP will almost look tipped over with a decreased slope
7. Inactivating spoon in open peanut butter jar: Class I antiarrhythmics bind to open or inactivated Na+ channels.
8. Heart tipping mic stand: "use dependence" – class I antiarrhythmics have a greater effect on rapidly depolarizing tissues (increased heart rate causes slower phase 0 upstroke)
9. Potassium banana curtain: K+ current present during Phase 2 (plateau) and phase 3 (repolarization) of the cardiac action potential
10. Illuminated atria, ventricles, and His-perkinje system: class I antiarrhythmics affect the Na+ dependent cardiac action potential (no action at the SA and AV nodes)
11. Wide QRS shaped crack: class I antiarrhythmis widen the QRS complex on the ECG (decreased AP conduction velocity) this will happen when the HR increases because that will increase the effect of the drug
12. **Class IA antiarrhythmics: quinidine, procainiminde, dysopyramide "Double, Quarter, Pounder"**
13. **Dining prom queen: quinidine (class IA antiarrhythmic)**
14. **Prom King: procainamide (class IA antiarrhythmic)**
15. "**Disapears!" disopyramide (class IA antiarrhythmic)**
16. Binding strength: IC>IA>IB
17. Prom queen lightly holding peanut butter jar: class IA antiarrhythmics have an intermediate binding affinity to the Na+ channel (intermediate use dependence, moderate slowing of phase 0 upstroke) <u>increased AP duration</u>
18. Pushing away the curtain: class IA antiarrhythmics also block K+ channels prolonging phase 2 and 3 of the cardiac action potential → prolonged refractory period
19. Illuminated top and bottom of IA heart: class IA antiarrhythmics treat supraventricular and ventricular arrhythmias
20. White wolf pack: class IA antiarrhythmics treat WPW syndrome (a type of SVT involving extra signals in a accessory pathway)
21. Tin cans: quinidine toxicity can cause cinchonism (syndrome of tinnitus, headache, dizziness)
22. Broken plates: quinidine can cause thrombocytopenia
23. Prom kings lupus wolf: procainamide can cause a lupus – like syndrome raising an ANA titer
24. Darts in failing heart balloon: dysopyramide can exacerbate heart failure (negative ionotrophy)
25. Twisted torsades streamer: Class IA antiarrhythmics can cause Q-T interval prolongation (Precipitates torsades)
26. Whenever the potassium current is prolonged and thrown aside it can cause torsades de pointes (prolonged QT intervarl)
27. **Class IB antiarrhythmics "Lettuce, Tomato, Mayo"**
28. **Lied: lidocaine (class IB antiarrhythmic)**
29. **Friendly towing: Phenytoin (an anti-epileptic) that shows some type IB properties**
30. **Mexican flag: mexilitine (class IB antiarrhythmic)**
31. Dropped peanut butter jar: Class IB antiarrhythmic have a low binding affinity for the Na+ channel (low use dependence, modest slowing of the phase 0 upstroke) <u>Decreased AP duration</u>
32. Pulling the curtain: class IB antiarrhythmics shorten phase 2 and 3 of the cardiac action potential → shortened refractory period so no chance for torsades de pointes
33. Illuminated and cracked bottom of heart: Class IB antiarrhythmics treat ventricular arrhythmias (especially in ischemic tissues) in sodium channels spending more time in the open and resting state because of the longer action potential
34. Broken illuminated IB heart: has a greater tendency to work with ischemic heart because of the reduced resting membrane potential delays sodium channel transition from inactive back into resting state resulting in increased drug binding
35. "DEAD": class IB antiarrhythmics treat ischemia induced ventricular arrhythmias one of the most common causes of death in the acute period following an MI
36. Brain trucker hat: class IB antiarrhythmics cause neurological problems (parasthesias, tremor, convulsions)





37. **Class IC antiarrhythmics Heart floor: propafenone, flecaoinide "Fries Please"**
38. **Flakes: Flecainide (class IC antiarrhythmic)**
39. **Purple phone: propafenone (class IC antiarrhythmic)**
40. Tightly held peanut butter jar: Class IC have a atrong binding affinity for the Na+ channel (strong use dependence, drastic slowing of the phase 0 upstroke) dramatic effect on QRS duration, prolongs ERP in AV node, no change in AP Duration
41. Untouched potassium curtain: class IC antiarrhythmic do not affect the cardiac action potential duration
42. Illuminated top and bottom of heart: class IC antiarrhythmics treat supraventricular (A.Fib) and ventricular arrhythmias
43. Irregularly Irregular signal: Class IC antiarrhythmics treat atrial fibrillation (and flutter)
44. Converting the signal: class IC antiarrhythmics can restore and maintain normal sinus rhythm in A. Fib and Flutter
45. "Healthy Hearts Only"!: class IC antiarrhythmics are contraindicated in patients with history of structural or ischemic heart disease (proarrhythmic effects)

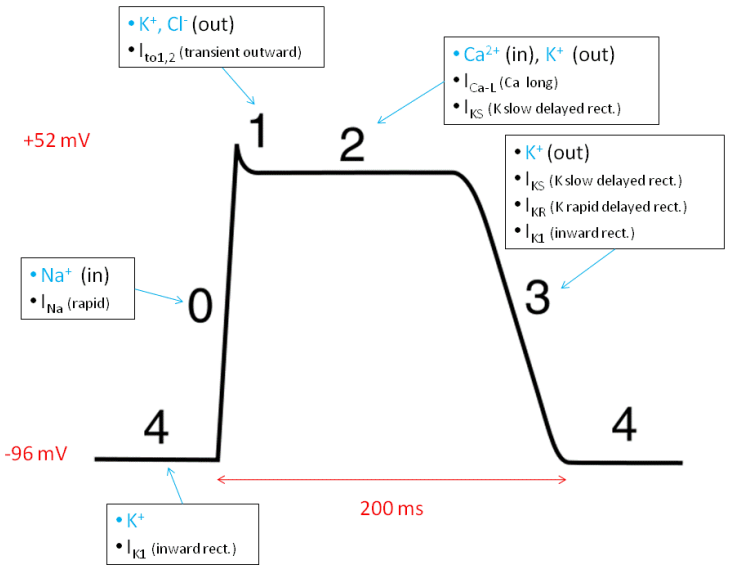

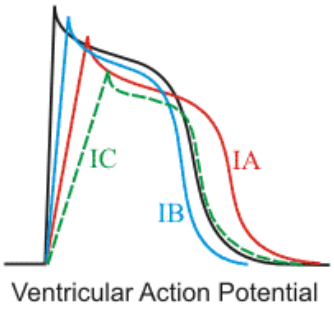

Ventricular Action Potential

- Class IA: e.g., quinidine
  - Moderate Na^+-channel blockade
  - ↑ ERP
- Class IB: e.g., lidocaine
  - Weak Na^+-channel blockade
  - ↓ ERP
- Class IC: e.g., flecainide
  - Strong Na^+-channel blockade
  - → ERP



Class II (rate control) : Beta Blockers - No (Class I sodium) **Bad Boy (Beta Blockers**) Keeps (Potassium) Clean (calcium)

1. Duet: class II antiarrhythmics
2. Muted beta bugle: beta blockers (class II antiarrhythmics)
3. Notes: beta blockers treat arrhythmias by blocking sympathetic input to SA and AV nodes
4. Torn Band Camp: beta blockers decrease cAMP
5. Crushed calci-yum ice cream cartons: decreased cAMP leads to closure of membrane calcium channels, preventing the upstroke of AV nodal action potential
6. Phase 4: pacemaker current dictated by Na+ (funny current) and other ion. Depolarization is from Ca++
7. Phase 0: upstroke dictated bt Ca2+
8. Phase 3 repolarization dictated by K+
9. Sliding up the keys: beta blockers prolong phase 4 of the nodal action potential decreased pacemaker activity, prolonged conduction time and refractory period
10. Disconnected bottom of light: beta blockers decrease atrioventricular conduction
11. Heart light Lit up top: beta blockers treat supraventricular arrhythmias (Afib and RVR)
12. IVY: IV beta blockers (esmolol) can be used for acute supraventricular arrhythmias
13. Hat shielding heart: beta blockers can cause heart block
14. Public relations: heart block manifests as a prolonged PR interval on EKG
15. Irregularly irregular static signal: beta blockers are useful in atrial fibrillation (and flutter)
16. Metronome: beta blockers prevent rapid ventricular response in atrial fibrillation and flutter “rate control” but does not fix the atrial fibrillation

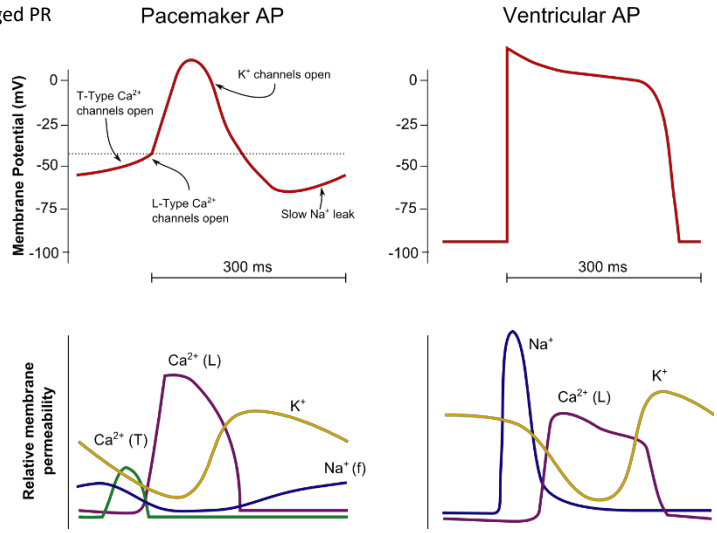



Class III (rhythm control): No (Class I sodium) Bad Boy (Beta Blockers) **Keeps (Potassium)** Clean (calcium)

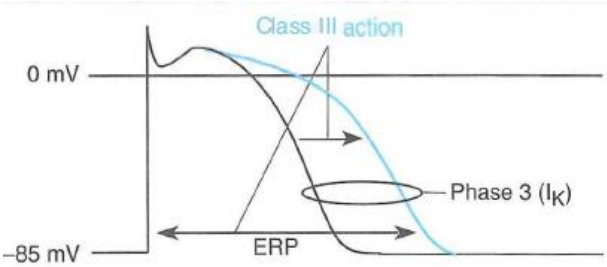

1. Phase 2: plateau dictated by Ca2+
2. Phase 3: repolarization dictated by K+
3. Potassium banana theme curtain: K+ current present during Phase 2 (plateay) and Phase 3 (repolarization) of the cardiac action potential
4. Singer pushing away the curtain: class III antiarrhythmics block K+ channels prolonging phase 2 and 3 of the cardiac action potential → prolonged refractory period
5. **"uno, dos, tres, quattro": Amiodarone shares properties of class I, II, III, and IV antiarrhythmics.**
6. **"till I die": –tilide suffix shared by dofetilide and ibutilide (class III antiarrhythmics)**
7. **Soda: sotolol**
8. Muted bugle and soda bottles: sotalol is also a beta blocker (lol suffix)
9. Heart illuminated on top and bottom: class III antiarrhythmics treat both supraventricular arrhythmias and also ventricular arrhythmias
10. Irregularly irregular signal: class III antiarrhythmics treat atrial fibrillation and flutter
11. Converting the signal: class III antiarrhythmics can restore and maintain normal sinus rhythm in atrial fibrillation and flutter
12. **Adverse effects**
13. Skull brains: amiodarone has many neurologic side effects (tremor, ataxia, peripheral neuropathy, sleep disturbances)
14. Gray sunglasses: amiodarone can cause grey corneal deposits
15. Bog and small bowties: amiodarone can cause hyper or hypothyroidism, always evaluate thyroid prior to use and monitor during
16. Fibrotic lung embroidery: amiodarone can cause pulmonary fibrosis
17. Tight button: amiodarone induced lung fibrosis causes restrictive lung diseases
18. Trampled failing heart balloon: amiodarone can induce heart failure
19. Liver spot: amiodarone can cause hypersensitivity hepatitis (always monitor LFT's)
20. Grey blue outfits: amiodarone can cause gray blue skin discoloration
21. Flash photo: amiodarone can cause photo dermatitis
22. Broken chrome bumper: amiodarone inhibits the cytochrome P450 inhibition
23. Twisted streamer: sotolol, dofetilide, and ibutilide can induce dose related torsade's (although all type III antiarrhythmics can widen the QT interval)



Class IV antiarrhythmics (rate control)- No (Class I sodium) Bad Boy (Beta Blockers) Keeps (Potassium) **Clean (calcium)**

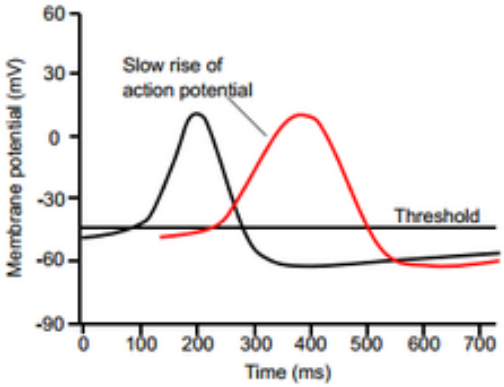

1. 4 singers quartet: Class IV (rate control at SA and AV nodes) Non dihydropyridine calcium channel blockers
2. L shaped nozzles on wall: Block L type calcium channels in the heart
3. Nondairy: non-dihydroppyridine calcium channel blockers (class IV antiarrhythmics)
4. Delicious dark chocolate: Diltiazem (non-dihydropyridine CCB)
5. Very Vanilla: verapamil (non-dihydropyridine CCB)
6. Notes on music sheet: Exert a greater effect on tissues that fire more frequently that use a calcium current, non-dihydropyridines treat arrhythmias by blocking Ca2+ current in the SA and AV nodes
7. Keys leading up the piano as the gradual phase 4: pacemaker dictated by Na+ and other ions
8. Phase 0: upstroke dictated by ca2+
9. Phase 3: repolarization dictated by K+
10. Sliding up the keys: non-dihydropyridine CCB's prolong phase 4 of the nodal action potential → decreased pacemake activity, prolonged conduction time and refractory period
11. Disconnected bottom: non-dihydropyridine CCB's decrease atrioventricular conduction
12. Illuminated top: non-dihydropyridine CCB's treat supraventricular arrhythmias (A.FIB with RVR)
13. Public relations: non-dihydropyridine CCB's will prolong the PR interval
14. Hat shielding heart: Non-dihydropyridine CCB's can cause heart block, be careful when combining with other drugs that cause AV nodal blocking like digoxin
15. Irregularly irregular signal: non-dihydroopyridine CCB's are useful in atrial fibrillation and flutter
16. Metronome: non-dihydropyridine prevents rapid ventricular response in A Fib and Flutter



Class V: Rate control

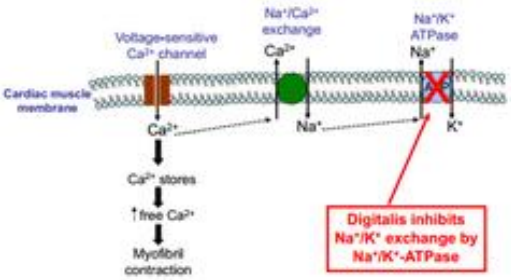

1. **DJ Foxglove: Digoxin has antiarrhythmic properties**
2. Vegas: digoxin exerts direct parasympathomimetic effects via direct stimulation of the vagus nerve → AV nodal inhibition
3. Irregularly irregulars signal: digoxin is useful in atrial fibrillation and flutter, not first line
4. Metronome: digoxin prevents rapid ventricular response in atrial fibrillation and flutter (rate control)
5. **Magnets: magnesium** is useful for the treatment of certain arrhythmias (torsades)
6. Torn twisted torsades streamers: magnesium treats torsades de pointes
7. Banana dancer pointing up: hyperkalemia can induce arrhythmia
8. Peaked streamer: hyperkalemia can cause peaked T waves (with shortened QT intervals) on ECG
9. Banana dancer pointing down: hypokalemia can induce arrhythmias, sever muscle weakness, and glucose abnormalities
10. Streamer with extra bump: hypokalemia can induce U waves at the end of the T wave on EKG
11. **Swing dancing: adenosine (a purine nucleoside with antiarrhythmic properties)**
12. Purine shaped gate: adenosine is a purine nucleoside
13. A1 swing: adenosine activated inhibitory AI receptors on the myocardium and at the SA and AV nodes
14. Banana flying out of the cup: activation of A1 receptors increases outward K+ current (hyperpolarizes, suppressed, Ca2+ dependent AP)
15. Falling calci-YUM ice cream: activation of A1 receptors suppress inward Ca2+ current
16. Note shaped dance floor: Adenosine inhibits AV nodes (decreased AV conduction, prolonged AV refractory period)
17. Hat blocking heart: Adenosine causes transient high grade heart block (direct av node inhibition for about 10s)
18. Disconnected bottom of heart: adenosine decreases atrioventricular conduction
19. Illuminated top of heart: adenosine is a first line agent for acute treatment of supraventricular arrhythmias (PVST)
20. Dilated coronary crown: adenosine causes coronary dilation (mediated by A2 receptors)
21. **Adverse Effects**
22. Flushed dancer: adenosine can cause cutaneous flushing
23. Dancer clutching chest: adenosine can cause shortness of breath, chest pain, and impending sense of doom
24. Fainting dancer: adenosine can cause fainting, headache, and hypotension
25. Energy drink blocking A1 gate: the actions of adenosine are inhibited by caffeine and theophylline (methylxanthines)



Heparin, LMWH, Fondaparinux, Direct thrombin inhibitors, Xa inhibitors

1. Beaver dam: fibrin clot
2. Throm-beaver: thrombin
3. Throm-beaver preparing stick: thrombin transforms fibrinogen into fibrin, these fibrin monomers will crosslink with calcium, a phospholipid surface and factor XIII to make a strong mesh
4. Throm-beaver II shaped teeth: factor II (thrombin)
5. FoX: factor X and Xa catalizes the conversion of pro-thrombin into thrombin (factor 2 into 2a)
6. FoX waking up throm-beaver: factor Xa converts prothrombin into thrombin.
7. **Heppy hunting: heparin**
8. Heppy hunting father: unfractionated heparin
9. Trap with III shaped bars: unfractionated heparin binds with antithrombin III
10. Trapped throm-beaver and foX: the unfractionated heparin-antithrombin III complex irreversible inactivates thrombin and Factor Xa
11. Birdwatching father: monitor APTT (activated partial thromboplastin time) to assess unfractionated heparin levels
12. Woodpecker inside tree trunk: PTT measures the function of the intrinsic pathway of the coagulation cascade
13. Heparin is not a clot buster, it will prevent the fibrin clots from forming
14. Hunting at the iliofemorial river: heparin can be used for deep vein thrombosis prophylaxis
15. Beaver dam ion the iliofemoral river: heparin can be used for acute treatment of deep vein thrombosis
16. Lung shaped tree: pulmonary arterial tree
17. Birds nest on ischemic branch: heparin can be used for prophylaxis and acute treatment of pulmonary embolism (PE)
18. Branched distal is ischemic and leafless
19. Continuous heparin drip can help reduce the development of the PE
20. Broken heart strings: Heparin is used in the setting of an acute MI, heparin is used to prevent clot extension and also formation
21. Ivy: administration IV heparin in the setting of acute DVT, PE, and MI
22. **Adverse effects of heparin**
23. Bleeding, need to keep close monitoring PTT
24. Shooting four clay plates: Heparin induced thrombocytopenia, (ex. in a 50 y/o pt receiving heparin prophylaxis for a few days then gets a swollen foot) This occurs when antibodies are made against heparin complex to platelet factor 4
25. Broken plates: heparin can cause thrombocytopenia
26. Throm-beaver dam around broken plates: HIT results in paradoxical thrombosis in the setting of thrombocytopenia
27. Depleted mineral mine: heparin can cause hyperaldosteronism (a mineralocorticoid) even in low doses heparin causes this
28. Big K: heparin induced hypoaldosteronism (type 4 RTA) causes hyperkalemia
29. Porous termite damage: heparin can cause osteoporosis
30. Protected area deterring the hunter: protamine sulfate reverses the anticoagulant effect of the unfractionated heparin (less effective foe LMWH and fondaparinux)
31. Protamine sulfate is a positively charged peptide that binds to unfractionated heparin (negatively charged)
32. **Heppy hunter daughter: low molecular weight heparin (LMWH)**
33. Trap with III: LMWH binds antithrombin III: Similar MOA as Unfractionated heparin,
34. FoX in small trap: the LMWH-antithrombin complex inhibits factor Xa with less of an effect on thrombin
35. Protected area deterring the hunter: protamine sulfate reverses the anticoagulant effect of unfractionated heparin (less effective against LMWH and fondaparinux)
36. Long tapering flag: LMWH has a prolonged half-life
37. Does not require PTT monitoring



38. Decay flag breaking a kidney shaped rock: LMWH is eliminated renally and can stay in the system if there is renal insufficiency
39. Heppy pregnant hunter: heparin is safe during pregnancy. “keep that baby heppy with heparin”
40. Intact clay pigeons: LMWH is less likely to induce HIT
41. ALL TYPES OF HEPARIN CAN CAUSE HIT, Just less likely
42. **Fido with a pair of FoXes: fondaparinux**
43. Protected area deterring the hunter: protamine sulfate reverses the anticoagulant effect of the unfractionated heparin (less effective foe LMWH and fondaparinux)
44. Fido with two cages: Fondaparinux binds antithrombin III with higher specificity that LMWH
45. FoX in small trap: the fondaparinux-antithrombin complex inhibits factor Xa with less of an effect on thrombin
46. Fido with no broken plates: Lowest risk of HIT
47. **NO intruding: bivaliRUDIN is a direct thrombin inhibitor**
48. **Big GATOR: arGATROban and dabigatran are direct thrombin inhibitors**
49. Intruding gator directly eating the throm-beaver: use direct thrombin inhibitors (argatroban, dabigatran, bivalirudin) in HIT
50. **Banned foXes: direct factor Xa inhibitors rivaroxaban and apiXaBAN**
51. Directly grabbing foX: factor Xa inhibitors bind directly
52. Open mouth: factor Xa inhibitors are oral medications, Afib
53. Irregularly irregular tv signal: direct Xa inhibitors are used for long term anticoagulation in atrial fibrillation

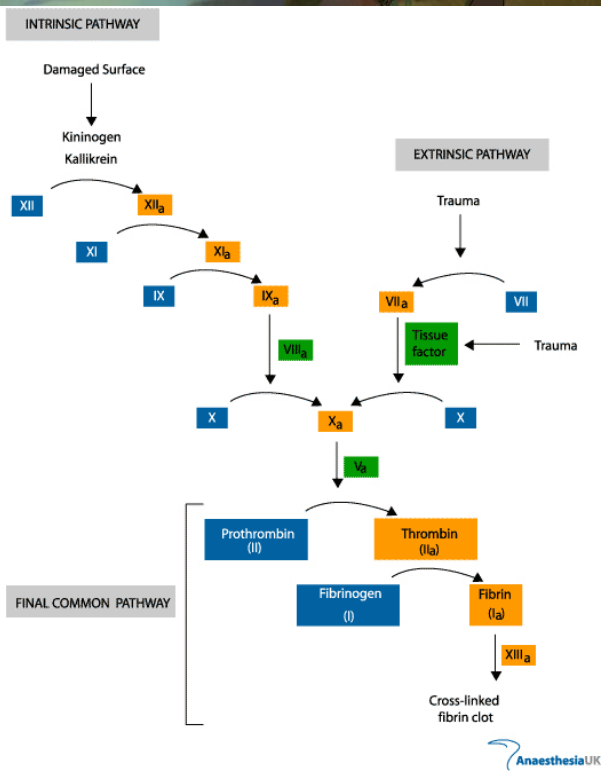



Warfarin

1. Vitamin K medic stopping the bleeding: vitamin K is a cofactor for the enzymatic activation of clotting factors
2. Blocks vitamin K epoxide reductase, this is required for activation of Vitamin K preventing clotting factors 2,7,9,10 from being produced, and proteins C and S
3. Vit K medic applies gamma shaped bandage: vitamin K promotes gamma carboxylation of coagulation factors II, VII, IX, and X
4. Throm-beaver with II shaped teeth: factor II (thrombin)
5. Seven deadly sins: Factor VII
6. Nine lives cat: factor IX
7. FoX: factor X
8. GL: gamma carboxylation occurs at the glutamic acid residue on factor II, XII, IX, and X
9. V-KOR supply boat: vitamin K epoxide reductase (VKOR) converts vitamin K epoxide (inactive) into vitamin K (Active)
10. Corporal: vitamin K promotes gamma carboxylation of proteins C
11. Sergeant: vitamin K promotes gamma carboxylation of protein S
12. Corporal and sergeant hold their troops back: proteins C and S are anticoagulant factors
13. Remember: vitamin K contributes to coagulant and anticoagulant forces
14. Warhead destroying V-KOR supply ship: Warfarin inhibits vitamin K epoxide reductase (VKOR)
15. Incapacitated Vik K medic: inhibition of VKOR prevents activation of Vit K
16. Onset of action is not immediate, not for acute thrombotic events
17. Wounded VIII soldier: factor VIII is the first clotting factor to be reduced when starting warfarin
18. Delayed warhead detonation: warfarin onset of action is 8-12 hours, full clinical effect takes 3 days
19. Soldier with open mouth leaning on warfarin bomb: oral administration
20. Long tapering flag: Long half life
21. Para trooping soldier: Monitor warfarin using PT time, this is an extrinsic factor, like the paratrooper landing extrinsically
22. INtercom Radio worn by paratrooper: the international normalized ration (INR) is also used to measure warfarin activity
23. Goal INR 2-3 for prevention and treatment of thrombosis
24. Irregularly irregular heart signal: warfarin is used for long term anticoagulation in atrial fibrillation
25. Warfarin patrolling Iliofemoral river: used as DVT prophylaxis
26. Acute txt for DVT is IV heparin, warfarin is delayed onset
27. **Adverse effects**
28. Tarantula: warfarin can cross the placental barrier and can cause a hemorrhagic disorder or prevent carboxylation reactions in bone.
29. Soldiers charging past the injured corporal: the anticoagulation protein C is reduced early in warfarin therapy, resulting in a hypercoagulable state initially
30. Black soot on corporal: warfarin induced skin necrosis due to early hypercoagulable state
31. Heparin hunters patrolling the bridge: coadministration of heparin when starting warfarin therapy prevents the early hypercoagulable state (heparin bridge)
32. Skin necrosis risk is increased with a hereditary protein C deficiency
33. Distant Vit K medic reinforcements: warfarin anticoagulation can be reversed with vitamin K (delayed effect)
34. FFP fighter pilot: fresh frozen plasma (FFP) provides coagulation factors for immediate reversal of warfarin anticoagulation
35. CYP-450 chrome tank crushing warhead: warfarin is a substrate of cytochrome P-450 (increase P450 rifampin, phenobarbital, phenytoin, decrease effects) (decrease P450, antibiotics, antifungals, SSRI's, increase effects)
36.



Aspirin, ADP receptor inhibitors, GP IIb/IIIa, cilostazol, dipyridamole

1. Peeling von Willie brand field: damaged vascular epithelium exposes collagen and von willebrand factor platelets will adhere to this and activate.
2. Holding 1b bat: binding of Von willebrand factor to GP1b receptors activate platelets
3. Home plate: activated plate degranulation
4. Aggregated players: platelet degranulation releases ADP, 5-HT, and TXA2, stimulating platelet aggregation
5. "ADP" aggregate Da players! Play youth ball 2-12y: adenosine di phosphate binds to the P2-Y12 receptor on platelets causing aggregation
6. Thrown happy face helmet: platelet degranulation releases serotonin (5-HT3) causing platelet aggregation and vasoconstriction
7. Batter's box: platelet degranulation releases thromboxane A2 (TXA2) causing aggregation and activation
8. **Thromboxane synthesis**
9. Head coach cox: Cyclooxygenase 1 (COX1) synthesizes prostaglandins (prostaglandins, TXA2) within platelets
10. Sleeping assistant coach: COX-2 expression induced during inflammation, so he is inactive until some inflammatory event
11. AA minor league dugout: COX-1 synthesizes TXA-2 from the precursor molecule arachidonic acid (AA)
12. Coach Cox twisting hat: TXA2 (synthesized by COX-1) causes vasoconstriction
13. **ASA umpire: Aspirin (ASA) antagonizing Coach Cox (COX-1)**
14. Acetyl-whistle: aspirin irreversibly acetylates COX-1 and COX2
15. ASA umpire ejecting the coaches: aspirin irreversible inhibits COX-1 and COX-2 reducing platelet activation and aggregation
16. Swollen ASA uppire: aspirin "pseudo-allergy" due to excess leukotriene synthesis, seen in asthma or nasal polyposis pts. Involves excessive leukotriene synthesis with cox inhibition. Use an ADP inhibitor, like clopidigrel if this occurs
17. **Hot dog grill: thienopyridines with –grel suffix (clopidogrel, ticagrelor, prasugrel) are surface ADP P2Y12 receptor inhibitors**
18. This inhibition is irreversible
19. "ADP" aggregate Da players! Play youth ball 2-12y: adenosine di phosphate binds to the P2-Y12 receptor on platelets causing aggregation, this is inhibited by thienopyidines
20. Greasy grill pipe: antiplatelet agents (aspirin, ADP receptor inhibitors) reduce cardiovascular events in patients with peripheral artery disease, they do not reduce the symptoms of peripheral artery disease such as atypical pain and claudication in the effected extremity
21. Angina anvil: antiplatelet agents (aspirin, ADP receptor inhibitors) reduce cardiovascular events in patients with coronary artery disease
22. Broken heart strings: use antiplatelet therapy (aspirin, ADP receptor inhibitors) in the setting of MI and other acute coronary syndromes, give as soon as possible to a patient with a STEMI
23. ASA umpire chewing tablets: give chewable aspirin tablets initially in an acute MI for immediate effect
24. Corked bat: dual antiplatelet therapy (aspirin and ADP receptor inhibitors) prevent coronary stent thrombosis
25. Black paint stroke: antiplatelet therapy (aspirin and ADP receptor inhibitors) prevents ischemic stroke in patients with atherosclerosis and known cerebrovascular disease
26. **Ty Cobb: ticlodapine** (an ADP inhibitor) causes neutropenia in 2% of patients
27. Falling granules: ticlodapine can cause granulocytopenia, you must obtain white cell and rbc count when starting therapy
28. **Fries: fibrinogen**
29. Crowd of spectators from seats 2b-3a: platelet surface receptors GP IIb/IIIa binds to fibrinogen to promote platelet aggregation
30. Seats 2b/3a: platelet surface receptor GP IIb/IIIa binds fibrinogen
31. **ABC sportscaster grabbing fries: abciximab blocks the GP IIb/IIIa receptor preventing platelet aggregation**
32. Antibody shaped microphones: abciximab is a monoclonal IgG antibody
33. **Tied game: eptifibatide and tirofiban block the GP IIb/IIIa receptor to prevent aggregation, must be given IV continuously**
34. Broken plates: GP IIb/IIIa inhibitors cause thrombocytopenia
35. Ketchup time: antiplatelet therapy increases bleeding time (a measure of platelet function)
36. **Don't phoster disinterest: Phosphodiesterase inhibitors (dipyridamole, cilostazol)**
37. Sign "up" for cAMP: phosphodiesterase inhibitors increase cAMP impairing platelet function
38. **Two pyramids: dipyramidole (an antiplatelet phosphodiesterase inhibitor)**



39. Player that Lost the ball: cilostazol

40. Dilated red sleeves: cilostazol causes arterial vasodilation
41. Dirt clods hitting leg: cilostazole treats symptoms of claudication due to peripheral artery disease
42. Stolen heart base: cilostazole can cause coronary steal, this will dilate all of the other coronary arteries preventing blood flow to the ischemic areas exacerbating ischemia
43. Dilated red crown: cilostazol causes coronary artery dilation

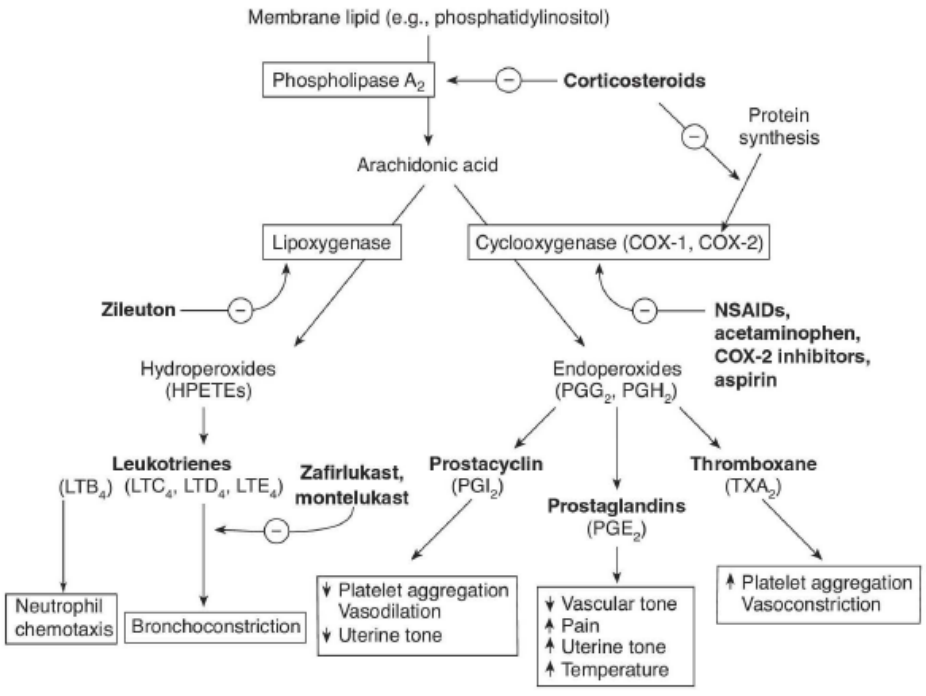



Fibrinolytic's: TPA'se: Alteplase, reteplase, tenecteplase, Streptokinase, Aminocaproic acid

1. Mesh of sticks: fibrin clot
2. **Toy PlAyset: tissue plasminogen activator (tPA)**
3. **Strepto-kinectors: streptokinase (a fibrinolytic)**
4. Purple sphere chain: streptokinase is synthesized by streptococci
5. Plasma general: plasminogen
6. Plasma general activation: plasminogen Is converted to plasmin by TPA and streptokinase
7. Plasma beams destroying wall: plasmin degrades fibrin clots
8. Paratrooper and PTTT Birdwatcher: Fibrinolytics prolong PT and PTT
9. D-shaped twigs: D-Dimer is a fibrin degradation product formed from clot lysis
10. Black paint stroke: IV fibrinolytics may be used in the setting of ischemic stroke
11. After school painting session 3:00-4:30: Administer IV fibrinolytics within 3-4.5 hours of ischemic stroke symptoms
12. Birds nest on ischemic branch: IV fibrinolytics can be used for acute treatment of sever DVT and PE
13. Broken heart strings: fibronolytics may be used in the acute management of MI
14. Corked Bat: percutaneous coronary intervention is the preferred reperfusion option in ACUTE STEMI
15. **Contraindications**
16. Calling for 2: perform PCI ideally within 2 hours of acute STEMI
17. Red pain stroke on painting: hemorrhagic stroke is a side effect of fibrinolytic therapy
18. Traumatic plasma beam: Recent head trauma is a contraindication for fibrinolytic therapy
19. Red palette knife: recent intracranial surgery is a contraindication for fibrinolytic therapy
20. White area on CT indicates cerebral hemorrhage – a contraindication for fibrinolytic therapy
21. High pressure paint tube: severe hypertension is a contraindication for fibrinolytic therapy
22. Choking hazard: Streptokinase only can cause allergic reaction and even prophylaxis
23. **Reverse fibrinolysis**
24. **Cap on paint tube: aminocaproic acid can be used to reverse fibrinolysis**
25. Plasma general tucked under arm: aminocaproic acid competitively inhibits plasminogen activation
26. **Exams: transexamic acid canbe used to reverse TPA**
27. **FFP Pilot: FFP can be used to reverse coagulopathy**
28. **Cryo ice pack: cryoprecipitate can be used to reverse coagulopathies**



Statins – HMG-CoA reductase inhibitors

1. Liver station: import and export of lipoprotein transporters
2. Intestinal airbase: lumen of the small intestine (site of free fatty acid and cholesterol absorption), flags resemble the microvilli of the brush border, 1st packaging and shipping center of endogenous lipids
3. Gold Bars: cholesterol
4. **Hot air balloon: chylomicron**
5. Chest: cholesterol ester, allows more to be packaged into the interior of the chylomicron
6. Moving chest into the hot air balloon: Cholesterol esters are packaged into the interior of the chylomicrons (intestinal cell)
7. Tridents: triglycerides, the main components of chylomicrons
8. Trident passengers: triglycerides make up most of the chylomicron
9. E-shaped flag: chylomicrons contain surface apolipoproteins A, B, C, and E, apo E plays an important role in being taken into the liver
10. Chylomicrons deliver triglycerides from the intestines to peripheral tissues
11. **Lipo-port lighthouse: Lipoprotein Lipase (LPL)**
12. Trident passengers disembarking at lipo-port lighthouse: triglycerides in chylomicrons are hydrolyzed by LPL releasing free fatty acids
13. Muscle shells: free fatty acids can be used for energy by heart and skeletal muscle
14. Adipocyte sea foam: free fatty acids can be converted back to triglycerides and stored in adipose tissue
15. Once depleted of nutrients, these chylomicrons return to the live where they are returned to the circulation
16. LoaD L receptor: LDL receptor
17. Pulling in E-Shaped flag: LDL receptor binds to ApoE and transports chylomicron remnant into liver via endocytosis
18. Cholesterol from chylomicron remnants are used by the liver
19. HMG crude ore reducer: HMG CoA reductase synthesizes cholesterol in the liver
20.
21. Evaluator: first intermediate in cholesterol synthesis is mevalonic acid
22. **Very low density airship: VLDL Very low density lipoproteins**
23. Cholesterol esters are packaged into the interior of VLDL's (hepatocyte)
24. Trident passengers: triglycerides make up most (60%) of the VLDL
25. B shaped anchor: apolipoprotein B100 is found on "bad cholesterol" (LDL and VLDL)
26. VLDL's deliver triglycerides from the liver to the peripheral tissues
27. Trident passengers disembarking at lipo-port lighthouse: triglycerides in VLDL's are hydrolyzed by LPL, releasing Free Fatty Acids
28. **Low density ship: low density lipoprotein** (LDL formed as VLDL's lose triglycerides via LPL and hepatic lipase)
29. Chest cargo: LDL's contain a core of cholesterol esters
30. LDL's deliver cholesterol to peripheral tissues expressing LDL receptors (like adrenal cells)
31. LoaD L receptor: LDL receptor
32. Pulling in B shaped anchor: LDL receptor binds ApoB and transports LDL particle into liver via receptor mediated endocytosis
33. B shaped anchor: apolipoprotein B100 is found on "Bad cholesterol" LDL and VLDL
34. **High-density submarine: High density Lipoprotein (HDL)** Nascent HDL is secreted by the liver and intestine
35. Deep sea diver collecting gold bars: HDL extracts cholesterol from membranes of peripheral tissues
36. Load Catch platform: lecithin: Cholesterol acyltransferase (LCAT) converts free cholesterol into cholesterol esters for transport by HDL
37. Loaded submarine: mature HDL particle contains LCAT generated cholesterol esters. HDL is critical for reverse cholesterol transport



38. Chest transform platform: HDL transfers cholesterol esters to LDL's and VLDL's to be transported back to the liver
39. Scavenger-1 dock: HDL Delivers cholesterol esters directly to the liver via scavenger 1 receptor.
40. **Steampunk pirate: Statins (simvastatin, avorastatin, rosuvastatin) extensive 1st pass metabolism**
41. Knocking over HMG crude ore reducer: statins inhibit HMG CoA reductase, reducing valinate and endogenous cholesterol production
42. Statin-punk threatening workers to pull in LDL ship: statins cause increased LDL receptor expression on hepatocytes, clearing LDL's from circulation
43. Sinking LDL ship: statins are most effective drugs for lowering LDL's (30-60%)
44. Statin-punk pirate kicking off trident passenger: statins can lower triglycerides (mild effect)
45. Raised HDL submarine: statins can increase HDL (mild effect)
46. Gold bar plunder: Hypercholesterolemia (LDL) treated with lifestyle modification and statins
47. **Guardian angel: Statins are the most effective lipid lowering medication for preventing future cardiovascular events**
48. Yellow filled coronary crown: statins are the only lipid lowering drug consistently proven to reduce risk of atherosclerotic heart disease
49. Statin therapy initiated in setting of MI and other acute coronary syndromes (ACS)
50. Candy jar: statins reduce risk of cardiovascular events and mortality in high risk diabetics
51. Clogged pipe: statins reduce risk of cardiovascular events and mortality in patients with peripheral artery disease
52. Black paint stroke: statins reduce risk of future vascular events in patients with history of TIA or stroke
53. Tarantula: statins may be teratogenic
54. Bite out of crispy chicken: statins can cause myopathy weeks to months after starting therapy (proximal muscle weakness/soreness), difficulty raising arms above head
55. Crispy chicken bucket: statins can cause elevations in serum CK (myopathy)
56. Raised LFT flag: mild elevations in liver function tests (LFT's) are common (reversible with discontinuation of statin)
57. Chrome tank with CYP bumper: all statins except pravastatin are metabolized by the cytochrome p450 (CYP-450) in the liver leading to an increased risk of developing myopathy

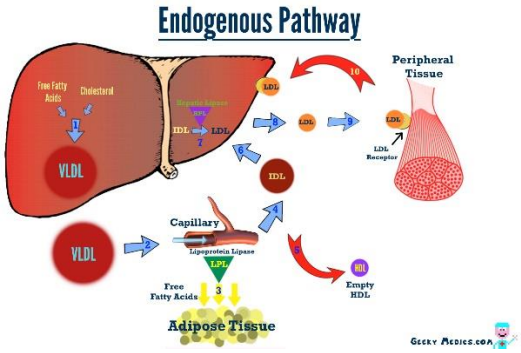

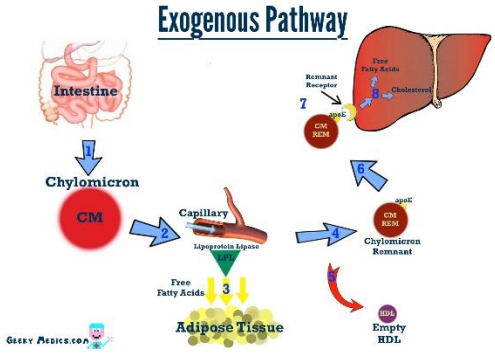



Cholestyramine, ezetimibe

1. Liver station: import and export of lipoprotein transporters
2. Intestinal airbase: lumen of small intestine site of cholesterol and bile acid absorption
3. Sea "gall": bile acids (derived from cholesterol) are released into the intestinal lumen
4. Liver station worker unloading sea "galls": the liver metabolizes cholesterol into bile acids (conjugated to become water soluble)
5. Sea galls exiting liver station: bile acids (derived from cholesterol) are secreted from the liver into the biliary tract and reabsorbed in the terminal ileum
6. Sea Gall droppings swept back to liver station: normally 95% of bile acids in the ileum are recycled back to the liver through enterohepatic circulation (hepatic vein)
7. Disabled sea gall droppings sweeper: bile acid resins prevent recycling of bile acids to the liver
8. **Cho"lobetser"amine: bile acid binding resins prevent bile acids from returning to the liver (cholestyramine, colestipol, colesevam)**
9. Empty gold stores: resins interrupt bile acid recycling and promote synthesis of new bile acids, depleting cholesterol stores
10. HMG crude or reducer: HMG CoA reductase
11. Activating HMG crude ore reducer: resins interrupt bile acid recycling, causing HMG CoA reductase to synthesis more cholesterol
12. Activating LoaD L receptor: resins interrupt bile acid recycling, causing upregulation of LDL receptor and uptake of circulating LDL
13. Low-Density ship: Low Density Lipoprotein (LDL)
14. Used in ots that have primary hypercholesteremia
15. **Adverse effects**
16. Very-low-density airship: Very Low Density lipoprotein (VLDL) exit liver
17. Trident passengers: triglycerides carried on VLDL's
18. Cho"lobster"amine scaring airship away: bile acid resins (cholestyramine, colestipol, colesevelam) cause hypertryglycemia (increased VLDL's)
19. Because of this do not use this in hypocholesteremia with concomitant hypertriglycemia
20. Sea"gall" stones: bile acid resins (cholesryamine, Colestipol, Colesevelem) can cause cholesterol gall stones
21. Cho"lobster"mine clamping pipe: bile acid resins can cause constipation and bloating. So not use in pts with diverticulitis, or preexisting bowel disease
22. DEcK-A: bile acid resins impair absorption of fat soluble vitamins A, D, E, K
23. Cho"lobster"amin clashing with statin punk: bile acid resins decrease statin absorption (administer 4 hours apart)
24. **Z shaped Eel: eczetimibe**
25. Z shaped eel blocking gold delivery at intestinal airbase: ezetimibe blocks intestinal absorption of cholesterol
26. Hot air balloon: chylomicron
27. Z shaped eel: ezetimibe: will prevent intestinal absorption of cholesterol decreasing chylomicron carrier
28. Empty chest delivery: ezetimibe restricts liver's access to exogenous cholesterol
29. Activating HMG crude ore reducer: ezetimibe blocks intestinal cholesterol absorption, causing HMG CoA reductase to synthesize more cholesterol
30. Sunken LDL ship: ezetimibe blocks intestinal cholesterol absorption, causing upregulation of LDL receptors and uptake of circulating LDL
31. STATINS ARE LIPID LOWERING DRUGS OF CHOICE FOR CARDIOVASCULAR DISEASE, USED IN CONJUNCTION WITH STATIN THERAPY
32. Ezetamibe does not cause gallstones or hypertrigylcemia
33. Raised LFT flag: ezetimibe may cause increased liver function tests (LFT's)
34. **Steam-ctopus man: evolocamab is a PCSK9 inhibitor**
35. Pesky "9" crabs inhibiting LoaD L receptor workers: PCSK9 normally causes degradation of LDL receptors
36. Octopus antibody-shaped claws: Many PCSK9 inhibitors (evolcumab) are antibodies
37. Steam-octopus man removing pesky crabs: evolcumab binds PCSK9 and prevents degradation of LDL receptors, increasing uptake of circulating LDL



Loch Niacin

1. LIPO-Port Light house: Lipoprotein Lipase (LPL)
2. Trident passengers disembarking at Lipo-Port light house: triglycerides in VLDL's are hydrolyzed by LPL, releasing free fatty acids
3. Muscle shells: free fatty acids can be used for energy by heart and skeletal muscle
4. Adipocyte sea foam: free fatty acids can be converted back into triglycerides and stored in adipose tissue
5. **Gem-fibrozil jellyfish: fibrates (gemfibrozil and fenofibrate)**
6. News PPAR: PPAR-alpha
7. Lighthouse keeper lighting newsPPAR signal: fibrates activate PPAR-alpha to upregulate LPL
8. Trident passengers escape airship: fibrates decrease serum triglycerides (increase hydrolysis of VLDL and chylomicron triglycerides via LPL)
9. Gem-Fibozil jellyfish takes down airship: fibrates decrease serum VLDL 35-50% (stimulate LPL and reduce hepatic VLDL secretion)
10. Gem-fibrozil jellyfish sinks ship: fibrates decrease serum LDL (mild effect) by reducing VLDL
11. Statins are LDL lowering drugs of choice
12. Elevates High density submarine: fibrates increase serum HDL (mild effect) by activation of apolipoproteins A1 and A2 that will create nascent HDL's
13. **Adverse effects**
14. Elevated statin-punk eating crispy chicken: Fibrates combines with statins increases risk of myopathy
15. Sea"gall" stones: fibrates can cause cholesterol gall stones
16. **Loch Niacin monster: niacin (vitamin B3)**
17. Elevate High Density submarine: niacin is MOST EFFECTIVE drug for increasing serum HDL (~30%)
18. Trident passengers escape airship: niacin decreases serum triglyceride (reduces hepatic VLDL secretion)
19. Loch Niacin monster takes down airship: niacin decreases serum VLDL (reduces hepatic secretion)
20. Loch Niacin monster sinks ship: Niacin decreases serum LDL (mild effect) by lowering VLDL
21. Red fiery furnace: niacin can cause cutaneous flushing and warmth
22. Pro slugger bat: prostaglandins (cause flushing) is a mediator of vasodilation and inflammation
23. Fire extinguisher: NSAIDs (including aspirin) can be used to prevent flushing from niacin
24. Elevated candy: niacin can cause hyperglycemia
25. Yellow knitting needles: niacin can cause hyperuricemia (can precipitate gout)
26. Raised LFT Flag: niacin can cause elevated liver function tests (LFT's) leading to severe hepatotoxicity, requires monitoring
27. Omega fish leaking oil: fish oils are high in omega 3 fatty acids
28. Sunken tridents: fish oil can lower serum triglycerides (by decreasing VLDL and apoB production)

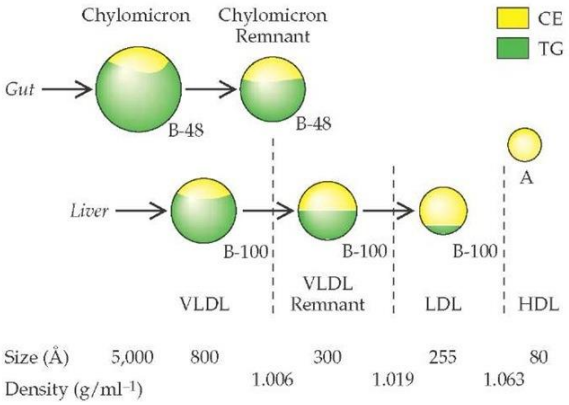



NSAID's, selective COX inhibitors

1. **AA League: Arachidonic Acid** (precursor molecules to prostanoids and Leukotrienes) a poly unsaturated fatty acid in almost every cell membrane
2. Pla2y ball: phospholipase A2 (PLA2) hydrolyzes arachidonic acid from the cell membrane
3. Head coach cox: cyclooxygenase-1 (COX-1) is constitutively expressed and active in most cells
4. Assistant coach: COX-2 expression is induced by inflammation
5. Batter's box: thromboxane A2 (TXA2) is synthesized by COX-1, just like how the batter needs to step inside the box and now the plate is activated
6. Twisted red hat: TXA2(from COX-1) causes vasoconstriction
7. **Pro-slugger bat: prostaglandins, made by COX-1**
8. Pro-slugger protecting catcher with gastrointestinal pads: COX-1 synthesizes gastric cytoprotective prostaglandins
9. Assistant coach in endothelial dugout: COX-2 is expressed in vascular endothelial and smooth muscle cells and mediates vascular smooth muscle effects
10. Pro-cycle pitching machine: prostacyclin (PGI2) is synthesized by COX-2
11. Pro-cyclers dilated red barrel: PGI2 causes vasodilation
12. Pro cycler dispersing the plates in the audience: PGI2 inhibits platelet aggregation
13. Pro-sluggers at the afferent tunnel: COX-1 and COX-2 synthesize prostaglandins that dilate the afferent arteriole
14. Pro-slugger activating the sprinkler: COX-2 synthesizes prostaglandins that increase vascular permeability
15. Pro-Slugger in pain: COX-2 synthesizes prostaglandins that increase pain sensitivity
16. Pro-slugger with flaming head: COX-2 synthesizes prostaglandins that induce fever
17. Right dugout Head Coach Cox: Cyclooxygenase -1 is constitutively expressed
18. Right dugout Assistant coach: cyclooxygenase-2 (COX-2) expression is induced by inflammation
19. Anti-inflammatory Fire extinguisher: NSAID's
20. Head coach and assistant couch doused by fire extinguisher: NSAID's reversible inhibit both COX-1 and COX-2
21. **BLAC sox: diclofenac and ketorolac (NSAID's)**
22. **INDIGO sox: Indomethacin (NSAID) closure of ductus arteriosus**
23. **SOX CAM: meloxicam and piroxicam (NSAID's)**
24. **Approximately 110 Mph: Naproxen (NSAID)**
25. **Adverse effects**
26. Burned hole in the gastrointestinal pads: Inhibition of COX-1 by NSAID's can cause gastric inflammation, erosions, and ulceration
27. Ketchup on the gastrointestinal pads: inhibition of COX-1 by NSAID's can cause GI bleeding
28. Ketchup on clock: inhibition of COX-1 by NSAIDs can prolong bleeding time
29. Bursting from high pressure: NSAIDs can increase blood pressure due to COX inhibition in the kidney, decreasing sodium excretion
30. Baseball-filled kidney containers: NSAIDs can cause acute interstitial nephritis
31. Contracted proximal end of fire extinguisher hose: NSAID's cause afferent arteriole vasoconstriction, decreasing GFR. ACE inhibitors will effect GFR greatly when used with NSAIDS due to the great decrease of GFR, this can lead to …
32. Sloughing of cleat spikes: NSAIDs can cause renal papillary necrosis (sloughing of renal papillae)
33. Elevated "lift-ium" balloons: NSAIDs can increase serum lithium concentrations
34. Plastic bone-shaped balloon: NSAIDs (indomethacin generally) can cause aplastic anemia
35. Depleted mineral mine: NSAIDs will cause Impaired renin secretion leading to hyperaldosteronism (decreased mineralcorticoids) that will lead to hyperkalemia, type IV RTA
36. Big K: NSAID induced hyperaldosteronism can cause hyperkalemia
37.



38. ASA umpire: aspirin

39. ASA umpire ejecting the coaches: aspirin **irreversible** inhibits COX-1 and COX-2
40. Acetylation whistle: aspirin acetylates COX-1 and COX-2 resulting in irreversible inhibition
41. Child in Kawasaki's ATV: aspirin is useful in Kawasaki's disease (the most common vasculitis in children) manifests as fever, conjunctivitis, erythema of lips and oral mucosa, rash, and cervical lymphadenopathy
42. Tissue box: Reye's syndrome occurs when a child is given aspirin in the setting of a viral illness. Consists of rapidly progressive encephalopathy with hepatic dysfunction after apparent recovery of a viral illness
43. Rays shirt pattern: aspirin use in children can lead to development of Reye's syndrome
44. Cerebral baseball cap: Reye's syndrome encephalopathy (confusion, seizure, coma)
45. Fat liver spot on cow: Reye's syndrome hepatic dysfunction (hepatic steatosis, hepatomegaly)
46. Mudpile: aspirin toxicity can cause an anion gap metabolic acidosis
47. Blowing "OH-" bubbles: aspirin causes respiratory alkalosis prior to metabolic acidosis
48. Tin Cans: aspirin can cause tinnitus
49. Charcoal lines: activated charcoal can be used to control aspirin in the setting of acute toxicity, alkanlinization of the serum allows you to pull aspirin out of the CNS
50. Bases loaded hose: alkalinization of the serum and urine with a basic solution (sodium bicarb) increases the renal excretion of aspirin
51. Fire extinguisher behind cracked kidney-shaped glass: minimize NSAID use in patients of risk for acute kidney injury, because it can exacerbate renal insufficiency, same with MI, or any other issue that may decrease renal perfusion
52. Exiting pregnant lady: avoid NSAIDs in 3rd trimester due to risk of premature closure of ductus arteriosus (highest risk with indomethacin and ibuprofen)

53. Celebrating catcher in the dugout drenching the assistant coach: celecoxib is a selective COX-2 inhibitor

54. Clean gastrointestinal pads: celecoxib has reduced ulcer and bleeding risk by avoiding COX-1 inhibition
55. Thrombus ice cubes: celecoxib may increase the risk of ischemic cardiovascular disease, avoid in acute MI and stable angina
56. Rotten sulfa eggs: celecoxib is a sulfa drug
57. **Icy-medicine spray on assistant coach: acetaminophen** inhibits COX-2, acting as an antipyretic and analgesic (NOT anti-inflammatory) used for mild to moderate pain, osteoarthritis and some Rheumatoid arthritis
58. Goat scared by the icy medicine: toxic levels of acetaminophen deplete glutathione in the liver (glutathione will inactivate the toxic metabolite NAPQI) goat:glutathione
59. Liver spot on goat: acetaminophen causes hepatotoxicity (via the toxic metabolite: NAPQI)
60. Charcoal lines on the fan above acetaminophen spray: activated charcoal can be used to absorb acetaminophen in setting of acute toxicity
61. N Flower seeds: n-acetylcysteine (antidote for acetaminophen overdose)
62. Goat attracted to N-Flower seeds: N-acetylcysteine restores hepatic glutathione stores to treat acetaminophen hepatoxicity



Gout Drugs

1. Knitting needles: uric acid crystals
2. Yellow center aisle: renal tubule
3. Uric acid yarn in the center aisle: uric acid excretion by kidney
4. Purine shaped collection plate: purines (purine metabolism produces uric acid)
5. Small kid passing XO note: hypoxanthine (purines are converted to hypoxanthine)
6. XO love letter: Xanthine oxidase (converts hypoxanthine to xanthine)
7. Larger kid passing XO note: Xanthine
8. XO love Letter: Xanthine Oxidase converts Xanthine to Uric acid
9. Tripping over Yarn and foot on fire: acute gout, will commonly manifest in the 1st metatarsal
10. **Fire extinguisher: NSAIDs**, 1st line treatment in acute gout (indomethacin)
11. **Moon Face: glucocorticoids** (prednisone) treat acute gout
12. **Choir sing: colchicine** treats acute gout, taken orally 12-24 hours
13. Spindly palm fronds: spindle apparatus microtubules
14. Binding palm fronds: colchicine binds intracellular tubulin preventing polymerization of microtubules
15. First responders blocked by choir: colchicine disrupts the cytoskeleton of neutrophils thereby inhibiting neutrophil migration, phagocytosis, and degranulation
16. Muddy floor: colchicine can cause diarrhea
17. Lying: pseudogout (acute treatment is similar to acute gout – NSAIDs, glucocorticoids, colchicine)
18. Blue rhomboid incense holder: Pseudogout is positively birefringent (blue as polarized light) and forms rhomboid shaped crystals)
19. **Pure nun: allopurinol manages chronic gout**
20. Nun grabbing XO notes: allopurinol inhibits xanthine oxidase
21. Stopped XO note in nun pocket: febuxostat inhibits xanthine oxidase (chronic gout)
22. Shattered cancer crab glass: uric acid crystals can form in tumor lysis syndrome after starting cytotoxic chemotherapy
23. White T Cell crusaders: tumor lysis syndrome is most common with treatment of lymphoma and acute lymphoblastic leukemia
24. Nun sweeping crystals: allopurinol prevent uric acid deposition in setting of tumor lysis syndrome
25. Needle in flesh and biting of finger of kid by stained glass window: Lesch-Nyhan syndrome (associated with hyperuricemia is managed with allopurinol. Will see picking of the skin or biting of the lips in a child where uric acid is causing pain
26. Concentrated purine beads on nuns: allopurinol inhibits breakdown of purine analogs (6 mercaptopurine and azathioprine increasing risk of toxicity) and may cause a mild rash
27. Sloughed off red mask: allopurinol can cause Stevens-Johnsons syndrome
28. Eo-slingshot granules: eosinophilia
29. Eosinophilic Dress: allopurinol can cause drug reaction with eosinophilia and systemic symptoms (DRESS syndrome)
30. Probation officer Cid: Probenacid (a uricosuric agent) manages chronic gout
31. Preventing punk from grabbing yarn: probenecid decreases renal tubular reabsorption of uric acid
32. Accumulating yarn and needles: probenecid may increase the risk of forming renal stones due to increased uric acid excretion.
33. "Drugs" tattoo: probenecid can inhibit the excretion of many drugs
34. Cid's purple pencil: probenecid prevents excretion of penicillin
35. Uricosyurics are only for under excretors and only for chronic gout.
36. Rotten sulfas eggs: probenecid is a sulfa drug
37. ASA umpire: aspirin
38. Preventing son from grabbing yarn: aspirin at high doses can prevent tubular reabsorption of uric acid
39. Little ASA umpire yarn: aspirin at low doses inhibits uric acid excretion
40. Holy water just in case!: pegloticase converts uric acid into water soluble allantoin
41. "Just in case" plegoticase (recombinant uricase) can be used in chronic gout management
42. Watermelon with bite: pegloticase can cause hemolysis in G6PD deficiency (bite cells)
43. Choking Kid: pegloticase can cause anaphylaxis
44. Ivy: pegloticase is administered IV



Nitrates: nitroglycerine, isosorbide mononitrate/dinitrate

1. **Dynamite: nitrates (nitroglycerine)**
2. Anvil: antianginal therapy
3. Nitric oxide exhaust: nitrates are metabolized and release nitric oxide
4. Grump: nitric oxide causes and increase in cGMP in vascular smooth muscle
5. Cut P lock off chain: increased cGMP causes myosin light chain dephosphorization, preventing its interaction with actin
6. Dilated blue pants: nitrates cause venous dilation and increased venous capacitance
7. Modest dilated red sleeves: nitrates cause some vasodilation of large arteries, but minimal dilation of arterioles
8. Turning the nozzle down on the preload: Nitrates decrease preload, venous return and filling of the heart, and decreasing the wall stress
9. Angina anvil: nitrates treat chronic stable angina
10. Discarded oxygen mask: nitrates reduce myocardial oxygen requirements
11. Folded tongue: sublingual administration of nitroglycerine avoids first pass metabolism (for acute symptom relief)
12. Mouth cave: oral nitrate preparations have a longer duration of action
13. **Single nitro stick in cave: isosorbide mononitrate**
14. **Double nitro stick in cave: isosorbide dinitrate**
15. Big pile of dynamite: oral nitrate preparations require larger doses due to first pass metabolism
16. Anvil medal: nitrates prinzmetal angina
17. Brocken heart strings: nitrates are useful in acute coronary syndrome
18. No right turn: nitrates should be avoided in right sided MI, should give IV fluids to increase preload
19. Emergency shut off: IV nitroglycerine can be used in hypertensive emergency
20. Wet lung spots: nitroglycerine is an acute treatment for pulmonary edema
21. Fainting woman: nitrates can cause hypotension
22. Doctor with Heart reflex hammer: nitrate induced hypotension activates baroreceptors that cause reflex tachycardia
23. Muted beta bugle stopping doctor: beta blockers help prevent reflex sympathetic activation
24. Guy holding the nails for john angina with a red face: Nitrates can cause throbbing headaches and flushing
25. Oxidized iron wheels: nitrates can cause methemoglobinemia
26. NO tolerance for 24 hour workday: avoid tolerance with daily nitrate free intervals, if not done this may lead to tachyphalaxis and decreased metabolism of the drug
27. Monday disease: with workplace exposure, tolerance disappears over weekend causing headache and dizziness to recur on Monday. This can happen in the chemical industry, called Monday disease
28. Fill station on blocked track: patients on PDE-5 inhibitors (sildenafil) should avoid nitrate therapy for 24 hours (give you severe hypotension)
29. Obstructed heart smokestack: nitrates are contraindicated with hypertrophic obstructive cardiomyopathy



Sumitriptans and Migraine

1. Pounding head shaped bell: Migraine therapy
2. Three gems on hat: migraine pain due to activation of trigeminal nerve afferents in the meninges
3. Dilated sleeves: trigeminal afferents release vasoactive peptides (CGRP, substance P, neurokinin A) onto meningeal vessels → vasodilation and protein extravasation
4. **Sumowrestler: triptans (sumitriptan)** are an acute treatment for migraines, selective agonists of the 5-HT1b and 5-HT1d receptors found on the meningeal vessels, trigeminal nerve, and brainstem
5. "b" and "d" shaped fingers: triptans are 5-HT1b and 5-HT1d receptor agonists
6. Smiley face on headband: 5-HT1b and 5-HT1d receptors are located on the meningeal vessels, this may induce vasoconstriction and attenuates inflammation and decreases stretch at pain receptors
7. Sumo taking out 3 gems: triptans also activate 5-HT1b and 5-HT1d on the trigeminal nerve, preventing release of vasoactive peptides
8. Hair stem: triptans also activate 5-HT1b and 5-HT1d receptors in the brainstem, inhibiting pain pathways
9. **Adverse effects**
10. Constricted coronary crown: triptans cause coronary vasospasm
11. Anvil in the sumo's shadow: triptans are contraindicated in patients with angina
12. Anvil medals in the sumo's shadow: triptans are a known trigger of Prinzmetal angina
13. Lantern cluster: triptans (and inhaled oxygen) are also an acute treatment of acute cluster headache
14. Fire extinguisher: NSAID's are an acute treatment for migraine
15. **Long term prophylaxis**
16. **Calci-yum ice cream nozzles: CCB's are widely used for migraine prophylaxis**
17. **Muted beta bugle: beta blockers can be used for migraine prophylaxis**
18. **Festival PRO: valPROic acid (an antiepileptic) can be used for migraine prophylaxis**
19. **Toupee: topiramate (an antiepileptic) can be used in migraine prophylaxis**
20. **Tricycle: tricyclic anti-depressents (amitryptaline) can be used for migraine prophylaxis**
21.



Prostaglandins, prostacyclin, bosentan, PDE5 inhibitors

1. Head and assistant coaches: COX-1 and COX-2 produce prostanoids (prostaglandins)
2. Pro slugger bat: prostaglandins
3. E in extreme sports: PGE1 and PGE2
4. **Dill pickle theme board: alprostadil (PGE1) and erectile dysfunction therapy**
5. Erect bat: alprostadil treats erectile dysfunction
6. Dilated red sleeves on skateboarder: alprostadil is a vasodilator
7. Opening air duct: alprostadil maintains patent ductus arteriosus
8. Fire extinguisher and closing the air duct: NSAID's (indomethacin) promote the closure of PDA
9. **Missed swing: misoprostol (PGE1)**
10. Gastric protective equipment: misoprostol promotes protective mucus secretion by gastric mucosa
11. Missed swing hitting fire extinguisher: misoprostol can prevent NSAID-induced peptic ulcer
12. Opening uterus bag: misoprostol can facilitate labor or terminate pregnancy
13. Flooded bathroom: misoprostal can cause diarrhea
14. **Dino helmet: dinoprostone (PGE2)**
15. Opening uterus bag: dinoprostone promotes uterine contraction and ripens the cervix to facilitate labor or terminate pregnancy
16. **F in Foot wear: PGF2a**
17. Cardboard box: carboprost (PGF2a)
18. Opening uterus bag: carboprost promotes uterine contraction to control postpartum hemorrhage or terminate pregnancy
19. **LA tan sandals: LAtanoprost (PGF2a)**
20. **World traveler boots: Travoprost (PGF2a)**
21. Leaking eyeballs: latanoprost and travoprost treat glaucoma by increasing aqueous humor outflow
22. Brown sunglasses: latanoprost and travoprost can produce brown pigmentation in the iris
23. High tension pulmonary rackets: pulmonary hypertension, usually manifests as dyspnea and exercise intolerance in women aged 20-40
24. Dilated pro-cycler: prostacyclin analogs cause vasodilation (ilioprost, epoprostenol)
25. iLow –ePRO: iloprost and epoprostenol (prostacyclin analogs) treat pulmonary HTN. Epoprostanol when delivered by IV can be used first line will improve symptoms, prolong survival and delay lung transplants
26. Fainting customer: Adverse effects: Flushing headache, and hypotension
27. **Fill: -fill suffix of phosphodiesterase isoform 5, (PDE-5) inhibitors (sildenafil, tadalafil)**
28. Don't phoster disinterest: phosphodiesterase isoform 5 (PDE-5) inhibitors (sildenafil, tadalafil)
29. Grump: PDE-5 inhibitors increase cGMP
30. increased cGMP causes myosin light chain dephosphorization, preventing its interaction with actin
31. Erect bat: PDE-5 inhibitors (sildenafil, tadalafil) treat pulmonary hypertension and erectile dysfunction
32. **Boss man stan: bosentan treats pulmonary HTN**
33. End o' the line: bosentan is an endothelin inhibitor
34. Dilated red sleeves: bosentan (an endothelin inhibitor) causes vasodilation
35. Liver spot on shirt: bosentan is associated with fatal hepatotoxicity



Antihistamines: H1 receptor antagonists

1. Beehive: histamine sequestered inside the granules of mast cells
2. "Q" dandelion: H1 histamine is coupled to the Gq protein (mediates allergic inflammation)
3. Honeypot with 2"S" handles: H2 histamine receptors is coupled to Gs protein
4. Golden gastric honey: H2 histamine receptor mediates gastric acid secretion
5. Dripping nose sap: histamine increases nasal and bronchial mucus production (H1 receptor activation)
6. Dripping vesicular sap: histamine increases vascular receptor permeability (H1 receptor agonist)
7. Constricted lung branch: histamine causes constriction of bronchial smooth muscle (H1 receptor activation)
8. Brain tree: histamine functions as a neurotransmitter (H1 receptor regulates sleep and arousal)
9. **Bee swatter: H1 receptor blocker (antihistamine) treats allergy**
10. **Dragonfly fairy: diphenhydramine and dimenhydranate are 1st generation H1 Blockers**
11. **Color fairy: chlorphenramine (1st gen H1 blocker)**
12. **fairy cuiSINE: hydroxyZINE, mecliZINE, promethaZINE, (1st generation H1 receptor blockers)**
13. Fairy dust and dander: histamine mediates type-1 allergic reaction → hives, allergic rhinitis, (H1 receptor blockers are 1st line therapy)
14. Seasick fairy sailors: 1st generation H1 blockers treat vestibular nausea or motion sickness (lipophilic → enter CNS → act on vestibular system and brainstem)
15. Sleeping under brain tree: 1st generation H1 blockers cause drowsiness (lipophilic → cross BBB → central effects)
16. Anti-muscarinic tea party: 1st generation H1 blockers antagonize –peripheral and central muscarinic receptors (pupillary dilation, dry mouth, urinary retention, constipation, exacerbation of glaucoma, and delirium)
17. adrenergic properties)
18. Falling "extra parking cone: 1st generation H1 blockers treat extrapyramidal side effects caused by antipsychotics (acute dystonia) (antimuscarinic effects re-establish dopaminergic-cholinergic balance)
19. Stuffed fairy: 1st generation H1 blockers stimulate appetite and weight gain (anti-serotonergic effects)
20. Cut smiley face cake: 1st generation H1 blockers antagonize serotonin receptors in the CNS
21. Extinguished single alpha candle: 1st generation H1 blockers antagonize alpha-1 receptors → dizziness and hypotension
22. Fainted fairy: 1st generation H1 blockers cause dizziness and hypotension (anti alpha-adrenergic effects)
23. Delirious elderly man: 1st gen H1 blockers cause cognitive impairment in the elderly (central antihistamine and antimuscarinic effects)
24. **Fox, satyr, and rat: 2nd generation H1 blockers, Fexofenadine, cetirizine, loratidine**
25. Fox, satyr, and rat stand outside the brain tree: 2nd generation H1 blockers are less lipophilic → do not cross BBB → less sedating (also less antimuscarinic, antiserotonergic, or anti-alpha



Asthma: Beta 2 selective agonists, Cromolyn, Leukotriene inhibitors, sulfate, olmalizumab, methylxanthanes

1. Dilated beta 2 tuba: selective beta-2 agonists (albuterol) treat bronchoconstriction in asthma
2. **ROL call: -"rol" suffix of the selective beta-2 agonists (albuterol, pirbuterol)**
3. "do not disturb": terbutaline (a selective beta 2 agonist) treats bronchoconstriction in asthma
4. Inhaler: selective beta 2 agonists (albuterol) are available as metered dose inhalers for acute symptom relief
5. **Moon face: inhaled corticosteroids** (beclomethasone, budesonide, fluticasone) can be added as daily maintenance therapy for persistent symptoms
6. Moon eclipsing inflammatory sun: corticosteroids treat asthma by blocking inflammation and cellular inflammation
7. Canadian snow cones: candida albicans,
8. Snow cone tongue: inhaled corticosteroids (beclemthasone, budesonide, fluticasone) can cause oropharyngeal candidiasis. Treated with tropical clopiprazole
9. AA league: arachidonic acid is the precursor of leukotrienes (and prostanil) synthesis
10. Lacrosse coach Lox: lipoxygenase (LOX) converts AA into leukotrienes
11. Lacrosse players: leukotrienes LTB4, C4, D4, and #4, are important regulators of inflammation
12. B4 attractant first responders: LTB4 is a chemoattractant for inflammatory cells (neutrophils)
13. First responders: neutrophils
14. Constricted lacrosse stick bronchi: LTC4, D4, andE4, increase airway vascular permeability, mucus production, and bronchoconstriction
15. Lacrosse goal CysLT1: receptor for LTD4 (most potent bronchoconstrictor)
16. Monte the broadcaster: "-Kast" suffix of LTD4-receptor antagonists (montelukast, zafirlukast)
17. Blocked D4 shot: LTD4-receptor antagonists (montelukast, zafirlukast) are an alternative therapy for mild persistent asthma
18. Dilated scarf: LTD4-receptor antagonists cause bronchodilation
19. Open mouth: LTD4-receptor antagonists are taken orally
20. **Godzilla falling on coach LOX: zileuton** (a direct lipoxygenase inhibitor) is an alternative therapy for mild persistent asthma
21. Liver spot: zileuton has a risk of hepatoxicity
22. ASA umpire grabbing coach COX: inhibition of COX shifts the AA metabolism to the LOX leukotriene pathway (exaggerated in aspirin-induced asthma)
23. Salute formation: salmeterol and formoterol (long acting beta 2 agonists) treat moderate or severe persistent asthma
24. Long tapering flag: salmeterol and formoterol (beta 2 agonists) have a long duration of action
25. Inhaler: Long acting beta 2 agonists (salmeterol, formoterol) are administered as a daily controller inhaler
26. Higher glucocorticoid moon face: an increased dose of inhaled corticosteroid treats moderate or severe persistent asthma
27. Xanthine energy drink: methylxanthines (theophylline) are an alternative therapy for mild to severe persistent asthma
28. **"flyin": theophylline (a methylxanthine)**
29. Caffeine: methylxanthines are related to caffeine
30. Don't phoster disinterest: methylxanthines (theophylline) are phosphodiesterase inhibitors
31. "Camping": methylxanthines increase cAMP
32. Open mouth: theophylline is administered orally
33. <u>Adverse effects</u>
34. Shaking kid: methylxanthies (theophylline) have CNS side effects including nervousness and tremor
35. Holding up heart watch: methylxanthines (theophylline) can cause tachycardia
36. Chrome bumper hitting energy drinks: methylxanthines (theophylline) are metabolized by the cytochrome P-450 system
37. Bee hive: mast cell degranulation is important to the pathogenesis of asthma
38. IgE gun shooting hive: antigen binding to Fc portion of IgE on mast cells causes degranulation and release of inflammatory mediators (histamines)
39.



40. **Limousine: omalizumabe** (an anti-IgE monoclonal antibody) is an adjunctive therapy for moderate or severe persistent asthma
41. grabbing end of IgE gun Omalizumab is a monoclonal antibody directed against the Fc portion of IgE, preventing mast cell sensitization
42. **Lynn's bee control: chromolyn sodium**
43. Bee sedating smoke: cromolyn sulfate inhibits mast cell degranulation (preventing release of histamine)
44. **IN THE EMERGENT SITUATION**
45. Beta 2 tuba: inhaled short-short acting beta 2 agonists (albuterol) treat an acute severe asthma exacerbation
46. Floating moon face caterpillar:" Systemic corticosteroids treat acute severe asthma exacerbation
47. Ivy: corticosteroids are administered IV or orally during acute severe asthma exacerbation
48. Cat-IPRA-pilar: nebulized IPRAtroprium bromide (antichlinergic) can be added to treat an acute severe asthma exacerbation
49. Epic: subcutaneous or intramuscular epinephrine can be used to treat an acute severe asthma exacerbation



Antiemetic agents: Odansetron, metoclopramide, H1 receptor agonists, Scopolamine, aprepitant

1. Solitary track runner: the nucleus tractus solitaries (NTS, or vomiting center) located in the medulla, receives inputs from the GI tract, vestibular system, and area postremia
2. Vomiting on track: the NTS projects neurons to other medullary nuclei to coordinate the vomiting response
3. Stomach hammer throw area: The GI tract blood barrier (bb) directly with the NTS (via CN X)
4. Vegas sign at the stomach area: vagal afferents from the GI tract communicate with the NTS
5. Smiley hammer at the stomach area: GI irritation (due to infection, chemotherapy, distension) causes mucosal serotonin release
6. "1-2-3" Hammer Throw!": serotonin activates 5HT-3 receptors on the vagal afferents
7. Semicircular canal: the vestibular system communicates directly with the NTS (via CN III)
8. Vests at the semicircular canal: the vestibulocochlear nerve (CN III) from the vestibular system communicates with the NTS
9. Seasick at the canal: the vestibular system is responsible or vertigo and motion sickness (vestibular nausea)
10. Extreme postures on the pommelhorse next to the track: the area postrema (chemoreceptor trigger zone) is located adjacent to the NTS (outside the BBB in the 4th ventricle) and responds to emetogenic substances (chemotherapeutic agents)
11. **Ribbon dancer blocking the hammer throw: Ondansetron** antagonizes 5-HT3 receptor on vagal afferents in the GI tract (treats chemo-induced or post-op vomiting)
12. Hammer tightening gut: ondansetron can cause constipation
13. Hammer hitting head: Ondansetron can cause headache and dizziness
14. Twisted torsade's streamer: ondansetron can prolong the QT interval and induce torsade's
15. Pile of smiley faces: Ondansetron can cause serotonin syndrome (symptoms include rigidity, tremor, hyperthermia, confusion)
16. Allergy inducing, Q shaped dandelions: the vestibular system contains H1 histamine receptors (coupled to Gq)
17. **Bee swatters: 1st generation H1 receptor blockers** (diphenhydramine, Meclizine) treat vestibular nausea (motion sickness)
18. M1 motorcycle parking: the vestibular system contains M1 muscarinic receptors
19. **Telescope: scopolamine** (muscarinic agonist) treats vestibular nausea (motion sickness)
20. Seasick Sailor outfits: motion sickness (vestibular nausea) is treated with 1st generation H1 antagonists (diphenhydramine) and scopolamine
21. Extreme posture 2 D-Ring ropes: the area postrema contains D2 receptors
22. **Tickler blocking the D-rings: metoclopramide** antagonizes D2 receptors in the area postrema (treats chemotherapy induced vomiting)
23. Contracted stomach: metoclopramide has upper GI prokinetic effects (increased esophageal peristalsis, decreased lower esophagus sphincter pressure, and enhanced gastric emptying) (useful for treatment of delayed gastric emptying due to post-surgical disorders and diabetic gastroparesis)
24. "Do not obstruct": metoclopramide (D2 Antagonist) is contraindicated in small bowel obstruction
25. Adverse effects
26. Mud puddle: metoclopramide can cause diarrhea (prokinetic effects)
27. Sleeping judge: Metoclopramide can cause drowsiness, especially in the elderly
28. Crying coach: metoclopramide can cause depression (central D2 blockade)
29. EXTRA pyramidal newspaper hat: metoclopramide can cause extrapyramidal effects due to central D2 blockade (dystonia, akathisia, parkinsonian features)
30. Sticking out tongue: metoclopramide can cause tardive dyskinesia with chronic use (central D2 blockade), especially in the elderly
31.



32. **N**ow **M**ore **S**picy chicken: metoclopramide (D2 agonist) can cause **neuroleptic malignant syndrome** (symptoms include fever, rigidity, mental status changes, autonomic instability, rhabdomyolysis)
33. Elevated milk release: metoclopramide can cause elevated prolactin levels (central D2 blockade), leading to gynecomastia, amenorrhea, and decreased sexual drive
34. Twisted torsade's streamer: metoclopramide can cause QT prolongation and induce torsade's
35. plaNK1 pommel horse: the area postrema contains neurokinin 1 (NK1) receptors (activated by substance P)
36. Substance Pee check: substance P binds to the NK1 receptors in the area postrema
37. "participants": aprepitant antagonizes the NK1 receptors in the area postrema (treats chemotherapy induced vomiting), the "a preppy aunt" is a better mnemonic

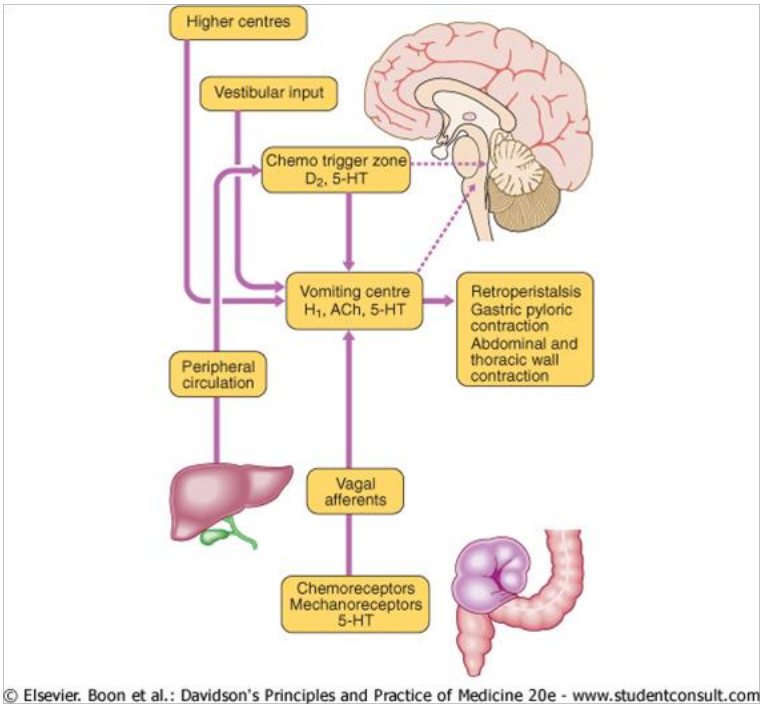



H2 Receptors: PPI's

1. "pour it all": parietal cells in the gastric mucosa are responsible for acid secretion
2. Battery powered puree pump: H+/K+ ATPase (proton pump) on the luminal membrane pumps H+ into the lumen
3. Banana into the pump, lemons out: the H+/K+ ATPase exchanges one K+ for one H+ at the luminal membrane
4. Sidewalk: lumen of the stomach
5. Three P batters: ATPase driven process
6. Bees swarming honey pot: histamine (released by the ECL cell) activates H2 receptors on the parietal cell
7. Honey pot with 2 "S" handles: H2 histamine receptors (coupled to Gs to increase cAMP) on the basolateral membrane
8. Honey pot kid knocking over acid pitcher: activation of H2 receptors upregulates the H+/K+ ATPase → increased acid secretion
9. Enter CarefuLly: enterochromaffin –like (ECL) cells
10. Bees released from ECL tree: the ECL cell releases histamine (activates the parietal cells)
11. Gas Powered blower releasing bees from ECL tree: gastrin (released by G cells) stimulates the ECL Cell to release histamine
12. Gas truck releasing gas tanks: G cells release gastrin (Which stimulates ECL and parietal cells)
13. Gas powered acid pump: gastrin (released by G cells) stimulates the parietal cell to secrete H+ (minor effect) gastrin's major effect is release of Histamine from ECL cells
14. Motorcycle attached to stand in M3: M3 acetylcholine receptors are located on the parietal cell
15. Vegas sticker: vagal stimulation stimulates the parietal by the vagus nerve (M3 receptor)
16. Vegas Sticker: vagal stimulation stimulates the G cell to release gastrin (VIA GRP)
17. Gate release pull: gastrin releasing peptide (GRP) from the vagus nerve activates G Cells
18. **2 bee swatters: H2 histamine receptor antagonists** (ranitidine, cimetidine) inhibit acid secretion by parietal cells
19.
20. Tie dye t shirt: "-tidine" suffix of H2 receptor antagonists (ranitidine, cimetidine, famotidine, nizatidine) @ antagonists reduce the acid secretion that is mediated by histamine, this comes from the enterocrhomaffin like cell, this cell is initially by gastrin by the G cell, which is brought on by vagal stimulation. So H2 blockers work with Histamine, gastrin, and Vagal stimulation. But Vagal stimulation will also stimulate the parietal cell directly to secrete acid. H2 blockers are used at night to prevent nocturnal secretion of acid that is largely dependent on histamine, but only a modest effect on meal stimulation because vagus nerve will stimulate Parietal cells directly
21. Gargling: H2 blockers (ranitidine, cimetidine) treat GERD (PPI's are first line)
22. Ulcerated sidewalk: H2 blockers (ranitidine, cimetidine) treat duodenal ulcers (PPI's are first line)
23. **Tie dye kid on the cement: cimetidine** (H2 blocker with antiandrogenic side effects)
24. Dented chrome bumper: Cimetidine inhibits cytochrome P-450
25. Pot lids on chest: cimetidine can cause gynecomastia when used long term or in high doses
26. Droopy honey wand: cimetidine can cause impotence
27. Milk shooting from nose: cimetidine can cause elevated serum prolactin levels
28. **Girl scout blocking puree pump: Proton Pump Inhibitors** (PPI's) irreversibly inhibit the H+/K+ ATPase (the final common pathway for H+ secretion)
29. PRIZE: "-prazole" suffix of PPI's (omeprazole, lansoprazole, rabeprazole)
30. Gargling: H2 blockerrs (ranitidine, cimetidine) treat GERD but PPI's are the first line
31. Ulcerated sidewalk: PPI's provide faster symptom relief for gastric and duodenal ulcers
32. Jumbo gas tank on mower with crab logo: gastrinoma causing hypersecretion of gastric acid (Zollinger-Ellison syndrome – treat with PPI's)
33.



34. Swarm of bees over lawn mower: extra gastrin will stimulate parietal cell directly with increasing Histamine, PPI's are the best medical treatment
35. Helicopter hat: PPI's treat H.Pylori infection, with clarithromycin or amoxicillin/metronidazole
36. Adverse effects
37. Chocolate fondue fountain: PPI's increase the risk for C.Diff infection
38. Dirty lung spots: PPI's increase the risk for respiratory infections (pneumonia)
39. Medals bound to wagon: PPI's decrease the absorption of Ca2+, Mg2+, and Fe2+ (requires acidic environment)
40. Fractured Axel: PPI's increase the risk of osteoporotic hip fractures (due to decreased Ca2+ absorption)
41. Porous wood: PPI's may worsen osteoporosis (due to decreased Ca2+ absorption)
42. Falling magnets on girl scout: PPI's can cause hypomagnesia
43. **Stop sign: Somatostatin** inhibits release of histamine by ECL cells
44. Stop sign: Somatostatin (SST) inhibits the release of gastrin by G cells (and SST receptor positive gastrinomas)
45. **Octagon shape of stop sign: octreotide** (a long acting SST analog) inhibits ECL production
46. Octagon: octreotide (a long acting SST analog) inhibits G cells (useful in the treatment of gastrinoma/Zollinger Ellison syndrome

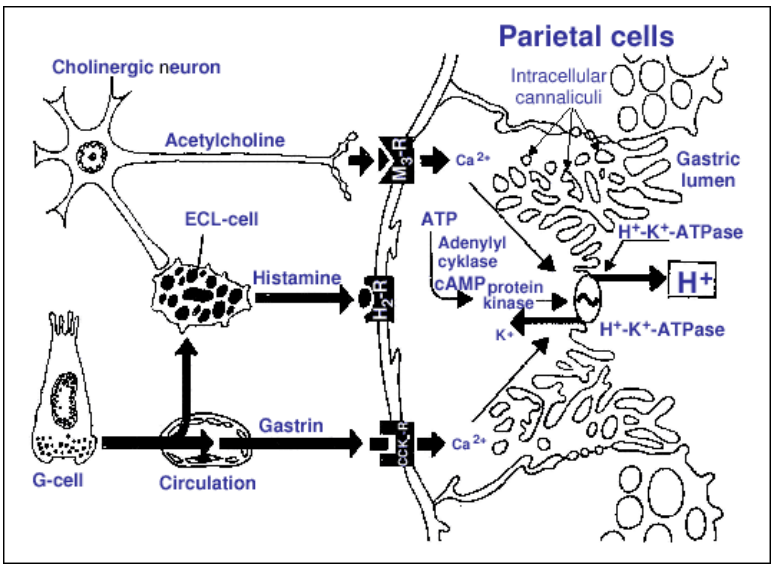



Laxatives and anti-diarrheal agents

1. Spa water: osmotic laxatives (magnesium compounds, lactulose, polyethylene glycol) are non-absorbable substances that draw water into the intestinal lumen → distension → peristalsis
2. Magnets: magnesium compounds (magnesium hydroxide (milk of magnesia), magnesium citrate) are osmotic laxatives
3. PEG drain cover: polyethylene glycol (PEG) is an osmotic laxative (non absorbable sugar), commonly is iso electrolytic so not to draw electrolytes into the lumen
4. Relaxulose: lactulose is an osmotic laxative (non absorbable sugar) sever flatus and cramps may be AE's
5. Relaxulose into the liver and brain coral tank: lactulose is useful in the treatment of hepatic encephalopathy
6. Cirrhotic liver and brain coral: hepatic encephalopathy (a neurologic complication of cirrhosis due to the buildup of ammonia and other toxins) as ammonia gets shunted past the liver and ends up in the brain, leads to the rhythmic flapping of hands (asterixs)
7. Fish eating lactulose: intestinal bacteria metabolize lactulose into acidic metabolites
8. Acidic pH meter: acidic metabolites decrease the pH of the intestinal lumen
9. Worker on the NH4+ release valve carrying the ammonia bottle: ammonia (NH3) is trapped as ammonium (NH4+) in the acidic lumen and excreted
10. **Fisherman removing fish: rifaximin** (a poorly absorbed antibiotic) eradicates ammonia producing intestinal bacteria (treats hepatic encephalopathy)
11. Spoiling mud bath: laxatives can cause diarrhea and dehydration
12. **Bulky seaweed outside of the shop:** psyllium is a bulk forming laxative (indigestible hydrophilic colloid → absorbs water → distension → peristalsis)
13. **Water penetrating a canoe at the DOCK: docusate** is a stool softener (surfactant agent that facilitates penetration pf stool by water and lipids)
14. Stimulating suntan lotion: senna is a stimulant laxative a.k.a cathartic (stimulation of enteric nervous system and colonic secretions)
15. Brown gut: chronic use of senna causes melanosis coli (brown pigmentation of the colon)
16. Muddy slippers left outside: antidiarrheal agents (featured in massage room)
17. Utopia: Opiate agonists (diphenoxylate, loperamide) treat diarrhea
18. MUssage: opioids treat diarrhea by activating mu-opioid receptors in the GI tract
19. **Lop-eared rabbit: Loperamide** treats diarrhea (mu-opioid agonist that does not cross the BBB → no analgesia or potential for addiction)
20. Lop eared rabbit hopping back and forth: opioid agonists (loperamide) increase colonic phasic segmenting activity → increased colonic transit time
21. **Dolphins: Diphenoxylate** treats diarrhea (mu-opioid agonist with some ability to cross the BBB → combines with atropine to prevent abuse)
22. Red stool and inflammatory candles outside door: antidiarrheal agents are contraindicated in patients with bloody diarrhea or fever (treat the underlying cause)
23. Clogged: opioids can cause constipation
24. VIP CUSTOMERS only crab: VIPoma and carcinoid tumor cause secretory diarrhea, pancreatic endocrine tumor secreting VIP
25. STOP sign: Octreotide treats the symptoms of VIPoma and carcinoid syndrome (secretory diarrhea)



Diabetes: insulin, sulfonylureas, meglitinides, GLP-1 agonists, DPP-4 inhibitors (type I on this page)

1. Welcome inside mat: insulin (the storage and anabolic hormone of the body)
2. LangerHansel: islets of Langerhans in the pancreas (the site of beta cells in the pancreas)
3. Beta 2 tuba: pancreatic beta cells produce insulin (stimulated by many factors including glucose and sympathetic activation of beta 2 receptors)
4. Langerhansel candy: glucose – the most potent stimulant of glucose secretion
5. Closed gate around banana candy flowers: glucose increases ATP levels in the beta cell → ATP dependent K+ → channels close
6. Gretel rushing in on the calci-yum ice cream flower: closing the ATP dependent K+ channels causes the beta cell to depolarize → voltage gated Ca2+ channels open → Ca2+ INFLUX → insulin secretion
7. Candy wrapper on the ground: C-Peptide (cleaved from proinsulin in the secretory granule) is released with endogenous secretion of insulin
8. Tyrosine tire swing: the insulin receptor contains an intracellular tyrosine kinase domain, this sets off a cascade of phosphorylation events eventually leading to glucose transporters being added to the cell membrane
9. 4 on the open door: insulin inserts glucose transporter type 4 (GLUT4) into the membrane of peripheral tissues (adipose and muscle)
10. Full liver candy jar: insulin increase hepatic glycogen stores (increased glycogenesis, decreased glycogenolysis)
11. Glycogen glazed ham: insulin increases glycogen storage and protein synthesis in muscle
12. Full fatty donut jar: increases triglyceride storage in adipocytes
13. Old lady Eating banana candy: insulin decreases serum K+ (increased Na+/K+ ATPaase in skeletal muscle drives K+ into the cells)
14. **Girls and Lads**: Insulin Glusine, Aspart, Lispro (rapid acting, short duration) these do not polymerize into hexamers so they are absorbed rapidly
15. Tall immediate peak on "girls and Lads": Insulin glusine, aspart, and Lispro have rapid onset and short duration of action, mimicking post prandial response.
16. Birds nibbling the peak: insulin glusine, aspart, and lispro control the postprandial glucose spike
17. **Rest Now: regular insulin and NPH** (neutral protamine Hagedorn) Intermediate acting
18. Delayed peak on the house: regular and NPH insulin have a delayed onset and intermediate duration of action (NPH is more delayed) this is due to the formation of dimers and hexamers, taking time to breakdown
19. Ivy under "R": Regular insulin is only one to be administered IV
20. Candy Cane Key: Diabetic Keto Acidosis (DKA – Presents with vomiting, Fatigue, Polyuria)
21. Ivy next to candy key: IV regular insulin is useful in the management of DKA (watch K+ levels)
22. Ivy next to eaten banana: IV regular insulin is useful in the management of hyperkalemia (administer with glucose!)
23. **Rest Now: regular insulin and NPH** (neutral protamine Hagedorn) Intermediate acting
24. Delayed Peak: : regular and NPH insulin have a delayed onset and intermediate duration of action (NPH is more delayed) this is due to the formation of dimers and hexamers, taking time to breakdown, NPH is not used much clinically
25. **Don't Go: insulin Detemir, Glargine (long acting)**
26. Roof on hat is long and flat: Insulin detemir and glargine have long durations of action and provide a steady background level of insulin (glargine has no peak)
27. Falling candy: insulin therapy can cause hypoglycemia (presents with tachycardia, palpitations, sweating, nausea)
28. Glucagone for when your glucose is gone!



Type II diabetics

1. **Sulfa egg laying swan: sulfonylureas (glyburide, glipizide)** are sulfa drugs that stimulate endogenous insulin release from beta cells
2. Sulfa swan lake behind closed banana gate: sulfonureas bind the ATP-dependent K+ channels on beta cells → leading to depolarization of beta cells → calcium influx → release of endogenous insulin
3. **Mother swan in a maid outfit: "-amide"** suffix of first generation sulfonureas **(tolbutamide, chloropropramide)** long duration of action, rarely used)
4. **Goslings riding on the mother swan's back: "-ride" suffix** of second generation sulfonureas **(glyburide, glimepiride)** smaller dosing, long duration of action
5. **Short zig-zagging gosling: glipizide (2nd generation sulfonurea**) has the shortest duration of action (less risk of hypoglycemia)
6. **Father goose gliding into the scene: "glinide" suffix of the meglitinides (repaglinide, nateglinide**) MOA similar to sulfonureas sulfonureas bind the ATP-dependent K+ channels on beta cells → leading to depolarization of beta cells → calcium influx → release of endogenous insulin)
7. Candy wrapper on the ground: C-Peptide (cleaved from proinsulin in the secretory granule) is released with endogenous secretion of insulin
8. Father goose cannot lay eggs: meglitinides (glinides) are NOT sulfa drugs (can be used in patients with an allergy to sulfa)
9. Falling candy: sulfonurease and meglitinides can cause hypoglycemia
10. Fat old hag: sulfonureas and meglitinides can cause weight gain
11. "Do not drink" next to mother sulfonurea swan: some 1st generation sulfonureas (cloropramide) cause a disulfuram like reaction with ingestion of alcohol
12. These need functional beta cells in order to work
13. 2 fingers: sulfonureas and meglitinides (glinides) are oral agents used in the treatment of TYPE 2 diabetes requiring functional beta cells for endogenous insulin release
14. **ExenaTIDE detergent: "-tide" suffix of GLP-1 agonists (exenatide, liraglutide)**
15. Langerhansel "Gulp" activated when looking at Hag: GLP-1 agonists (exenatide, liraglutide) activate the Glucagon Like Peptide Receptor (GLP-1) (increased insulin release and satiety, decreasing glucagon release and gastric emptying)
16. **4 DRIPPNG laundry items hanging: Dipeptidyl peptidase (DPP-4) inhibitors (gliptins) prevent the breakdown of GLP-1**
17. Clipped in clothespins: "-gliptin" suffix of the DPP-4 inhibitors (stigaliptin, saxagliptin, linagliptin)
18. Laundering old hag letting out endogenous gulps: DPP-4 inhibitors (gliptins) increase levels of endogenously secreted GLP-1 (increased insulin release and satiety, decreased glucagon release and gastric emptying)
19. Falling empty glucagon packets: GLP-1 agonists and DDP-4 inhibitors decrease glucagon secretion this aids in lowering serum glucose levels
20. Sealed gastric container: GLP-1 and DDP-4 inhibitors decrease gastric emptying leading to increase satiety and delayed glucose absorption
21. Clothespin clipping nose: DPP-4 inhibitors (gliptins) can increase risk for upper respiratory infections an nasopharangyiis
22. Creping detergent lady Squeezing pancreas sponge: GLP-1 agonists (exenatide) can cause pancreatitis, seek immediate medical care
23. Green candies NOT falling off the tree: GLP-1 agonists and DPP-4 inhibitors do NOT cause hypoglycemia
24. 2 fingers: GLP-1 and DPP-4 inhibitors are oral agents used in the treatment of TYPE 2 diabetes requiring functional beta cells for endogenous insulin release
25. C-Wrapper: GLP-1 agonists and DPP-4 inhibitors increase endogenous insulin release and C-Peptide levels



Metformin, Rosiglitazone, pioglitazone, pramlintide, canagflozin, acarbose, miglitol

1. 2nd grade: these agents are used in the treatment of type II diabetics (require functional beta cells for endogenous insulin release)
2. **Skinny Kid on his knee saying a metaphor: Metformin** (a biguanide) is the first line oral agent for the management of type II diabetes
3. Girl eating the mitochondrial candy then puking: metformin inhibits the mitochondrial enzyme glycerophosphate dehydrogenase (mGDP) → decreasing hepatic gluconeogenesis
4. AMPKandy: metformin activates the enzyme AMP-activated protein Kinase (AMPK) → decreased gluconeogenesis, increased insulin sensitivity
5. Girl stopping candy release from liver bag: metformin modulates enzyme function to decrease hepatic gluconeogenesis
6. INSIDE open candy box: Metformin increases insulin sensitivity (valentines mailbox is to simulate "welcome inside" mat
7. Spilled sour milk: metformin can cause lactic acidosis. This is due to metformin inhibiting lactic acid ability to enter gluconeogenic pathways into the liver
8. Cracked kidney tray: renal insufficiency increases the risk of metformin induced lactic acidosis
9. Nauseated: most common side effect with metformin use is GI side effects (nausea, anorexia, vomiting, diarrhea)
10. Skinny kid: metformin can cause modest weight reduction
11. **Glitter: "-glitazone" suffix of the thiazolidinedione's** (glitazones –rosiglitazone, pioglitazone) work to increase by increase glucose utilization and decreasing glucose production
12. PPARy in circle: thiazolidinedione (glitazones) are ligands of peroxisome proliferator activated receptor gamma (PPARy) an intracellular nuclear receptor that regulates gene transcription causing increased insulin sensitivity, found in muscle, fat, and the liver
13. Turtle neck: PPAR-y upregulates adiponectin (increased insulin sensitivity and fatty acid oxidation)
14. Elevated fatty donut jar: thiazolidinedione (glitazones) increase the differentiation and number of adipocytes
15. Eating Fatty donut: thiazolidinedione's (glitazones) increase triglyceride storage and fatty acid oxidation → decreased serum triglycerides
16. 4 an open door: thiazolidinedione's (glitazones) upregulate GLUT4 in peripheral tissues (increased glucose uptake)
17. Inside open candy box: thiazolidinedione's (glitazones) increase insulin sensitivity
18. Takes days to weeks after therapy to get a response
19. Fat belly on PPAR-y kid: thiazolidinedione (glitazones) can cause weight gain
20. Baggy pants on PPAR-y kid: thiazolidinediones (glitazones) can cause fluid retention and peripheral edema, and decompensation of CHF
21. Falling heart balloon: thizolidinediones (glitazones) induced fluid retention can exacerbate heart failure
22. Fractured chair leg: thiazolidinediones (glitazones) can increase the risk of atypical extremity fractures in women (due to decreased bone mineral density)
23. **Amy and Lynn: Amylin** (islet amyloid polypeptide) analogues (pramlintide) a (decreased glucagon, gastric emptying, and appetite) drug
24. Closed gastric water cooler: amylin analogues (pramlintide) decrease gastric emptying
25. Falling empty glucagon packets: amylin analogues decrease glucagon secretion
26. 1 and 2 fingers being held up by Amy and Lynn: amylin analogues can be useful in the management of type I and type II diabetes
27. Eaten cupcake: amylin analogues can be used to control the postprandial glucose spike
28. Fallin candy: pramlintide can cause hypoglycemia
29. Nauseated: pramlintide can cause GI side effects (N&V, anorexia)
30.



31. **A-Carb wigglers: acarbose and miglitol** (alpha-glucocidase inhibitors)
32. "monosaccharide free": inhibition of alpha-glucosidase enzymes decreases the conversion of disaccharides into absorbable monosaccharides
33. Brush border flags: alpha-glucosidase inhibitors decrease the activity of disaccharides on the intestinal brush border
34. Kid can't open the bag, delayed bag opening: alpha-glucosidase inhibitors delay carbohydrate absorption
35. Eaten cupcake: alpha-glucosidase inhibitors can be used to control post prandial glucose spike
36. Leaky bathroom puddle: alpha-glucosidease inhibitors can cause GI side effects (diarrhea, flatulence, abdominal pain) due to fermentation of the undigested carbs by the gut flora
37. **Flossing: "-flozin" suffix of the SGLT2 inhibitors** (canigflozin, dapagflozin) 2nd or third line drug
38. Salty Glucose Co.: sodium glucose cotransporter 2 (SGLT2 reabsorbs glucose in the proximal tubule (inhibition leads to urinary glucose loss)
39. Pro Cart Track: Proximal convoluted tubule of the nephron (site of activation of SGLT2)
40. Bladder cup: SGLT2 inhibitors can increase the risk of UTI due to increased urine glucose concentration
41. Snow hitting crotch: SGLT2 inhibitors can increase the risk of vaginal candidiasis (Corey the Canadian flag)
42. Fainting kid in the blue: SGLT2 inhibitors can cause hypotension due to osmotic diuresis
43. Cracked kidney tray: SGLT2 inhibitors are contraindicated in renal insufficiency
44.



Osteoporosis drugs: Bisphosphonates: raloxifene: calcitonin: denosumab

1. Fresh piece of calcified chalk: Bisphosphonates, SERMs, denosumab, and calcitonin are useful in the treatment of osteoporosis (inhibit bone resorption → modest increase in bone mineral density and decreased fracture risk)
2. Osteo-builders: osteoblasts
3. Destructive class: osteoclasts
4. **DONATE: "-Dronate" suffix of bisphosphonates** (alendronate, pamidronate, zoledronate), the first line treatment for osteoporosis
5. Two P coins: bisphosphonates have a chemical structure similar to pyrophosphate
6. Large T-Rex appetite: bisphosphonates attach to hydroxyapatite in the bone
7. Classmate stuck in donation box: osteoclasts bind to the bisphosphonate, inhibiting their adherence to the bony surface
8. Class waiting to enter: osteoclast precursors
9. Preventing class from entering: bisphosphonates decrease the development and recruitment of osteoclast precursors
10. Classmates popping balloon: bisphosphonates induce osteoclast apoptosis
11. Elevated calci-yum ice cream: bisphosphonates are useful in the acute treatment of hypercalemia
12. Massive calcified rock with metastatic crab fossils: hypercalcemia of malignancy is a common cause of severe hypercalcemia requiring acute treatment (with bisphosphonates and calcitonin)
13. Disorganized bone homo paget display: bisphosphonates and calcitonin are useful in the management of pagets disease (uncontrolled osteoclast resorption with secondary disorganized bone formation)
14. Corroded neck on dinosaur: bisphonates can cause upper GI side effect (acid reflux, esophagitis, esophageal ulcers) sit upright 30 min and drink water to treat
15. Crumbling jaw bone: bisphosphonates can cause osteonecrosis of the jaw
16. Falling calci-yum ice cream: bisphosphonates can cause hypocalcemia
17. Female symbol: estrogen therapy can treat and prevent postmenopausal osteoporosis (not recommended due to increased risk of breast cancer and other side effects) estrogen therapy will inhibit osteoclast differentiation.
18. Female guarding class entrance: estrogen inhibits differentiation of osteoclast precursors
19. **Relax: raloxifene** (a selective estrogen receptor modulator SERM) is useful in the treatment and prevention of postmenopausal osteoporosis
20. Relaxing the waiting classmates: raloxifene has estrogen agonist activity in bone (inhibits osteoclast differentiation) and estrogen antagonist activity in breast and uterus (reduced risk of breast cancer)
21. **PthD: parathyroid hormone (PTH)**
22. Convincing osteo-builder to give crank drill: PTH stimulates osteoblasts to express RankL
23. Crank drill: receptor activator of nuclear factor kappaB ligand (RANKL)
24. Active classmate with crank drill: RankL binds to RANK on the osteoclast, increasing its activity
25. Dino suit man grabbing crank drill: denosumab (monoclonal antibody against RANKL) is useful in the treatment of osteoporosis
26. Antibody spikes: denosumab is a monoclonal antibody
27. **Curator toning it down: calcitonin** ("tones down calcium) has some utility in the treatment of osteoporosis, released from the parafolicular cells of the
28. Curator grabbing classmate: calcitonin inhibits osteoclasts → decreased bone resorption
29. Calci-Yum ice cream pouring down flank: calcitonin promotes Ca2+ excretion by the kidney
30. Used in the same clinical scenarios as bisphosphonates but not 1st line
31. Massive calcified rock with crab fossils: hypercalcemia or malignancy is a common cause of sever hypercalcemia requiring acute treatment with bisphosphonates and calcitonin
32. Falling calci-yum ice cream: calcitonin can cause hypo calcemia



3.1 - Propylthiouracil, methimazole, levothyroxine

1. Evil follicu-LAIR: thyroid follicular cell (site of iodine uptake and thyroid hormone production)
2. Salty sodium peanuts entering lair: sodium enters thyroid follicular cell through the sodium-iodide symporter
3. Iodide vial smuggled in with salty peanuts: the sodium-iodide symporter concentrates iodide in the follicular cell
4. Follicu-LAIR truck lumen: thyroid follicle lumen (site of iodide storage as thyroglobulin)
5. TransPOrter: thyroid peroxidase (TPO - enzyme involved in iodide oxidation and organification)
6. Rusty oxidized transport truck: TPO oxidizes iodide into iodine
7. “Thyro-global” truck: thyroglobulin (tyrosine rich protein precursor to thyroid hormones located in the follicular lumen)
8. Organic foods transporter truck: TPO facilitates iodine organification (iodination of tyrosine residues on thyroglobulin)
9. Coupled tyres of transport truck: TPO facilitates coupling of iodinated tyrosine residues
10. Time bomb prep table in the follicu-LAIR: thyroid hormones (T4 and T3) are cleaved from thyroglobulin in the follicular cell (T4 in greater quantities)
11. T4 time bomb: tetraiodothyronine (thyroxine, T4)
12. T3 time bomb: triiodothyronine (T3) is the more potent form of thyroid hormone
13. T4 detonator in the periphery: 5’ deiodinase in the peripheral tissues converts T4 to T3
14. Sensitive to catfish: thyroid hormone increases the sensitivity of peripheral tissues to catecholamines (increased number of beta-adrenergic receptors)
15. Anxious henchman with big bowtie: hyperthyroidism is associated with hypermetabolic and hyperadrenergic symptoms (e.g. tachycardia, palpitations, insomnia, anxiety, tremor, heat intolerance, weight loss)
16. Bulging infrared goggles: Grave’s ophthalmopathy (increased volume of retroorbital connective tissue, due to cellular proliferation, inflammation, and the accumulation of glycosaminoglycans) → exophthalmos
17. Radioactive vial: hyperthyroidism due to Graves' disease can be treated with ablating doses of radioactive iodine (131-I)
18. Undone bowtie: radioactive iodine treatment can cause hypothyroidism
19. Anxious radioactive henchman: radioactive iodine treatment can exacerbate HYPERthyroidism
20. Bulging radioactive goggles: radioactive iodine treatment can exacerbate Grave’s ophthalmopathy
21. “PTU!” agent firing at the transporter: propylthiouracil (PTU - a thionamide) treats hyperthyroidism by inhibiting TPO
22. Evil math equations striking transporter: methimazole (thionamide) treats hyperthyroidism by inhibiting TPO
23. “PTU!” agent firing at the bomb trigger: PTU treats hyperthyroidism by inhibiting 5’ deiodinase → decreased conversion of T4 into T3
24. Silenced bugle gun pointed at catfish tank: beta blockers treat the hyperadrenergic symptoms of hyperthyroidism
25. Silenced bugle gun pointed at trigger: beta blockers treat hyperthyroidism by inhibiting 5’ deiodinase → decreased conversion of T4 into T3



3.1 - Propylthiouracil, methimazole, levothyroxine

26. Moon face death coaster blocking trigger: glucocorticoids treats hyperthyroidism by inhibiting 5' deiodinase → decreased conversion of T4 into T3
27. Moon face death coaster hitting goggles: glucocorticoids treat Grave's ophthalmopathy
28. Thwarted Dr. Storm: treat thyroid storm by 1) blocking sympathetic effects (beta blockers); 2) blocking thyroid hormone synthesis (PTU); and blocking conversion of T3 to T4 (beta blockers, PTU, glucocorticoids)
29. Broken liver beaker: PTU can cause severe hepatotoxicity
30. Chemical spots: PTU can cause a maculopapular rash
31. Plastic chew bones: PTU and methimazole can cause aplastic anemia
32. Guard wolf: PTU and methimazole can cause drug induced lupus
33. Inflamed leash: PTU can cause ANCA-associated vasculitis
34. Tarantula: methimazole is a first trimester teratogen
35. Fat, cold, fatigued mixologist: hypothyroidism is associated with dry brittle hair, lethargy, fatigue, weakness, decreased BMR, cold intolerance, and myxedema
36. Mixing cold drinks: untreated hypothyroidism can lead to myxedema coma (progressive weakness, stupor, hypothermia, hypoventilation, hypoglycemia, hyponatremia, death)
37. Synthetic T4 time bombs: levothyroxine (synthetic T4) treats hypothyroidism
38. Anxious agent taking cover: levothyroxine therapy can cause HYPERthyroidism
39. Obstructive box of anions: anions such as perchlorate, pertechnetate, and thiocyanate competitively inhibit the sodium-iodide transporter (treat accidental radioactive iodine exposure)
40. Fresh piece of calcified chalk: bisphosphonates, SERMs, denosumab, and calcitonin are useful in the treatment of osteoporosis (inhibit bone resorption → modest increase in bone mineral density and decreased fracture risk)



3.3 - Teriparatide, vitamin D, cinacalcet, sevelamer

1. Osteo-builders: osteoblasts (activated by teriparatide and vitamin D → increase bone mineral density)
2. Destructive classmates: osteoclasts (indirectly activated by teriparatide and vitamin D → increase bone resorption/turnover)
3. Released calcified bones: osteoclasts release calcium from bone
4. Released P fossil: osteoclasts release phosphate from bone
5. PthD paleontologist: parathyroid hormone (PTH)
6. PthD lab: parathyroid gland
7. Calcified bone receiving: calcium-sensing receptor on the parathyroid gland (senses increased serum calcium)
8. PthD stuck behind bones: high serum calcium levels inhibit PTH production and secretion
9. PthD convincing osteo-builder to give up crank-drill: PTH stimulates osteoblasts to release receptor activator of nuclear factor kappa-B ligand (RANKL) → activates osteoclasts
10. Classmate receiving crank-drill: RANKL binds to RANK on the osteoclast surface → increased differentiation and activity → increased bone resorption
11. PthD teaching osteo-builders: PTH stimulates maturation of osteoblasts → increased bone formation (net effect of PTH)
12. PthD gathering bones and dropping P fossils: PTH increases calcium resorption by the kidney (and increases phosphate excretion).
13. 1-head added to Calci-TRON: 1-alpha-hydroxylase in the kidney converts 25-hydroxyvitamin D into 1,25-dihydroxyvitamin D
14. PthD adding final piece to Calci-TRON: PTH increases activity of 1-alpha-hydroxylase in the kidney → increased production of 1,25-dihydroxyvitamin D (calcitriol)
15. PthD teaching assistant (TA): teriparatide (recombinant PTH)
16. TA teaching osteo-builders: intermittent doses of teriparatide stimulates maturation of osteoblasts → increased bone formation
17. Fresh piece of calcified chalk: teriparatide can be used to treat osteoporosis (increase bone density)
18. TA gathering bones and dropping P fossils: teriparatide increases calcium resorption by the kidney (and increases phosphate excretion)
19. TA adding final piece to Calci-TRON: teriparatide increases activity of 1-alpha-hydroxylase in the kidney → increased production of 1,25-dihydroxyvitamin D (calcitriol)
20. Solar D3 battery: vitamin D3 (cholecalciferol) is obtained via dairy products or UVB radiation in sunlight
21. Earth-friendly D2 battery: vitamin D2 (ergocalciferol) is obtained via plants
22. Robot body added to D battery in liver-barrow: 25-hydroxylase in the liver converts vitamin D to 25-hydroxyvitamin D
23. Calci-TRON gathering bones and fossils from dump site: calcitriol stimulates reabsorption of calcium AND phosphate by the kidney
24. Calci-TRON gathering bones and fossils from GI truck: calcitriol stimulates intestinal absorption of calcium AND phosphate
25. Calci-TRONl delivering crank-drills: calcitriol stimulates osteoblasts to release RANKL → activates osteoclasts
26. Calci-TRON collapsing PthD lab: calcitriol inhibits PTH production by the parathyroid gland



3.3 - Teriparatide, vitamin D, cinacalcet, sevelamer

27. Calci-TRON teaching osteo-builders: calcitriol stimulates maturation of osteoblasts → increased bone formation
28. Fresh piece of calcified chalk: calcitriol can be used to treat osteoporosis (increase bone density)
29. Calci-TRON stabilizing rickety tower: vitamin D (e.g. calcitriol) can be used to treat osteoporosis (increase bone density)
30. Calci-TRON stabilizing broken kidney: calcitriol can be useful in chronic kidney disease (prevent hypocalcemia)
31. Scaly knee and elbow pads: topical vitamin D can be used to treat psoriasis
32. Calci-TRON saving falling calcified bones: calcitriol is useful in the long term management of hypocalcemia (e.g. hypothyroidism)
33. Falling PthD: hypocalcemia is commonly caused by hypoparathyroidism (decreased production of calcitriol by the kidney)
34. Undone bowtie on PthD: thyroid surgery can cause hypoparathyroidism and hypocalcemia
35. Shaking structure: hypocalcemia can cause seizure
36. Tense fist: hypocalcemia can cause paresthesias, muscle cramps, trismus, and tetany
37. Raised calci-yum ice cream: teriparatide and vitamin D therapy can cause hypercalcemia
38. Calculator at the calcified bone receptor: cinacalcet (a calcimimetic) activates the calcium sensing receptor on the parathyroid gland → decreased production of PTH
39. Calculating pile of calcified bones: cinacalcet is useful in the treatment of hypercalcemia due to hyperparathyroidism
40. Shoveling fossils in the GI truck: sevelamer (a phosphate binding polymer) decreases absorption of phosphate in the GI trac
41. Shoveling pile of fossils: sevelamer is useful in the treatment of hyperphosphatemia due to chronic kidney disease



Growth hormone: mecasermin: octreotide: pegvisomant

1. **Magic growing beans: Growth hormone** (somatotropin)
2. Front of pituitary sack: GH is secreted from the anterior pituitary
3. Tyrosine tire: the GH receptor is associated with JAK tyrosine kinase "jackin up that cell growth"
4. Growing "welcome INSIDE" mat: insulin-like growth factor (IGF-1) (mediates the growth promoting effects of GH)
5. Tall growing vine: IGF-1 is responsible for long bone growth (pubertal growth spurt) think of a child shooting up just like the vine off the ground
6. Vine sprouting from the Liver rock: GH stimulates the liver to produce IGF-1
7. Striated muscle leaf: GH has anabolic effects in muscle
8. Falling fatty donut jar: GH has catabolic effects in adipose tissue, reduced adiposity, increased muscle mass
9. Short kid: GH therapy is useful in GH deficiency and idiopathic short stature (controversial)
10. Pradre willi: GH therapy is useful for increasing growth in Prader-willi syndrome
11. Turning X girl: GH therapy is useful for increasing growth in turner syndrome, transmittance of a single X chromosome (XO)
12. **Sermon: Mecasermin** (recombinant IGF-1) treats growth failure due to severe IGF-1 deficiency
13. Falling candy: mecasermin (recombinant IGF-1) can cause hypoglycemia
14. Giant: GH secreting pituitary adenoma causes acromegaly in adults and gigantism in children
15. Octagon stop sign: octreotide (somatostatin analog) treats acromegaly and gigantism (inhibit secretion of GH)
16. VIP Customers only: octreotide treats VIPoma (neuroectoderm tumor secreting VIP)
17. Customers only: octreotide treats carcinoid tumors (ileal tumor with hepatic mets secreting serotonin) flushing, wheezing, and secretory diarrhea
18. BIG "welcome inside mat": Octotreotide treats insulinoma (fasting hypoglycemia)
19.
20. Giant glucagon packet: octreotide treats glucagonoma (manifests as weight loss and necrolytic migrator erythema affecting limbs and skin surrounding the lips)
21. Giant gas tank: octreotide treats gastrinoma (Zollinger ellisson syndrome)
22. Exposed variceal pipes: octreotide can control bleeding of esophageal varices (decreased portal blood flow and variceal pressure)
23. Nauseated and pointing up: AE's include GI side effects, N&V, abdominal pain
24. Yellow stool: octreotide can cause steatorrhea (decreased pancreatic secretions and gall bladder contractility)
25. **Burglar with broomstick: cabergoline and bromocriptine** (D2 receptor agonists) treat acromegaly (inhibit secretion of GH from pituitary
26. Double rope ladder: D2 dopamine receptor (activated by cabergoline and bromocriptine)
27. Pituitary sack at the end of the broomstick holding in the beans: reinforcing the inhibition of GH at the pituitary
28. **Ants on a tire swing: pegvisomant** (GH receptor antagonist) treats acromegaly
29.



ADH, Desmopressin (DDAVP), Vasopressin receptor antagonist

1. Collecting duct (CD) – the site of action of antidiuretic hormone (ADH, vasopressin)
2. Hydrating waterboy: antidiuretic hormone (ADH, vasopressin)
3. Posterior water jug: ADH is released from the posterior pituitary
4. V1 hole on the Q shaped green: ADH activates V receptors coupled to Gq (activates PLC → IP3 + DAG → increased intracellular Ca2+)
5. Constricted golfclub: ADH activation of V1 on vascular smooth muscle causes vasoconstriction and increased BP
6. V2 hole on the S shaped green: ADH activates V2 receptors coupled to Gs (activates adenylyl cyclase → increased cAMP)
7. Translocation of pure water: ADH activation of V2 on the basolateral membrane of the CD causes translocation of aquaporin 2 to the apical membrane and reabsorption of free water
8. Endothelial tile: extrarenal V2 receptors are located on the vascular endothelium
9. Von Wille brand pool table: ADH activation of V2 on vascular endothelium causes release of von Willebrand factor (vWF)
10. 8-ball: ADH activation of V2 on vascular endothelium causes release of factor VIII
11. Insipidus fountain: polyuria diabetes insipidus (DI)
12. Dehydrating kidney sand trap: nephrogenic DI
13. Ignoring water boy: nephrogenic DI occurs when the nephron does not respond appropriately to ADH
14. Lift-ium balloons: lithium can cause drug-induced nephrogenic DI
15. Chloro-thighs: thiazide diuretics treat nephrogenic DI
16. Almond cart: amiloride (a K+ sparing diuretic treats nephrogenic DI)
17. Falling lift-ium balloon man: amiloride treats lithium induced DI (blocks Li+ entry into collecting duct cells → increased Li+ clearance)
18. Fire extinguisher: NSAIDs (e.g. indomethacin) treat nephrogenic DI
19. Dehydrating brain sand trap: central DI
20. Absent waterboys: central DI occurs when the pituitary does not release adequate amounts of ADH
21. Waterboy entering exogenously: exogenous administration of ADH treats central DI
22. Desert-mobile: Desmopressin acetate (DDAVP – a long acting synthetic analog of ADH) treats central DI
23. V-2 engine: DDAVP has high specificity for the V2 receptor
24. Scratched von Wille brand felt: DDAVP treats von Willebrand disease (releases vWF from vascular endothelium)



ADH, Desmopressin (DDAVP), Vasopressin receptor antagonist (continued)

25. Bruised with mucosal bleeding: von Willebrand disease (vWD – deficient vWF) can be associated with increased bruisability and muscosal bleeding
26. Missing 8-ball in "A" frame: DDAVP treats hemophilia A (releases factor VIII from vascular endothelium)
27. Bleeding knee joint: hemophilia A (X-linked deficiency of factor VIII) can be associated with hemarthrosis and prolonged bleeding after minor procedures
28. Wet mattress: DDAVP treats nigh enuresis (decreased urine production)
29. Falling salty peanut shells: DDAVP can cause hyponatremia
30. Bulging venous golf clubs: ADH is useful in the management of esophageal variceal bleeding (constricts mesenteric arterioles → reduced portal pressure)
31. Inappropriate water hazard: syndrome of inappropriate ADH (SIADH)
32. Over-hydrating waterboy: SIADH is caused by the overproduction of ADH
33. Vaporizer: "-vaptan" suffix of V2 ADH receptor antagonists (e.g. conivaptan, tolvaptan) used to treat SIADH
34. Wet pants: vaptans promote free water excretion (correcting hyponatremia)
35. Elevated peanuts hitting head: vaptans may cause hypernatremia or central pontine myelinolysis (osmotic demyelination syndrome – due to overly rapid correction of Na+)
36. Bicycle: demeclocycline treats SIADH (vaptans are first line)



Glucocorticoids

1. Adrenal cap: cortisol (an endogenous glucocorticoid) is released from the adrenal cortex
2. Moon face: glucocorticoids
3. Moon scepter in outer circle: the glucocorticoid receptor is located in the cytoplasm
4. Activated scepter in inner circle: the activated glucocorticoid receptor enters the nucleus and regulates gene transcription
5. Inhibited pro-slugger bat: glucocorticoids prevent production of inflammatory prostaglandins by COX
6. Inhibited lacrosse stick: glucocorticoids prevent production of inflammatory leukotrienes by LOX
7. Inhibited N-Flame Krossbow: glucocorticoids inhibit NF-KB (transcription factor for proinflammatory cytokines, e.g. IL-2, TNF-alpha)
8. Inhibited T-knight and antibody archer: glucocorticoids prevent activation of T-cells and B-cells (by inhibiting production of proinflammatory cytokines)
9. Blocked adhesion of first responders: glucocorticoids prevent production of neutrophil adhesion molecules → demargination and decreased migration
10. Crowded first responders: demargination of neutrophils causes neutrophilia
11. Falling T-knight, helper T-squire, and antibody archer: glucocorticoids reduce T-cell and B-cell counts
12. Helper T-squire lowest: glucocorticoids are most effective at reducing helper T-cell counts
13. Falling eo-slingshot: glucocorticoids reduce peripheral eosinophil counts
14. Eclipsed inflammatory sun: glucocorticoids are useful for treating inflammatory disorder (e.g. gout, rheumatoid arthritis, asthma, IBD)
15. Cracked antibodies: glucocorticoids are useful for immunosuppressive therapy (e.g. transplant rejection prevention, treatment of autoimmune disorders)
16. Locked welcome inside mat: glucocorticoids cause insulin resistance
17. Liver bag producing candy: glucocorticoids stimulate gluconeogenesis
18. Sugar-filled liver jar: glucocorticoids increase hepatic glycogen storage
19. Cracked moon: adrenal insufficiency (can be due to Addison's disease – primary adrenal insufficiency)
20. Fainted druid: acute adrenal insufficiency can manifest as circulatory shock and death
21. Falling candy: acute adrenal insufficiency can manifest as hypoglycemia
22. Exogenous moon face: exogenous glucocorticoids treat/prevent acute adrenal insufficiency
23. Shriveled adrenal hat: chronic exogenous glucocorticoid use causes adrenal cortical atrophy (secondary adrenal insufficiency)
24. Falling meat: glucocorticoids promote proteolysis
25. Falling fatty donut jar: glucocorticoids promote lipolysis
26. Moon face: moon facies (due to fat deposition)
27. Fat belly: fat redistribution → central adiposity
28. Thin arms: myopathy, muscle wasting, proximal weakness
29. Thin striped fabric: glucocorticoids inhibit fibroblast proliferation → skin thinning, striae, impaired wound healing
30. Fractured osteoporotic altar: glucocorticoids decreased bone mass → osteoporosis, fractures
31. Cracked head: glucocorticoid induced psychosis (hypomania, confusion, hallucinations)
32. Banana peel: glucocorticoids can cause hypoglycemia (due to mineralocorticoid effects)
33. Cane: glucocorticoids can cause immune-suppression
34. Pulmonary cacti: glucocorticoids can cause reactivation of latent infections (e.g. TB)



Benzodiazepines, Flumazenil

1. Ben's diner: benzodiazepines
2. Pam-cakes: "-pam" suffix of benzodiazepines (e.g. diazepam, lorazepam, oxazepam)
3. Fast ox: oxazepam (a short-acting benzodiazepine)
4. "All A.M.": "-olam" suffix of short-acting benzodiazepines (triazolam, alprazolam, midazolam)
5. "Addictive flavor": benzodiazepines have the potential to cause addiction (more common with short-acting agents)
6. Liver spot: benzodiazepines are metabolized by the liver (long acting agents form active metabolites)
7. Cab-A: benzodiazepines bind to an allosteric site on the GABA-A receptor
8. CNS light: benzodiazepines potentiate GABA-A transmission in the CNS
9. "Chlo-Rider": the GABA-A receptor is a chloride channel
10. "Take it easy": GABA (with glycine) is a major inhibitory neurotransmitter in the CNS
11. "open more frequently": benzodiazepines increase the frequency of ion channel opening
12. Alcoholic on Cab-A: alcohol binds the GABA-A receptor at a separate allosteric site
13. Hangover special: benzodiazepines treat alcohol withdrawal
14. Alcohol withdrawal symptoms (8-12 hours) – insomnia, tremulousness, anxiety, autonomic instability
15. Alcohol withdrawal symptoms (48-96 hours) – delirium tremens (fever, disorientation, severe agitation)
16. Long tapering flag: long-acting benzodiazepines (e.g. diazepam, chlordiazepoxide) are useful in the treatment of alcohol withdrawal
17. Ivy: IV administration of benzos is useful for the management of alcohol withdrawal, seizures, and anesthesia
18. Unplugging jackhammer: benzodiazepines treat status epilepticus
19. Sedated customer: IV benzos can be used in general anesthesia (muscle relaxation, amnesia)
20. Lite: IV benzos can induce conscious sedation for minor procedures and surgeries
21. Sleeping customer: benzodiazepines treat insomnia (not first line due to side effect of physical dependence)
22. Crying kid in pajamas: benzodiazepines treat parasomnias in children (e.g. sleepwalking, night terrors)
23. Relaxing chair: benzodiazepines treat spasticity caused by upper motor neuron disorders (e.g. MS, stroke, spinal cord trauma, tetanus)
24. Anxious customer: benzodiazepines treat generalized anxiety disorder (SSRIs and SNRIs are first line)
25. The Scream: benzodiazepines treat panic disorder (SSRIs and SNRIs are first line)
26. All are welcome: benzodiazepines can cause tolerance (downregulation of GABA-A)
27. Question mark hat: benzodiazepines can cause anterograde amnesia (useful during conscious sedation)
28. Disoriented old man: elderly patients are more sensitive to the side effects of benzodiazepines (including somnolence, confusion, disorientation)
29. Unbalanced stack: benzodiazepines can cause central ataxia (causing falls in the elderly)
30. Bee swatter smacking head: benzodiazepines should be avoided with other CNS depressants (e.g. 1st generation antihistamines, alcohol, barbs, neuroleptics)
31. Barbershop next to Cab-A: barbiturates bind the GABA-A receptor at a separate allosteric site
32. Antagonizing fluffy muzzled dog: flumazenil (competitive antagonist at the BZD receptor) reverses benzo induced sedation (but precipitates seizures)



Zolpidem, Zaleplon, Zopiclone, Melatonin

1. 3 Zs: Zolpidem, Zaleplon, esZopiclone (nonbenzodiazepine hypnotics)
2. "Chlo-Rider": the GABA-A receptor is a chloride channel
3. CNS light: benzodiazepines potentiate GABA-A
4. "Take it easy": GABA (with glycine) is a major inhibitory neurotransmitter in the CNS
5. Grabbing same cab handle: nonbenzodiazepine hypnotics and benzos bind to the same allosteric site on GABA-A
6. Alcoholic on Cab-A: alcohol binds the GABA-A receptor at a separate allosteric site
7. Barbershop next to Cab-A: barbiturates bind the GABA-A receptor at a separate allosteric site
8. "fast": zaleplon and zolpidem have a rapid onset of action
9. Quick jump and fall: nonbenzodiazepine hypnotics have a short duration of action
10. Liver spot: zaleplon and zolpidem are rapidly metabolized by the liver
11. Sleeping: nonbenzodiazepine hypnotics treat insomnia
12. "Fall asleep": zaleplon and zolpidem treat sleep onset insomnia (eszopiclone has the longest half life and is effective for both sleep onset and sleep maintenance insomnia)
13. Disoriented old man: elderly patients are more sensitive to the side effects of nonbenzodiazepine hypnotics (e.g. cognitive impairment and delirium)
14. Unbalanced stack: nonbenzodiazepine hypnotics can cause central ataxia (causing falls in the elderly)
15. "Cannot combine with other CoupoNS": avoid use with other CNS depressants
16. Bee swatter smacking head: avoid use with other CNS depressants (e.g. 1st generation antihistamines, alcohol, benzos, barbs)
17. "not tolerated": nonbenzodiazepine hypnotics are less likely to cause tolerance
18. "break bad habits": nonbenzodiazepine hypnotics are less likely to cause withdrawal symptoms and dependence
19. Antagonizing fluffy muzzled dog: flumazenil (competitive antagonist at the BZD receptor) reverses benzo induced sedation (but precipitates seizures)
20. "melt away": melatonin and ramelteon (a melatonin receptor agonist) treat insomnia
21. Dark and light: melatonin receptors maintain circadian rhythm
22. Nucleus above "X": MT1 and MT2 melatonin receptors are located in the suprachiasmatic nucleus of the hypothalamus (activated by ramelteon)
23. Peacefully sleeping elderly: ramelteon has few side effects and are safe in geriatric patients





Barbiturates

1. Cab-A: benzodiazepines bind to an allosteric site on the GABA-A receptor
2. Ben's diner next to Cab-A: benzodiazepines bind the GABA-A receptor at a separate allosteric site
3. Alcoholic on Cab-A: alcohol binds the GABA-A receptor at a separate allosteric site
4. "Chlo-Rider": the GABA-A receptor is a chloride channel
5. CNS light: benzodiazepines potentiate GABA-A
6. "Take it easy": GABA (with glycine) is a major inhibitory neurotransmitter in the CNS
7. "Open longer": barbiturates increase the duration of opening of the GABA-A receptor
8. Long tapering flag: barbiturates have long durations of action ("hangover" effects more common)
9. Intubated customer: IV thiopental can be used for induction of anesthesia
10. Ivy: IV administration of barbiturates is useful for induction of anesthesia (thiopental) and management of seizures (Phenobarbital)
11. "The ol' quick shave": thiopental has a rapid onset and short duration of action (highly lipid soluble)
12. Hair "redistributed" onto arms and belly: plasma levels of thiopental decrease rapidly due to redistribution to skeletal muscle and adipose
13. Decay line: rapid decay of plasma thiopental levels (due to redistribution)
14. Brief peak: rapid accumulation of thiopental in brain tissue and rapid redistribution
15. Growth line: rapid accumulation of thiopental in skeletal muscle and adipose (recovery from anesthesia)
16. Unplugging jackhammer: IV phenobarbital can be used to treat seizures
17. Perm is done!: primidone (a barbiturate used to treat seizures and essential tremor)
18. Tremulous hand: primidone treats essential tremor (first line with propranolol)
19. Fainting: barbiturates can cause hypotension
20. Collapsed heart and lungs: barbiturates can cause profound cardiac and respiratory depression
21. Brain hair dryer: barbiturates can cause severe CNS depression (e.g. coma) and should be avoided in the elderly
22. "All are welcome": chronic barbiturate use leads to tolerance
23. "Addicted": chronic barbiturate use leads to physical dependence
24. Activated chrome bumper: barbiturates (e.g. phenobarbital) are potent inducers of the cytochrome P450 system



Propofol, Etomidate, Ketamine, Barbiturates, Benzodiazepines

1. Ivy: IV anesthetics (e.g. propofol, etomidate, ketamine)
2. "Prospero…fall asleep!": propofol (IV anesthetic for induction and maintenance)
3. "Introducing": propofol can be sued for induction of anesthesia
4. "Maintain": propofol can be used for maintenance of anesthesia
5. Cab-A: propofol and etomidate potentiate chloride current through the GABA-A receptor complex
6. Dilated sleeves and pants: propofol causes profound vasodilation (arterial and venous) → hypotension
7. "Intimidator": etomidate (IV anesthetic for induction)
8. "Introducing": etomidate can be used for induction of anesthesia
9. Stabilized patient: etomidate preserves cardiovascular stability
10. "snaKE TAMINg": ketamine (IV anesthetic for induction)
11. "Introducing": ketamine can be used for induction of anesthesia
12. Hitched nomadic camel: ketamine inhibits the NMDA receptor complex
13. Dissociative trance: ketamine causes "dissociative anesthesia" (eyes remain open with a slow nystagmic gaze)
14. Unpleasant hallucinations: ketamine can cause unpleasant emergence reactions (e.g. vivid colorful dreams, hallucinations, out of body experiences)
15. Stimulated heart cobra: ketamine causes cardiovascular stimulation (e.g. increased blood pressure, heart rate, cardiac output)
16. Ben's diner: benzodiazepines (IV anesthetics used perioperatively)
17. Bowel water pump: benzodiazepines are used for conscious sedation for minor procedures (e.g. colonoscopy)
18. Barber: IV barbiturates (e.g. thiopental)
19. "Introducing": IV barbiturates (e.g. thiopental) can be used for induction of anesthesia
20. "The ol' quick shave": thiopental has a rapid onset and short duration of action (highly lipid soluble)



Nitrous Oxide, Volatile anesthetics

1. Kid inhaling balloon: Inhaled anesthetics
2. "laughing gas": nitrous oxide (N2O – a gaseous anesthetic)
3. Air tank in water: volatile anesthetics (e.g. enflurane, isoflurane, halothane) are liquid at room temperature
4. Balloon flower: volatile anesthetics (e.g. enflurane, isoflurane, halothane) are fluorinated
5. Moving freely in ball pit: highly soluble inhaled anesthetic (e.g. halothane)
6. Impeded by ball pit: less soluble inhaled anesthetic (e.g. N2O)
7. Passed out earlier: less soluble inhaled anesthetics (e.g. N2O) have a faster onset of action
8. Immediate rescue: less soluble inhaled anesthetics (e.g. N2O) have a faster recovery
9. Passed out later: more soluble inhaled anesthetics (e.g. halothane) have a slower onset of action
10. Long tapering flag: more soluble inhaled anesthetics (e.g. halothane) have a longer duration of action
11. Partition>>>: higher blood:gas partition coefficient (e.g. halothane) → higher solubility → slower onset of action
12. Steeper arterial tension curve (e.g. N2O) → lower blood:gas partition coefficient → lower solubility → faster onset of action
13. Less steep arterial tension curve (e.g. halothane) → higher blood:gas partition coefficient → higher solubility → slower onset of action
14. Mac and cheese: minimum alveolar concentration (MAC)
15. 1 out of 2 unresponsive: MAC corresponds to the dose of anesthetic that causes 50% of patients to become unresponsive to painful stimuli
16. Inverted bowl of potent mac and cheese:1/MAC corresponds to the potency of an inhaled anesthetic
17. Deflating lung balloons: inhaled anesthetics can cause respiratory depression (leading to decreased minute ventilation and hypercapnia)
18. Red brain wig: fluorinated anesthetics increase cerebral blood flow (decrease cerebral vascular resistance)
19. Cracked liver: halothane can be hepatotoxic (e.g. massive hepatic necrosis)
20. Smacked in the flank: enflurance can be nephrotoxic
21. Shaking: enflurance can induce seizures
22. Magnificent birthday: malignant hyperthermia (skeletal muscle hypersensitivity to volatile anesthetics)
23. "Sucks": succinylcholine (depolarizing muscle relaxant) can also causes malignant hyperthermia
24. Defective RYAN: malignant hyperthermia is related to a defect in ryanodine receptors (RyR) in the sarcoplasmic reticulum
25. Flame theme: defective RyR release excess Ca2+ → excessive ATP dependent uptake by the SR → heat production
26. Bite out of muscle: excess heat production and consumption of ATP induces muscle damage (e.g. rhabdomyolysis)
27. Trampoline: dantrolene (muscle relaxant) treats malignant hyperthermia
28. Blocking Ryan: dantrolene blocks ryanodine receptors





Opioid analgesics, Opioid antitussives, Opioid antidiarrheal, Methadone, Buprenorphine, Naloxone, Naltrexone

1. Utopia: opiates
2. µssage: µ-opioid receptor (mediates most clinical and adverse effects: e.g. analgesia, sedation, constipation, respiratory depression)
3. Open banana barrels: opiate receptors open K+ channels
4. Closed Calci-Yum ice cream cooler: opiate receptors close VG Ca2+ channels
5. Disconnected presynaptic wire: closure of presynaptic VG Ca2+ channels prevents release of neurotransmitters (e.g. glutamate, acetylcholine, norepinephrine, serotonin, substance P)
6. "Fantasy": fentanyl (opioid analgesic)
7. "More fun": morphine (opioid analgesic)
8. Distant tram: tramadol (a weak µ-opioid receptor agonist used to manage chronic pain)
9. North-South: tramadol also inhibits reuptake of norepinephrine and serotonin
10. Colon µssage table: µ-opioid receptors are located in the GI tract (delay stool transit)
11. Removed muddy slippers: opioids (e.g. loperamide, diphenoxylate) can be used as antidiarrheals
12. Lop-eared rabbit: loperamide (opioid antidiarrheal)
13. Loping back and forth: loperamid increases colonic phasic segmentation (increase stool transit time)
14. Dolphins: diphenoxylate (opioid antidiarrheal)
15. Barcode: codeine (opioid antitussive)
16. Orphan: dextromethorphan (opioid antitussive)
17. Tethered nomadic camel: dextromethorphan antagonizes NMDA receptors
18. Cerebral towel: opiates cause CNS depression (e.g. sedation)
19. Deflated lung vest: opiates can cause respiratory depression
20. Constricted hood: opiates cause miosis (constricted pupils)
21. Plunger: opiates can cause constipation
22. Biliary tree: opiates can cause biliary colic (contract biliary smooth muscle)
23. "All are welcome": patients may develop tolerance to opiates
24. "Out of order": tolerance does not develop for miosis or constipation
25. Causing pain: opiate induced hyperalgesia can occur with chronic use
26. Anxious, hot, and moist: opioid withdrawal (rhinorrhea, lacrimation, yawning, hyperventilation, hyperthermia, muscle aches, vomiting, diarrhea, anxiety)
27. DONE timer: methadone (long acting opioid used to attenuate withdrawal symptoms)
28. Long tapering flag: methadone and buprenorphine have a long half lives (used in opioid detoxification)
29. Blueprint: buprenorphine (long acting partial µ-opioid agonist used to attenuate withdrawal symptoms)
30. Irritable, moist, tachypneic baby: neonatal abstinence syndrome (diarrhea, sweating, sneezing, crying, tachypnea, irritability)
31. Partial µssage: partial µ-opioid agonists (e.g. buprenorphine, nalbuphine, butorphanol)
32. Falling into the withdraw spa: partial µ-opioid agonists can induce withdrawals)
33. No lax zone: naloxone (µ-opioid antagonist) used to reverse acute opioid toxicity (can precipitate withdrawals)
34. No tricks zone: naltrexone (µ-opioid antagonist) helps maintain abstinence in heroin addicts)
35. Tempting alcohol: naltrexone (µ-opioid antagonist) helps reduce cravings for alcohol and nicotine
36. Getting fit: naltrexone (µ-opioid antagonist) can help with weight loss



SSRIs, SNRIs, Cyproheptadine

1. expreSS tRIps: selective serotonin reuptake inhibitors (SSRIs)
2. Parrot: paroxetine (SSRI)
3. Fly out: fluoxetine (SSRI)
4. Desert Airline: sertraline (SSRI)
5. City: citalopram (SSRI)
6. Smiley face: serotonin (5-HT)
7. Keeping post-it out of the drawer: SSRIs inhibit the presynaptic reuptake of serotonin (5-HT)
8. Fax machine: venlafaxine (SNRI)
9. Dual copier/scanner: duloxetine (SNRI)
10. North and South: SNRIs (e.g. venlafaxine, duloxetine) inhibit the presynaptic reuptake of norepinephrine and serotonin
11. Happy and sad masks: SSRIs and SNRIs are first line agents for the treatment of depression
12. 5H-TV: serotonin (5-hydroxytryptamine, 5-HT)
13. Anxious coworker: SSRIs and SNRIs are 1st line agents for the treatment of generalized anxiety disorder (GAD)
14. The Scream: SSRTs and SNRIs treat panic disorder
15. Dog tags: SSRIs and SNRIs treat PTSD
16. Obsessively neat: SSRIs are useful in the management of OCD
17. Binge drawer: SSRIs are useful in the management of bulimia
18. Shy guy: SSRIs are useful in the management of social anxiety disorder
19. Pain in the Diasweetes machine: SNRIs (e.g. venlafaxine, duloxetine) treat diabetic neuropathy
20. Chronically frayed wire: SNRIs treat chronic pain (e.g. neuropathic pain)
21. Fiber bars: SNRIs (e.g. venlafaxine, duloxetine) treat fibromyalgia
22. 2 month calendar: SSRIs and SNRIs take 1-2 months to achieve maximum effect (not for acute treatment)
23. Inappropriately wet head: SSRIs may cause hyponatremia (SIADH)
24. Rejected advances: SSRIs can cause sexual dysfunction
25. Fat belly: SSRIs can cause weight gain
26. Sleeping on the job: SSRIs can cause drowsiness
27. Excessive smiley faces: SSRIs and SNRIs can cause serotonin syndrome
28. Hot and hypertensive: serotonin syndrome is characterized by hyperthermia and hypertension
29. Hyperactive foot tap: serotonin syndrome is characterized by neuromuscular hyperactivity (e.g. hyperreflexia, clonus)
30. Tricycle and mouse traps: serotonin syndrome can occur if SSRIs or SNRIs are combined with other drugs that increase serotonin levels (e.g. TCAs, MAO inhibitors)
31. "Silly pranks prohibited": cyproheptadine (5HT-2 blocker) treats serotonin syndrome
32. Hypertensive coworker: SNRIs can cause hypertension
33. Withdrawn with the flu: withdrawal symptoms from SSRIs and SNRIs include flu-like symptoms





Tricyclic Antidepressants (TCAs)

1. Tricycle: TCAs
2. Imprint: imipramine (and derivatives desipramine, clomipramine – TCAs)
3. Tripping: amitriptyline, nortriptyline
4. Prevented from picking up smiley face and compass balls: TCAs inhibit presynaptic uptake of serotonin and norepinephrine
5. Happy and sad masks: TCAs can be useful in treatment resistant depression
6. Resistant door: TCAs can be useful in treatment resistant depression
7. Pain in the Diasweetes machine: TCAs treat diabetic neuropathy
8. Chronically frayed wire: TCAs treat chronic pain (e.g. neuropathic pain)
9. Pounding head bell: TCAs can be used for migraine prophylaxis
10. Obsessively neat: clomipramine (TCA) treats OCD (SSRIs first line)
11. Rejected advances: TCAs can cause sexual dysfunction
12. Anti-muscarinic tea party: TCAs inhibit muscarinic acetylcholine receptors → dry mouth, constipation, blurred vision, urinary retention
13. Northside Prep: nortriptyline and desipramine (secondary amines)
14. Protected by secondary sign: secondary amines (e.g. nortriptyline and desipramine) are associated with less cholinergic effects
15. Confused elderly: TCAs are relatively contraindicated in elderly patients due to severe anticholinergic and antihistamine effects
16. Bee swatter: TCAs block H1 histamine receptors
17. Sleeping kid: TCAs can cause sedation
18. Hefty kid: TCAs can cause increased appetite and weight gain
19. Extinguished alpha flame: TCAs block alpha-1 receptors
20. Passed out: TCAs can cause orthostatic hypotension
21. Inactivated peanut butter jar: TCAs block the cardiac fast Na+ channels
22. Wide QRS crack: TCAs can widen the QRS complex on ECG
23. Twisted torsades streamer: TCAs can induce torsades
24. Baking soda: sodium bicarb treats widened QRS and ventricular arrhythmia caused by TCA overdose
25. Shaking kid: TCAs can induce seizures
26. Stack of smiley faces: TCAs can cause serotonin syndrome





MAO Inhibitors

1. Albino mouse: monoamide oxidase A (MAO-A)
2. Albino mouse eating smiley face: MAO-A breaks down serotonin
3. Albino mouse eating north compass: MAO-A breaks down norepinephrine
4. Albino mouse eating rope: MAO-A breaks down dopamine
5. Black mouse: MAO-B
6. Mouse trap: MAO inhibitors
7. Irreversible trap: MAO inhibitors are irreversible
8. "Try a sip of wine": tranylcypromine (MAO inhibitor)
9. Funnel: phenelzine (MAO inhibitor)
10. Boxed wine: isocarboxazid (MAO inhibitor)
11. "Not typical": MAO inhibitors may be useful in atypical depression
12. Happy and sad mask: MAO inhibitors can treat depression (not 1st line)
13. Resistant wine bottle: MAO inhibitors can be useful in treatment resistant depression
14. Sledge hammer: selegiline (selective MAO-B inhibitor)
15. Brain tied with rope: selegiline (selective MAO-B inhibitor) increase dopamine levels in the CNS
16. Cog wheels: selegiline is useful in the management of Parkinson's disease (increases dopamine levels in the CNS)
17. Aged meats, wine, cheese: MAO inhibitors should be avoided with these tyramine containing foods
18. Albino mouse eating GI meat: tyramine is normally broken down by MAO-A in the GI tract
19. Trap releasing north compass cheeses: in the presence of MAO inhibitors, tyramine enters the circulation and acts as a sympathomimetic agent
20. Hypertensive and sweaty: tyramine toxicity can precipitate a hypertensive crisis (e.g. hypertension, blurry vision, diaphoresis)
21. Pile of smiley faces: MAO inhibitors can cause serotonin syndrome
22. Tricycle: MAO inhibitors should be avoided with other drugs that increase serotonin levels (e.g. TCAs, SSRIs, SNRIs → cause serotonin syndrome)
23. Phantom of the alpha: phentolamine (alpha-1 and alpha-2 blocker) can be used to manage hypertensive symptoms of tyramine toxicity



Atypical antidepressants: Bupropion, Mirtazapine, Trazodone

1. "NET DAT ball": bupropion inhibits the norepinephrine transporter (NET) and the dopamine transport (DAT)
2. Pro ball player: bupropion (atypical antidepressant)
3. Aroused from sleep: bupropion exerts CNS activating effects
4. "Pros don't smoke": bupropion can be used to treat tobacco dependence
5. Shaking: bupropion can induce seizures
6. Shaking binge snacker: bupropion is contraindicated in bulimia (may induce seizures)
7. Shaking skinny player: bupropion is contraindicated in anorexia nervosa (may induce seizures)
8. Kissing couple: bupropion does not cause sexual dysfunction
9. "Lose weight": bupropion is less likely to cause weight gain
10. "Mirth and Misery": mirtazapine (atypical antidepressant
11. Happy and sad masks: atypical antidepressants can be used as 1st line agents to treat depression
12. Retired 52 and 53: mirtazapine blocks 5HT-2 and 5HT-3 receptors
13. Bee swatter: mirtazapine inhibits H1 histamine receptors
14. Sleeping fan: mirtazapine can cause sedation
15. Hefty fan: mirtazapine can cause weight gain
16. Kissing couple: mirtazapine does not cause sexual dysfunction
17. Trombone: trazodone (serotonin modulator)
18. Smiley face drummer: trazodone is a serotonin modulator (antagonizes 5-HT receptors and inhibits 5-HT reuptake)
19. Retired 52: trazodone inhibits 5HT-2 receptors
20. Extinguished alpha lighter: trazodone antagonizes alpha-1 receptors
21. Erect trombone: trazodone can cause priapism
22. Fainting: trazadone can cause orthostatic hypotension
23. Sleeping players: trazodone can cause sedation
24. Bee swatter: trazodone inhibits H1 histamine receptors
25. Rejected advances: trazodone can cause sexual dysfunction
26. Pile of smiley faces: trazodone can cause serotonin syndrome





Lithium

1. Stabilizing poles: mood stabilizers (e.g. lithium, valproate, carbamazepine, lamotrigine, antipsychotics)
2. Stabilizing chair lift: lithium treats bipolar disorder (acute mania and maintenance)
3. Narrow window: lithium has a very narrow therapeutic index
4. Early nausea: acute lithium toxicity causes GI symptoms (e.g. nausea, vomiting, diarrhea)
5. Late trembling: chronic lithium toxicity causes neurologic symptoms (e.g. tremor)
6. Late falling: chronic lithium toxicity causes neurologic symptoms (e.g. ataxia)
7. Undone bowtie: lithium therapy can cause hypothyroid
8. Hefty snowboarder: signs of lithium induced hypothyroidism include weight gain, dry skin, hair loss, and constipation
9. Insipidus fountain: lithium can cause nephrogenic diabetes insipidus
10. Thighs on high dive: thiazide diuretics (increase lithium levels)
11. “Low clearance”: diuretics (e.g. thiazides) and NSAIDs decrease clearance of lithium (decrease GFR)
12. Tarantula: lithium is teratogenic (Ebstein’s anomaly)
13. Large right head: atrialization of the right ventricles (seen in Ebstein’s anomaly with ASD and malformed tricuspid)
14. “Winter festival”: valproate treats bipolar disorder (acute mania and maintenance)
15. Classic car carving: carbamazepine treats bipolar disorder (acute mania and maintenance)
16. Llama: lamotrigine treats bipolar disorder (maintenance only)
17. Psychotic painting on the high peak: first generation (e.g. haloperidol) and second generation (e.g. quetiapine) antipsychotics treat acute mania





Valproate, Topiramate, Lamotrigine, Levetiracetam

1. "Seize the land": broad spectrum antiepileptic agents (e.g. valproate, topiramate, lamotrigine, levetiracetam)
2. Focal arm shaking: broad spectrum antiepileptic agents (e.g. valproate) treat focal seizures
3. Generalized body shaking: broad spectrum antiepileptic agents (e.g. valproate) treat generalized seizures
4. Juvenile shaking arms: broad spectrum antiepileptic agents (e.g. valproate) treat juvenile myoclonic epilepsy (a type of generalized seizure disorder)
5. Welcome festival: valproate (broad spectrum antiepileptic)
6. Inactivated baskets of salty peanuts: valproate increases Na+ channel inactivation
7. Elevated cab: valproate increases GABA levels in the CNS
8. Nauseated: valproate can cause GI distress (e.g. nausea, vomiting)
9. Fat belly: valproate can cause increased appetite and weight gain
10. Trembling weapon: valproate can cause tremor
11. Liver spot: valproate can cause fatal hepatotoxicity
12. Squeezed pancreas sponge: valproate can cause pancreatitis
13. Tarantula: valproate is teratogenic
14. Tubes: valproate therapy during pregnancy can cause neural tube defects (e.g. spinal bifida)
15. Toupee: topiramate (broad spectrum antiepileptic drug)
16. Inactivated baskets of salty peanuts: topiramate increases Na+ channel inactivation
17. Binding to cab driver: topiramate allosterically binds to the GABA-A receptor
18. Fatigued soldiers: topiramate can cause somnolence and fatigue
19. Scratching head: topiramate can cause confusion and cognitive slowing
20. Thin arm: topiramate can cause weight loss
21. High pressure eye kettle: topiramate can cause acute angle closure glaucoma
22. Llama: lamotrigine (broad spectrum antiepileptic drug)
23. Inactivated baskets of salty peanuts: lamotrigine increases Na+ channel inactivation
24. Sloughed off red mask: topiramate can cause Stevens-Johnson syndrome (SJS/TEN)
25. Cross-eyed: topiramate can cause diplopia
26. Elevator: levetiracetam (broad spectrum antiepileptic drug)
27. Sleeping on the job: levetiracetam can cause somnolence
28. Chrome CYP450 cannon: many antiepileptic drugs are metabolized by the hepatic cytochrome P450 system



Carbamazepine, Phenytoin, Gabapentin, Tiagabine, Vigabatrin

1. "Seize the Night": narrow spectrum antiepileptic agents (e.g. carbamazepine, phenytoin, phenobarbital, gabapentin)
2. Focal arm shaking: narrow spectrum antiepileptic agents (e.g. carbamazepine, phenytoin) treat focal seizures (and generalized tonic-clonic)
3. Classic car: carbamazepine (narrow spectrum antiepileptic drug)
4. Inactivated salty sodium chip bags: carbamazepine increases Na+ channel inactivation
5. Three gems: carbamazepine is a first line therapy for trigeminal neuralgia
6. Unbalanced stack: carbamazepine can cause ataxia
7. Misaligned headlights: carbamazepine can cause diplopia
8. Inappropriate wet head: carbamazepine can cause syndrome of inappropriate ADH (SIADH)
9. Sand timer: carbamazepine can cause agranulocytosis
10. Activated chrome bumper: carbamazepine induces cytochrome P450
11. Eosinophilic dress: carbamazepine can cause drug reaction with eosinophilia and systemic symptoms (DRESS) syndrome
12. Tarantula: carbamazepine is teratogenic
13. Neural exhaust tube: carbamazepine therapy during pregnancy can cause neural tube defects (e.g. spina bifida)
14. Sloughed off red mask: carbamazepine can cause Stevens-Johnson syndrome (SJS/TEN)
15. Classic tow truck: phenytoin (narrow spectrum antiepileptic drug)
16. Inactivated salty sodium chip bags: phenytoin increases Na+ channel inactivation
17. Unbalanced stack: phenytoin can cause ataxia
18. Misaligned headlights: phenytoin can cause diplopia
19. Spilled salad: phenytoin can cause folate deficiency → megaloblastic anemia
20. Expanding gum: phenytoin can cause gingival hyperplasia
21. Big bushy beard: phenytoin can cause hirsutism
22. Lupus wolf: phenytoin and carbamazepine can drug-induced lupus
23. Eosinophilic dress: phenytoin can cause drug reaction with eosinophilia and systemic symptoms (DRESS) syndrome
24. Sloughed off red mask: phenytoin can cause Stevens-Johnson syndrome (SJS/TEN)
25. Tarantula: phenytoin is teratogenic
26. Cleft trucker hat: phenytoin therapy during pregnancy can cause left palate
27. Activated chrome bumper: phenytoin induces cytochrome P450
28. Fractured osteoporotic axle: phenytoin can decrease bone density
29. "Status": status epilepticus (treat acutely with benzodiazepines and phenytoin for maintenance)
30. Ben's Diner: IV benzodiazepines (e.g. diazepam, lorazepam) acutely treat status epilepticus (give phenytoin for maintenance)
31. Barbershop: IV phenobarbital (barbiturate) can be used in treatment refractory seizures
32. "Grab a pint": gabapentin (narrow spectrum antiepileptic drug)
33. Closed Calci-Yum ice cream cooler: gabapentin blocks voltage gated Ca2+ channels
34. Chronically frayed wire: gabapentin treats chronic pain (e.g. neuropathic pain)
35. Diasweeties: gabapentin treats painful diabetic nephropathy
36. Fiber bars: gabapentin treats fibromyalgia
37. Zeus: gabapentin treats post-herpetic neuralgia (reactivated varicella-zoster virus – VZV)
38. Unbalanced stack: gabapentin can cause ataxia
39. Raised CAB: vigabatrin and tiagabine (narrow spectrum antiepileptic drugs)
40. V cab transmission: vigabatrin irreversible inhibits GABA transaminase (decrease GABA degradation)
41. Tied up cab driver: tiagabine inhibits GABA reuptake





Ethosuximide, Valproate, Lamotrigine

1. "Seize the day": antiepileptic therapy for absence seizures (e.g. ethosuximide)
2. "Absences"; absence seizure (a type of generalized seizures)
3. Inattentive student: absence seizures are characterized by sudden momentary lapse in awareness accompanied by staring, blinking, or clonic jerks
4. "3 spikes": absence seizure manifest as 3 Hz spike wave complexes on EEG
5. "Ethos": ethosuximide (a narrow spectrum anti-epileptic drug used to treat absence seizures)
6. Closed Calci-Yum chocolate: ethosuximide blocks Ca2+ channels
7. Closed T-thermos: ethosuximide blocks T-type Ca2+ channels in the thalamus
8. Punched in stomach: ethosuximide can cause GI distress (e.g. pain, nausea, vomiting)
9. Sleeping student: ethosuximide can cause lethargy or fatigue
10. FestiVAL banner: valproate is effective against absence seizures
11. Llama: lamotrigine is effective against absence seizures





First generation antipsychotics – Haloperidol, Trifluoperazine, Fluphenazine, Chlorpromazine, Thioridazine

1. Typical post-impressionist: first generation (typical) antipsychotics (FGAs)
2. "Gazing": "-azine" suffix of FGAs (e.g. trifluoperazine, fluphenazine, chlorpromazine, thioridazine)
3. Halo: haloperidol (high potency FGA)
4. Snapping double rope: FGAs block D2 receptors in the CNS
5. Trying to fly: trifluoperizine, fluphenazine (high potency FGAs)
6. "Color theory": thioridazine (low potency FGA)
7. "Color-Pro": chlorpromazine (low potency FGA)
8. Blocking positive voices: FGAs treat the positive symptoms of schizophrenia
9. Crazy peak: antipsychotics treat acute psychosis in many conditions (e.g. bipolar)
10. Agitated peak: antipsychotics (e.g. haloperidol) treat acute agitation or aggression
11. Marionette: FGAs can be useful for the management of Tourette syndrome
12. Long tapering flag: FGAs have a long half life (highly lipophilic)
13. Antimuscarinic tea party: FGAs (low potency > high potency) block muscarinic receptors → dry mouth, constipation, blurred vision, urinary retention
14. Passed out: FGAs (low potency > high potency) can cause orthostatic hypotension
15. Extinguished alpha flame: FGAs (low potency > high potency) block alpha-1 receptors
16. Bee swatter: FGAs (low potency > high potency) block H1 histamine receptors
17. Van Gogh's bed: FGAs (low potency > high potency) can cause sedation
18. EXTRA pyramid hat on the roof: FGAs (high potency > low potency) cause extrapyramidal symptoms (EPS)
19. Cocked head: acute dystonia (EPS seen within minutes)
20. Falling chair: akathisia (EPS seen within days)
21. Cog wheels: drug induced Parkinsonism (EPS seen within weeks)
22. Sticking out tongue: FGAs (high potency > low potency) can cause tardive dyskinesia
23. Elevated milk production: FGAs (high potency > low potency) can cause hyperprolactinemia → galactorrhea, amenorrhea, impotence
24. "Now More Spicy": FGAs (high potency > low potency) can cause neuroleptic malignant syndrome (NMS)
25. Rigidly holding pipe: NMS is characterized by generalized "lead-pipe" rigidity
26. Crazy, sweaty, and tachycardic: NMS is characterized by altered mental status, fever, autonomic instability
27. Eaten chicken: NMS is characterized by rhabdomyolysis
28. Twisted streamer: FGAs can cause torsades de pointes
29. Shaking: FGAs can cause lower the seizure threshold
30. Corn Yellow paint: chlorpromazine can cause corneal deposits
31. Deposits on retinal palette: thioridazine can cause retinal deposits





Second generation antipsychotics – Olanzapine, Quetiapine, Aripiprazole, Ziprasidone, Risperidone, Clozapine

1. Atypical surrealist: second generation (atypical) antipsychotics (SGAs)
2. "Quiet please, only whispering is appropriate": quetiapine, olanzapine, risperidone, aripiprazole (SGAs)
3. Zipper: ziprasidone (SGA)
4. Clozapine: clozapine (SGA)
5. Snapping double rope: SGAs block D2 receptors in the CNS
6. Cut smiley cake: SGAs block serotonin receptors (5-HT 2A)
7. Hearing positive and negative voices: SGAs treat schizophrenia (positive and negative symptoms)
8. Happy and sad masks: SGAs can treat depression (treatment resistant)
9. Resisting opening: treatment resistant depression
10. Obsessively neat: SGAs (e.g. risperidone) can help manage OCD (adjunctive with SSRIs)
11. Marionette: risperidone can help manage Tourette syndrome
12. Bee swatter: SGAs block H1 histamine receptors → sedation
13. Extinguished alpha candle: SGAs block alpha-1 receptors → orthostatic hypotension
14. Antimuscarinic tea party: SGAs (especially clozapine) block muscarinic receptors → dry mouth, constipation, blurred vision, urinary retention
15. Obscured tea party: SGAs have lower affinity for muscarinic receptors than FGAs (less antimuscarinic symptoms)
16. Passed out: SGAs can cause sedation and orthostatic hypotension(block H1 and alpha-1)
17. Fat face: SGAs (e.g. olanzapine, clozapine) can cause weight gain
18. Bunch of candy: SGAs (e.g. olanzapine, clozapine) can cause hyperglycemia
19. Elevated butter: SGAs (e.g. olanzapine, clozapine) can cause dyslipidemia
20. Melting sand timers: clozapine can cause agranulocytosis
21. Surreal heart: clozapine can cause myocarditis or cardiomyopathy
22. Shaking clock: clozapine reduces seizure threshold
23. EXTRA pyramid hat: extrapyramidal symptoms (e.g. acute dystonia, akathisia, parkinsonism) due to D2 blockade (FGA > SGA)
24. Whispering to EXTRA hat: risperidone has the highest risk of causing EPS among the SGAs
25. Elevated milk release: elevated prolactin levels due to D2 blockade (FGA > SGA)
26. "Now more spicy": neuroleptic malignant syndrome (e.g. mental status changes, rigidity, autonomic instability, fever) (FGA > SGA)
27. Bite out of chicken leg: NMS is associated with rhabdomyolysis
28. Twisted torsades streamer: SGAs can cause torsade de pointes





Levodopa, Carbidopa, Entacapone, Tolcapone, Selegiline, Ropinirole, Pramipexole, Amantadine

1. Cracked open cogwheels: parkinsonism therapy
2. Bank vault threshold: blood brain barrier (BBB)
3. "L" rope crank inside vault: levodopa (L-DOPA) crosses the BBB
4. Unfurled rope in vault: levodopa is converted to dopamine by DOPA decarboxylase in the CNS
5. Unfurled rope in lobby: levodopa is converted to dopamine by DOPA decarboxylase in the periphery (can't cross BBB)
6. Nauseated hostage: levodopa can cause GI distress (due to peripheral conversion into dopamine)
7. Arrhythmia rope: levodopa can cause cardiac arrhythmias (due to peripheral conversion into dopamine)
8. Passed out hostage: levodopa can cause orthostatic hypotension (due to peripheral conversion into dopamine)
9. Psychiatrically disturbed hostage: levodopa can cause neuropsychiatric symptoms e.g. anxiety, agitation, insomnia, confusion, hallucination (due to excess dopamine in the CNS)
10. End of rope wearing-off: chronic levodopa therapy can cause a wearing-off reaction (akinesia and dyskinesia re-emerge at the end of each dose)
11. "Too long!": chronic levodopa therapy can cause response fluctuations (wearing-off reaction, on-off phenomenon) and dyskinesias
12. Flashing on and off: chronic levodopa therapy can cause an on-off phenomenon (periods of akinesia alternate with periods of improved mobility, not related to dose)
13. Narrowing window: the therapeutic window of levodopa therapy narrows as Parkinson's progresses (unpredictable response to therapy)
14. Writhing sneeze: chronic levodopa therapy can cause dyskinesias (choreoathetosis of the face and distal extremities)
15. Damaged psychotic painting: levodopa is contraindicated in psychotic patients
16. Police car on periphery: carbidopa (peripheral DOPA decarboxylase inhibitor)
17. Scared into vault: carbidopa increases the bioavailability of levodopa (prevents peripheral conversion into dopamine)
18. Pulling away from hostages: carbidopa decreases peripheral side effects of levodopa therapy (but exacerbates neuropsychiatric side effects)
19. InTerCOM guard shooting "L" crank: catechol-O-methyltransferase (COMT) converts levodopa to 3-O-methyldopa (3-OMD) in the periphery
20. Tall Al Capone gangster: tolcapone (a peripheral and central COMT inhibitor) increases the bioavailability of levodopa





Levodopa, Carbidopa, Entacapone, Tolcapone, Selegiline, Ropinirole, Pramipexole, Amantadine (continued)

22. Al Capone gangster at entrance: entacapone (a peripheral COMT inhibitor) increases the bioavailability of levodopa
23. InTerCOM guard in vault: catechol-O-methyltransferase (COMT) converts dopamine to 3-methoxytyramine (3-MT) in the CNS
24. Tall gangster in vault: tolcapone (a peripheral and central COMT inhibitor) increases dopamine levels in CNS
25. Hepatic gun: tolcapone can cause hepatic failure
26. Black mouse eating rope: monoamine oxidase B (MAO-B) selectively metabolizes opamine
27. Sledge hammer: selegiline (a selective MAO-B inhibitor) increases dopamine levels in the CNS
28. Double rope ladder: D2 dopamine receptor
29. Rope in a roll: ropinirole (D2 dopamine receptor agonists) is an important initial treatment of Parkinson's
30. Big pecs: pramipexole (D3 dopamine receptor agonist) is an important initial treatment of Parkinson's
31. Restless legs: dopamine receptor agonists (e.g. ropinirole, pramipexole) treat restless leg syndrome (RLS)
32. "Rock and roll": dopamine receptor agonists (e.g. ropinirole) may enhance impulse control disorders (e.g. gambling, shopping, hypersexuality)
33. Manatee: amantadine can treat some motor symptoms of Parkinson's
34. Breaking open rope: amantadine enhances the effect of endogenous dopamine (by increasing its synthesis/release and inhibiting its uptake)
35. Tri-hex Benz car: trihexyphenidul and benztropine (antimuscarinic agents used to treat parkinsonism)
36. Trembling getaway car: trihexyphenidyl and benztropine (antimuscarinic agents) improve tremor and rigidity of Parkinson's with no effect on bradykinesia





Cyclophosphamide, Ifosfamide, Busulfan, Nitrosoureas (Carmustine, Lomustine, Streptozocin)

1. Cyclops Polyphemus: cyclophosphamide (cytotoxic alkylating agent)
2. Cross-linking ankle chain: alkylating agents donate an alkyl group → DNA cross-links (cell cycle NONspecific)
3. Activating chrome bumper: cyclophosphamide is ACTIVATED by hepatic cytochrome P450 enzymes
4. Torn cancer crab: cyclophosphamide treats many hematologic and solid malignancies (e.g. leukemias and lymphomas, breast cancer, ovarian cancer)
5. Torn antibody: cyclophosphamide is a potent immunosuppressive therapy (e.g. treatment of nephrotic syndrome, nephritic syndrome, vasculitis, autoimmune hemolytic anemia)
6. Broken marrow: cyclophosphamide can cause myelosuppression
7. Red urine: cyclophosphamide can cause hemorrhagic cystitis
8. Protective maze: co-administration of 2-mercaptoethanesulfonate (MESNA) prevents hemorrhagic cystitis
9. Cancer crab belt buckle: cyclophosphamide increases risk of bladder cancer (high grade transitional cell carcinoma)
10. Inappropriately wet head: cyclophosphamide can cause hyponatremia due to SIADH
11. Dried up fruit tree: cyclophosphamide can cause infertility and premature menopause
12. Beautiful sirens: busulfan (cytotoxic alkylating agent)
13. Cross-linking ankle chains: alkylating agents donate an alkyl group → DNA cross-links (cell cycle NONspecific)
14. Severely depleted marrow: busulfan is useful as a conditioning agent prior to bone marrow transplantation
15. Fibrotic lung pattern: busulfan can cause lung toxicity (e.g. acute lung injury, interstitial fibrosis, alveolar hemorrhage)
16. Beautiful TAN sirens: busulfan can cause a hyperpigmentation reaction ("busulfan tan")
17. Centaurs: nitrosoureas (cytotoxic alkylating agents)
18. Mustang: "-mustine" suffix of nitrosoureas (e.g. carmustine, lomustine)
19. Striped zebra centaur: streptozotocin (nitrosoureas – cytotoxic alkylating agent)
20. Brain tree: nitrosoureas are highly lipophilic → cross BBB → treat brain tumors (e.g. glioblastoma multiform)
21. Dizzy centaur: nitrosoureas can cause neurotoxicity (e.g. convulsions, dizziness, ataxia)





Methotrexate, leucovorin, 5-fluorouracil, hydroxyurea

1. Hexagonal plates- pyrimidines are shaped like hexagons. These drugs block synthesis of thymidine, a pyrimidine nucleoside
2. Dumplings- dUMP (deoxyuridine monophosphate) is precursor to dTMP
3. T shape chopsiticks- after eating dumpling, turns into dTMP
4. sushi boat /belt- cycle powered by folate cycle
5. 4 leaves on boat-tetrahydrofolate (THF)
6. C shaped sushi on boat is the carbon for donation.
7. Transfer of C sushi catalyzes the converion of THF to DHF and methylation of dUMP to dTMP, catalyzed by thymidylate synthase
8. DHF converted back to THF by dihydrofolate reducatase, adding 2 hydrogens is reducing it
9. Adding C shape sushi- methylate the THF to become a carbon donor again.
10. Methotrexate-MTX-meat stix chef. A cytotoxic folate analog, preventing conversion of DHF to THF. Inhibits dihyrofolate reductase.
11. Build up of boats- build up of DHF. Stop DNA and RNA synthesis in rapidly dividing cells.
12. Sushi phase: S phase affected. DNA production blocked (chopsticks clamping down on noodles)

Treatment:

13. Cracked crab- agents treat cancers
14. Empty uterus backpack-MTX with misoprostol used as abortifacient and ectopic pregnancy (baby keychain on the side)
15. Mole keychain- tx invasive molar pregnancy, trophoblastic tumors and choriocarcinoma
16. Silver knee/elbow pads-MTX tx psoriasis
17. Joint lantern with flame- MTX first line tx for rheumatoid arthritis or DMARD
18. Torn antibody latern- MTX used for immunosuppressive therapy such as IBD, SLE, vasculitis, dematomyositis

MTX Side effects:

19. Foliage falling: folate deficiency
20. Blasting firework lantern: megaloblastic anemia
21. Falling pan of sushi: pancytopenia, myelosuppression
22. Cane: immunosuppressed have increased risk for infection
23. Fibrotic lung bonsai: lung fibrosis (restrictive lung dz)
24. Liver spot on apron- hepatotoxicity, monitor LFTs
25. Bald guy- causes baldness
26. Guy eating hot meat stick- mucositis
27. Lucky feline- leucovorin/ folonic acid, antidote

---

28. Full guy- 5-FU. Complexes with THF and inhibits thymidylate synthase to block thymidine production (touching sushi donation)
29. Buildup of dumpling plates- increase dUMP via inhibition of thymidylate synthase
30. Stained pants- diarrhea
31. Sensitive photos- photosensitivity and rash
32. 5-FU also increases myelosuppression and infection
33. Knocked over cat- no antidote for 5-FU

---

34. UDP sign- UDP (uridine diphosphate) is precursor to pyrimidine nucleosides
35. Crossed out OXY- ribonucleotide reductase (converts UDP to deoxy-UDP)
36. Hydro rock area- hydroxyurea , ribonucleotide reductase inhibitor, blocks thymidine synthesis (inhibited wait list waitress)
37. Zen sickle- tx sickle cell,
38. Raised baby with Hb coin - increase HbF, protection against HbS
39. Also myelosuppression and increased infection side effect





Hunchback of notre DNA: purine inhibitors- Azathioprine, 6-mercaptopurine, mycophenolate mofetil
1. pentagon pedestal with 3 P hammers: PPRP (phosphoribosyl pyrophosphate), precursor to IMP. Ribose sugar with 3 Ps attached
2. gargoyle imp: IMP is intermediate purine nucleotide, precursor to AMP and GMP
3. golden statues on side- right statue is GruMPy=GMP. Left statue is grAMPs- AMP. The final products of IMP.
4. purine shape behind statues' head
5. gold- pure As Gold nmeumonic
6. Esmeralda- Aza-meralda. AZA is prodrug of cytotoxic purine analog 6-mercaptopurine (purine earrings)
7. CAPTured gypsy- 6-merCAPTopurine, chains also shaped as purines.
8. HiGh Priest- need HGPRT (enzyme) to activate 6-MP
9. staff is prodding captive- activation of 6-MP
10. captive toppling imp- block synthesis of IMP
11. broken stair way- inhibits DNA synthesis, blocks S phase
12. stained glass window with crabs, antibody archers and T knights- treats hematogenous malignancies ex: ALL
13. torn lanterns with antibodies and bone- used for immunosuppressive therapies ex/ SLE, grafts. inflammations
14. bone lantern- tx rheumatoid arthritis, DMARD
15. inflamed colonic lanterns- tx inflammatory bowel dzs
16. nun with bone tray feeding bird- bone marrow suppression
17. statue with cane- immunosuppression and increased risk for infection, monitor pt with CBCs
18. pancreas sponge-pancreatitis
19. liver stain on apron- hepatotoxicity or hepatitis
20. pure nuns- allopurinol, a xanthine oxidase inhibitor (XO)
21. purine bead necklace- inhibition of XO increases level of purine analogs (6-MP) and cause toxicity/ effects
22. quasimoto- quasi-mofetil, mycophenolate mofetil (IMP dehydrogenase inhibitor)
23. knocking over GruMPy statue- decrease GMP synthesis, decreased lymphocyte production
24. swinging on lanterns- for immunosuppressive therapy (grafts, SLE, MG) and rheumatoid arthritis (DMARD)
25. nauseated quasi-mofetil- GI effects
26. also has immunosuppressive side effects -nuns
27. also increased infection in immunosuppressed -cane





Cladribine, Cytarabine, Gemcitabine

1. Clad in bearskins: cladribine (cytotoxic purine analog)
2. Purine shaped hammer: cladribine is a purine analog
3. Hairy caveman: cladribine treats hairy cell leukemia
4. Immunosuppressed cane: cladribine, cytarabine, and gemcitabine can cause immunosuppression and increased risk of infection
5. Saber toothed tiger: cytarabine (cytotoxic pyrimidine analog)
6. Pyrimidine shapes: cytarabine and gemcitabine are pyrimidine analogs
7. Scratched out antibody archers and T-cell swordsman: cytarabine is only active against hematologic malignancies (e.g. AML, non-Hodgkin lymphoma)
8. Gems inside geode: gemcitabine (cytotoxic pyrimidine analog)
9. Cracked crab fossil on solid rocks: gemcitabine is active against both hematologic malignancies and solid tumors
10. Cracked replication fork: cladribine, cytarabine, and gemcitabine inhibit DNA polymerase
11. Stone Phase: antimetabolites (e.g. cladribine, cytarabine, gemcitabine) inhibit the S phase of the cell cycle (DNA synthesis)
12. Broken marrow: cladribine, cytarabine, and gemcitabine can cause myelosuppression



Cisplatin, Carboplatin, Amifostine

1. Platinum: cisplatin, carboplatin, oxaliplatin (cytotoxic platinum analogs)
2. Cross-linked helix necklace: platinum analogs bind DNA and form intrastrand and interstrand cross-links
3. Crumpled crab: platinum analogs treat various solid malignancies (e.g. non-small cell lung cancer, small cell lung cancer, testicular cancer, ovarian cancer, bladder cancer)
4. Ototoxic earrings: platinum analogs can cause ototoxicity → sensorineural hearing loss, tinnitus (especially cisplatin)
5. Neuropathic gloves: platinum analogs can cause neurotoxicity → peripheral neuropathy (especially cisplatin)
6. Nephrotoxic purse: platinum analogs can cause nephrotoxicity → acute kidney injury (especially cisplatin)
7. Muddy drain tube: platinum analogs can cause acute tubular necrosis (ATN – muddy brown casts)
8. Amethyst: amifostine (an organic thiophosphate) can prevent cisplatin-induced nephrotoxicity
9. "Free, rare": amifostine scavenges free radicals produced by cisplatin in the kidney
10. saline fluids: IV saline diuresis prevents cisplatin-induced nephrotoxicity
11. Immunosuppresed cane: platinum analogs can cause immunosuppression and increased risk of infection (especially carboplatin)
12. Depleted bone jewelry box: platinum analogs can cause myelosuppression (especially carboplatin)



Bleomycin, Doxorubicin, Daunorubicin, Actinomycin D

1. Beluga whale: bleomycin (antitumor antibiotic)
2. Oxide bubbles: bleomycin binds DNA and produces free radicals (superoxide, hydroxide)
3. Broken double helix kelp: free radicals produced by bleomycin cause single and double strand breaks in DNA
4. Galleon: bleomycin blocks the G2 phase of the cell cycle
5. Cracked anticancer crab: bleomycin treats many hematologic and solid malignancies (e.g. Hodgkin and Non-Hodgkin lymphoma, germ cell tumors, squamous cell carcinoma of the skin, cervix, and vulva)
6. Lung coral: bleomycin can cause pulmonary toxicity (e.g. pneumonitis, pulmonary infiltrates)
7. Hyper-pigmented striae: bleomycin can cause skin toxicity (e.g. rash, exfoliation, hyperpigmentation, atrophic striae)
8. Poking mouth: bleomycin (and anthracyclines) can cause mucositis and stomatitis
9. Bald beluga: bleomycin can cause alopecia
10. Santa Anthracycline: anthracyclines (antitumor antibiotics)
11. Rubies: "-rubicin" suffix of anthracyclines (e.g. doxorubicin, daunorubicin)
12. Oxide bubbles: anthracyclines produce free radicals (e.g. superoxide, hydroxide)
13. Rubies inserting into helical seaweed: anthracyclines (e.g. doxorubicin) intercalate in DNA → block DNA and RNA synthesis
14. Cracked cancer crab: anthracyclines (e.g. doxorubicin) treats a broad range of solid and hematologic malignancies
15. Dilated heart ruby sacks: anthracyclines (e.g. doxorubicin) can cause cardiotoxicity (e.g. dilated cardiomyopathy)
16. Chelating the heart sack: dexrazoxane (iron chelator) prevents anthracycline-induced cardiotoxicity
17. Up on deck with razor: dexrazoxane (iron chelator)
18. Depleted bone chest: anthracyclines (e.g. doxorubicin) and actinomycin D can cause myelosuppression
19. Poking mouth: bleomycin (and anthracyclines) can cause mucositis and stomatitis
20. Bald pirate: anthracyclines (e.g. doxorubicin) can cause alopecia
21. Doll artifact: actinomycin D (antitumor antibiotic)
22. Artifacts inserting into helical seaweed: actinomycin D intercalates in DNA → block DNA and RNA synthesis
23. Child's artifact: actinomycin D treats numerous pediatric malignancies (e.g. Wilms tumor, Ewing sarcoma, rhabdomyosarcoma)
24. Bald doll: actinomycin D can cause alopecia
25. Depleted bone chest: anthracyclines (e.g. doxorubicin) and actinomycin D can cause myelosuppression





Etoposide, Teniposide, Topotecan, Irinotecan

1. Side of the tower: etoposide and teniposide (topoisomerase II inhibitors)
2. Unwinding strands: topoisomerases relieve DNA supercoiling that occurs during DNA replication
3. Grasping 2 strands: etoposide and teniposide inhibit topoisomerase II (double stranded breaks to relieve supercoiling)
4. Both strands breaking: etoposide and teniposide prevent relegation of the double strand break induced by topoisomerase II
5. "Stairs out": topoisomerase inhibitors block the S phase of the cell cycle (DNA synthesis)
6. "Gone 2 forest": topoisomerase inhibitors block the G2 phase of the cell cycle (double check and repair)
7. Ripped cancer crab: etoposide and teniposide treat many solid and hematological malignancies (e.g. testicular cancer, small cell lung cancer, Hodgkin and non-Hodgkin lymphoma)
8. Spilling bone luggage: topoisomerase inhibitors can cause myelosuppression
9. Immunosuppressed cane: topoisomerase inhibitors can cause immunosuppression
10. Losing hair: topoisomerase inhibitors can cause alopecia
11. Toucan: topotecan and irinotecan (topoisomerase I inhibitors)
12. Single ponytail strand: topotecan and irinotecan inhibit topoisomerase I (single strand nick to relieve supercoiling)
13. Ripped cancer crab: topotecan treats ovarian cancer and small cell lung cancer; irinotecan treats colon cancer
14. Spilling bone luggage: topoisomerase inhibitors can cause myelosuppression
15. Loose bird stool: topotecan and irinotecan can cause severe diarrhea





Vincristine, Vinblastine, Paclitaxel

1. Christine in vines: vincristine (cytotoxic vinca alkaloid)
2. Breaking spindle vines: vinca alkaloids (e.g. vincristine, vinblastine) inhibit microtubule production and mitotic spindle assembly
3. Blasting vines: vinblastine (cytotoxic vinca alkaloid)
4. Cracked cancer crab: vinca alkaloids treat many hematologic and solid malignancies (e.g. leukemias, lymphomas, pediatric tumors, breast cancer, and germ cell cancer)
5. Neuropathic stockings and gloves: vincristine can cause neurotoxicity (e.g. peripheral sensory neuropathy)
6. Plunger: vincristine can cause autonomic dysfunction (e.g. paralytic ileus, constipation)
7. Bald: vinca alkaloids (e.g. vincristine, vinblastine) can cause alopecia
8. Tarzan: taxanes (e.g. paclitaxel, docetaxel, cabazitaxel – cytotoxic plant alkaloids)
9. Stabilizing the vine: taxanes enhance microtubule production and prevent their degradation → improper mitotic spindle function
10. Bald: taxanes (e.g. paclitaxel) can cause alopecia
11. Neuropathic glove: taxanes can cause neurotoxicity (e.g. peripheral sensoryneuropathy)
12. Broken marrow: drugs that affect microtubule function (e.g. vinca alkaloid, taxanes) can cause myelosuppression (especially vinblastine)
13. “M” shape in vines: drugs that affect microtubule function (e.g. vinca alkaloids, taxanes) block the M phase of athe cell cycle (mitosis)



Imatinib, Erlotinib, Sorafenib, Sunitinib, Vemurafenib

1. Broken nib: "-nib" suffix of small molecule kinase inhibitors (e.g. imatinib, erolotinib, vermurafenib)
2. Inhibited tire swing: tyrosine kinase inhibitors ("-tinib" e.g. imatinib, erlotinib, sunitinib)
3. Imitating: imatinib (small molecule tyrosine kinase inhibitor)
4. Cracked crab: small molecule kinase inhibitors treat a variety of hematologic and solid malignancies (e.g. imatinib treats CML)
5. Copious pink, white, and blue granules: chronic myeloid leukemia (CML) (increased levels of mature granulocytes – eosinophils, neutrophils, basophils)
6. BREAKABLE: imatinib blocks the tyrosine kinase domain of the BCR/ABL fusion protein (in CML)
7. Philadelphia, Pa: translocation between chromosomes 9 and 22 → BCR/ABL oncogene on chromosome 22 (Philadelphia chromosome)
8. Congress kit: imatinib blocks the c-kit tyrosine kinase (in GIST)
9. Crab buttons on belly: c-kit tyrosine kinase is found in gastrointestinal stromal tumors (GIST)
10. Baggy pantaloons: imatinib can cause fluid retention → ankle and periorbital edema
11. British Earl: erlotinib (small molecule tyrosine kinase inhibitor)
12. Earl Geoffrey: erlotinib blocks the epidermal growth factor receptor (EGFR) tyrosine kinase
13. Big lapel with crab badge: erlotinib treats solid tumors with EGFR overexpression (e.g. non-small cell lung cancer – NSCLC)
14. Spotty rash: erlotinib can cause a papulopustular acneiform rash
15. Muddy pantaloons: erlotinib can cause diarrhea
16. Rising sun: sunitinib (a small molecule tyrosine kinase inhibitor)
17. Soaring eagle: sorafenib (a small molecule tyrosine kinase inhibitor)
18. Inhibiting vegetables: sunitinib and sorafenib inhibits the vascular endothelial growth factor receptor (VEGFR) tyrosine kinase
19. Flank crab buckles: sunitinib and sorafenib treat cancer with VEGFR overexpression (e.g. renal cell carcinoma)
20. Callused and sunburned: sunitinib and sorafenib can cause hyperkeratosis and skin rashes
21. Bleeding wound: VEGF-targeted therapies (e.g. sunitinib, sorafenib) are associated with an increased risk of hemorrhage
22. Venom: vemurafenib (a small molecule kinase inhibitor)
23. B. Fra: vemurafenib blocks B-Raf kinase
24. Disseminated ink: vemurafenib treats V600E BRAF positive malignant melanoma





Rituximab, Cetuximab, Bevacizumab, Alemtuzumab, Trastuzumab

1. Chimera sigil: rituximab and cetuximab are chimeric monoclonal antibodies
2. Pulling down antibody archer: rituximab depletes B cells (binds CD20)
3. Grabbing "XX" straps: rituximab binds CD20 on B-cells
4. Chronic tapestry with antibody archers and T knights: rituximab treats chronic lymphocytic leukemia (CLL)
5. Rheumatic lantern: rituximab treats rheumatoid arthritis (disease modifying anti-rheumatic drug – DMARD)
6. Torn antibody: Rituximab is useful for immunosuppressive therapy (e.g. microscopic polyangiitis, Wegener's granulomatosis)
7. Immunosuppressed cane: rituximab can cause immunosuppression and increased risk of infection
8. White laurel leaves: rituximab may be associated with a higher risk of progressive multifocal leukoencephalopathy (PML)
9. Swollen cherub with ivy: monoclonal antibodies can cause an infusion reaction (e.g. headache, fever, skin rash, pruritus, dyspnea, hypotension)
10. Delayed onset poisoning: chimeric antibodies (e.g. rituximab, rarely cetuximab) can cause serum sickness (e.g. fever, rash, arthralgia within 7-10 days)
11. Tusks: cetuximab (monoclonal antitumor antibody)
12. Giraffe: cetuximab binds the epidermal growth factor receptor (EGFR)
13. Tire swing: EGFR is a receptor tyrosine kinase
14. Cracked crab: cetuximab treats solid tumors (e.g. colorectal cancer, squamous cell carcinoma)
15. Red spots: cetuximab can cause a papulopustular acneiform rash
16. Beverage lady: bevacizumab (monoclonal antitumor antibody)
17. Chopped vegetables: bevacizumab binds VEGF
18. Chopping vessels: bevacizumab inhibits growth of blood vessels in tumors (binds VEGF)
19. Cracked crab: bevacizumab treats metastatic tumors (e.g. colorectal cancer, squamous cell carcinoma)
20. Wet center of retina pillow: bevacizumab treats wet macular degeneration
21. Blood spatter: bevacizumab can cause bleeding
22. Ice clots: bevacizumab increases the risk for thrombotic events
23. Alms: alemtuzumab (monoclonal antitumor antibody)
24. Pulling down antibody archer and T knight: alemtuzumab depletes B and T cells (binds CD52)
25. 52 pattern: alemtuzumab binds CD52 on B and T cells
26. Chronic tapestry with antibody archers and T knights: alemtuzumab treats chronic lymphocytic leukemia (CLL)
27. Tapestry weaver: trastuzumab (monoclonal antitumor antibody)
28. Tire swing: HER2 is a receptor tyrosine kinase
29. Her 2 babies: trastuzumab binds epidermal growth factor receptor 2 (HER2, c-erbB2)
30. Crab bra: trastuzumab treats HER2 positive breast cancer
31. Unraveling heart: trastuzumab can cause cardiotoxicity (e.g. decreased LVEF, heart failure)

Cardiac Pathology



1.1 - Myocardial Response To Ischemia

1. Oxidative forge: cardiac myocytes generate energy almost exclusively through oxidative phosphorylation
2. Oxygen bellows: myocytes extract a higher percentage of oxygene from blood than any other tissue in the body → cornorary sinus has most deoxygenated blodd
3. DIlated red exhaust pipe: coronary endothelial cells produce NO, a gaseous melecule that promotes coronary vascular vasodilation
4. GruMPy blacksmith: NO ↑ cyclic GMP inside arteriolar smooth muscle cells ↓ coronary vasodialtion
5. Dancing with dilated red sleeves: adenosine is an important vasodilator of coronary arteries
6. Flat autoregulation graph: autoregulation(via NO and adenosine) normally keeps the coronary blood flow constant across a range of BPs by regulatio coronary vasodilation
7. Glowing harp: well oxygenated myocardium
8. Gunky constricted exhaust pipe: coronary atherosclerosis obstructs luminal flow AND inhibits endothelial cell release of NO and other vasodilation
9. Broken autoregulation gauge: coronary atherosclerosis interferes with autoregulation mechanism and ability to maximally vasodialte
10. Cold inner harp surface: subendocardium becomes ischemic first
11. "Supply and demand": mismatch between myocardial oxygen demand and coronary oxygen supply› ischemic heart disease
12. Pushing load(queen pushing blacksmith): ^ afterload on the heart (e.g. due to aortic stenosis or HTN)
13. Stenotic aortic princess hat and high pressure steam: aortic stenosis and HTN ↑ afterload →↑myocardial o2 demand
14. Concentric conch shell: concentric myocardial hypertrophy(due to ↑ afterload)→ ↓coronary O2 supply
15. Diamonds on left(her left) the LEFT ventricle recives coronary blood flow during diastole
16. Raised heart watch and falling diamond: tachycardia ↓ time in diastole ›coronary flow to LEFT ventricle ›myocardial ischemia
17. Running blacksmith:: excercise ↑ myocardial o2 demand (tachycardia and ↑contractility) and ↓ coronary o2 supply (tachycardia)
18. Little constricted coronary crown: cocaine causes coronary artery vasoconstriction → ↓coronary o2 supply
19. Jutter coca mug: cocaine ↑ myocardial o2 demand (tachycardia and ^ contractility)
20. Pale complexion: systemic hypoxia ↓ coronary o2 supply (e.g. hypotension, shock, anemia and carbon monoxide poisoning)
21. Cardia Myocyte
22. 3 falling P batteries: within seconds, ishemic myocardial cells switch from aerobic to anaerobic glycolysis› depleted ATP
23. Floppy harp strings: myofibril relaxation seen within Seconds(depleted ATP in the cardiac myocyte)
24. Puffy harp repairman with candybard and ball of string: early pathologic changes in sichemic myocyte include cellular and mitochondrial swelling, glycogen depletion, and clumping of chromatin (REVERSIBLE cell damage)
25. Repairing harp with new red string: cellular swelling and other early changes are reversible with early reperfusion
26. "Repaired in 30 min or less": irreversible damage to cardiac myocyte after ~30 minutes to ischemia
27. Raptured and vacuolated mitochondrial lute: mitochondrial vacuolization or membrane rupture is a sign of IRREVERSIBLE cell injury
28. Spilling ChicKen and T-bone steaks: myocyte cell membrane breakdown (IRREVERSIBLE cell damage) → release of troponin and creain kinase
29. Stunned girl receiving repair harp: STUNNED myocardium (viable myocytes do not immediately return to full activity) can last a few hours to days after reperfusion

Cardiac Pathology



1.1 - Myocardial Response To Ischemia

30. Hypercontracted lute: buildup of intracellular Ca during ishemia → hypercontracture and cytoskeletal damage on reperfusion (REPREFUSION INJURY)
31. Sparks and fire caused by repairman: reperfusion results in local release of free radicals, influx of inflammation, and further irreversible mitochondrial damage (REPERFUSION INJURY)
32. CIHD
33. Old grandfather clock: Chronic ischemic heart disease(aka "ischemic cardiomyopathy")→progressive heart failure
34. Patched-up and discarded lute frame: Chronically ischemic hearts usually have evidence of "patchy fibrosis" from previous healed infarcts (more rarely, chronic sever CAD w/o infarct can also cause chronic ischemic heart disease
35. Floppy heart balloon above diluted lut frame: Chronic cardiac ischemia→ systolic heart failure with eccentric hypertrophy
36. Hibernating bear: chronically ischemic hearts may contain nonviable myocardial cells along with "hibernating" viable myocardial cells
37. Waking hibernating bear with vacular hose: revascularize a chronically ischemic heart to reactive viable myocardial cells (reverse systolic dysfunction)

Cardiac Pathology



1.2- Rupture at the Stables- Stable Angina, Vasospastic Angina, ACS

1. **Anvil: angina**
2. **"70"-shaped tongs**: fixed coronary plaques causing **>70%** stenosis will present clinically (**stable angina**)
3. **Clutching chest over anvil**: **stable** angina (**predictable** episodes chest pain and pressure worse with exertion)
4. **Plaques secured above stable**(one above anvil): **stable** fixed atherosclerotic plaques cause **stable** angina (**predictable** symptoms)
5. **Dark spot on inner horseshoe surface**: stable angina involves transient **subendocardial** ischemia in inner surface of the heart
6. **Tired blacksmith with armor on left arm**: typical symptoms of **stable** angina include chest pressure/pain which can radiate to l**eft** arm and chin, **diaphoresis** and **dyspnea** (elderly diabetic, female pts may have minimal atypical sx)
7. **Relaxing on nitro crate**: **stable** angina is relieved with rest or **nitroglycerine** (usually <30 min) = dec preload
8. **Sleeping stable boy**: vasospastic (Prinzmetal) angina symptoms occur at rest, more commonly at night
9. **Twisted red sleeve**: vasospastic angina is caused by transient coronary vasospasm
10. **Startled awake:** the paroxysmal vasospasm seen in vasospastic angina is likely due to smooth muscle **hyper-reactivity** in the coronary artery wall
11. **Plaque mounted above stable:** paroxysmal vasospasm seen in vasospastic (prinzmetal) angina common occurs over a **stable** atheroscleotic coronary plaque (may occur in disease free vessels)
12. **Relaxing on nitro box:** nitroglycerin improves symptoms of vasospastic angina = relax coronary smooth muscle
13. **"Calci-Yum" icecream:** calcium channel blockers are the **1st-line therapy** for long term management of vasospastic (prinzmetal) angina (vasodilated and ↓spasticity)
14. **Smoker**: cigarette smoking is a major risk factor for prinzmetal angina (encourage pts to quite)
15. **Sumo stable manager with cocoa kid:** sumatriptans and sympathomimetic agents (e.g. cocaine, amph) can precipitate vasospastic angina
16. Entire Thickness of horseshoe dark: vasospastic (prinzmetal) angina involves transient **transmural** ischemia (**ST elevation** on ECG = transmural involvement)
17. ELEVATED StreeT sign: **vasospastic angina** presents with transient **ST segment elevation** in ECG leads that correspond to the region of **ischemic** myocardium
18. Ruptured stable: plaque rupture
19. **Thrombotic** hay released toward home **plate:** atheromatous plaque rupture lead to exposure of thrombogenic substances (ie. Tissue factor, Collagen) → **platelet** and coagulation pathway activation → **luminal thrombus** formation
20. **Repairing ruptured fence:** plaque rupture is quite common (repeated cycles of plaque disruption and repair are usually **subclinical!**); cycle of healing/rupture is what predisposes to ACS
21. **"ACS" horse rupture through gate**: Acute Coronary Syndrome (ACS) includes unstable angina, NSTEMI, STEMI (**destabilized** coronary plaque →occlusive thrombus → cardiac ischemia or infarction)
22. **Disrupted plaque: ACS** (e.g. Unstable angina) occurs due to **acute plaque destabilization** (rupture, erosion)
23. **Hay scattered From rupture:** Plaque rupture/erosion exposes prothrombotic surface →occlusive luminal **thrombus** →cardiac ischemia or infarction (ACS)
24. **Flipping coin:** we have no good way of predicting which plaques are vulnerable to rupture (NOT necessarily the largest or most occlusive)
25. **Sweeping up thrombotic hay:** Unstable ANGINA is caused by a **transient** (or only partially occlusive) thrombus
26. **Partially filled lumen:** UNSTABLE ANGINA is caused by a **partially occlusive** (or transient) thrombus
27. **Falling anvil**: UNSTABLE ANGINA presents with **unstable** symptoms (new onset angina, angina with less exertion or at rest)
28. **Broken heart string**: during **NSTEMI**, ischemia progresses to **infarction** and myocardial cell death
29. **Disrupted plaque: myocardial infarction** (NSTEMI and STEMI) occurs due to **acute plaque destabilization** (rupture, erosion)
30. **Falling StreeT sign**: **NSTEMI** often presents with **ST segment depressions** in ECG leads that corresponds to the region of **infarcted** myocardium
31. **Sweeping up thrombotic hay**: **NSTEMI** is caused by a **transient** (or only partially occlusive) thrombus
32. **Partially filled lumen of lute: NSTEMI** is caused by a **partially occlusive** (or transient) thrombus

Cardiac Pathology



1.2- Rupture at the Stables- Stable Angina, Vasospastic Angina, ACS

33. **Dark spot on inner horseshoe surface:** NSTEMI involves **subendocardial** region of infarction/cell death (**ST depressions** on ECG = subednocardial involvement)
34. **ELEVATED StreeT sign: STEMI** presents with **ST segment elevation** in ECG leads that correspond to the region of **infarcted** myocardium
35. **Broken heart string:** during **STEMI,** ischemia progresses to **infarction** and myocardial cell death
36. **Completely filled lumen of lute**: **STEMI** is caused by a **fully occlusive** (or prolonged) thrombus
37. **Full thickness of horseshoe dark:** STEMI involves **transmural** infarction/cell death (**ST elevation** on ECG=transmural involvement)
38. **T weather vane:** hyperacute **T waves** within seconds corresponding to area of ischemia (STEMI progression of ECG changes 1of4)
39. **Elevated ST:** „tombstone" shaped **ST elevation** within minutes, corresponding to the area of **infarction** (STEMI progression of ECG changes 2of4)
40. **„Q" lasso**: after initial ST changes, **negative Q waves** develop **corresponding to the area of necrosis** (STEMI progression of ECG changes 3of4)
41. **Inverted T shadow:** after initial ST changes, **T wave inversion** (STEMI progression of ECG changes 4of4)
42. 

43. **Pathologically old stable keeper**: pathologic Q waves persists (area of previous infarct)
44. **Thatcher with bundle of stick(on the roof):** new -onset of LBBB is also diagnostic of STEMI (LBB is supplied by LAD)
45. **Falling StreeT sign: unstable angina** will present with **ST segment depressions** in ECG leads that correspond to the region of **ischemia**
46. **Dark spot on inner horseshoe surface:** unstable angina involves **sunendocardial** ischemia (**ST depressions** on ECG = subendocardial involvement)
47. **Grillmaster holding T-Bone steak:** Death and rupture of cardiac myocytes in NSTEMI and STEMI leads to spillage of cellular enzymes, one of which is **Troponin**
48. **T-bone steak**: Troponins are serum markers used to detect infarction (dx NSTEMI n STEMI) (Troponin **I** is more SPEC**I**F**I**C for cardiac muscle damage, troponin **T** is more SENSI**T**IVE)
49. C**K**ick**K**en bucked „now with More Biscuits!": CK, isoform MB **(CKMB)** is a cardiac -specific serum marker used to detect infarction (dx NSTEMI and STEMI)
50. **T-bone 24/7**: serum troponin lvls peak ~24hr after MI and remain ↑ for ~7 days
51. „Good the **next day**": serum CK-MB levels peak in ~24 hours and fall over the next ~24 hrs
52. „try **rehydrated**": serum CKMB can be used to dx **reinfarction** (relatively short time course of ↑ and return to baseline

Cardiac Pathology



1.3 Ischemia Is coming- Acute MI and Post MI Timeline

1. -Clinical Presentation of MI:
   a. -Crushing substernal chest pain/pressure radiates to jaw/l. arm **(angina anvil)**
   b. -Assoc. with anxiety, dyspnea, diaphoresis **(nervous jester)**
   c. -Symptoms last >30 min, not relieved by rest or Nitro **(discarded pills)**
2. -OCCLUDING LEFT SYSTEM (most often)
   a. -MI with LAD **[left anterior braid/lady]**-> Left sided heart failure (myocardial ischemia-> decreased ventricular systolic function) **[floppy balloon]**
      i. -Ischemia of anterior wall of L vent, anterior 2/3 of IV septum, and apex
      ii. -Flash pulmonary edema and bibasilar crackles **[bubbles]**
      iii. -Dyspnea **[breath knocked out]**
      iv. **-S4 heart sound [stiff S4 chair]**
1. -Ischemic heart tissue becomes stiff and noncompliant
   v. -Can cause to cardiogenic shock (hypotension and complete CV collapse) **[Lightning bolt heart shield]**
3. -Ventricular Ischemia from MI can cause conduction abnormalities **[dead jester with quivering heart accordion]**
   a. **-Fatal Ventricular Arrhythmias** (Vtach, Tfib)-> Sudden Cardiac Death
4. -OCCLUDING RIGHT SYSTEM

a. -40% of MI's are occlusion of RCA **[right hand of king]**
   i. -Affects AV/SA nodes **[notes]**
1. -Bradycardia/sick sinus syndrome **[falling heart watch]**
2. -Heart Block **[shield]**
   ii. -RCA perfuses R ventricle, posterior 1/3 of IV septum and posterior LV **[right hand behind back]**
1. -II/III/aVF Leads **[on shield]**

a. -inferior leads

iii. -Right Sided Heart Failure **[balloon]**
1. -Myocardial Ischemia-> Decreased Ventricular systolic function
2. -Jugular Venous Distention **[blue jug]**

iv. -Can cause cardiogenic shock **[heart/lightning sigil]**
1. -hypotension/CV collapse

5. **<u>Histo/Path Timeline: Post MI</u>**
6. **-Microscopic**
7. -0-4 hrs [4 clock dongles on hat]

a. -Very few microscopic or gross changes [normal tunic]

8. -4-12 hrs [half a day sun mask]

a. **-Wavy fibers** [wavy tassles]- On shirt
   i. -non-contractile muscle fibers being pulled by adjacent contractile fibers

b. **-Edema/punctate hemorrhages** [blood spots on floor]

c. -Coagulation Necrosis (teetering on edge) [skull dungeon]
   i. -very minor signs

9. -12-24 hrs [full sun mask]

a. **-Coagulation necrosis full visible [in pit]**
   i. -cells dead/lack nuclei - preserved structural outline

b. **-Contraction bands [tunic]-[hyper contacted arms]**
   i. -linear densities
   ii. -Return of blood flow -> abnormally high intracellular Ca-> hypercontraction of dead cardiac myocytes

c. **-Neutrophils** [first responders]

10. -Days 1-3 [3 suns on shirt]

a. -Extensive Coagulation Necrosis [falling WAY in]

b. **-Neutrophils** become more abundant
   i. -Infiltrating blue between pale dead myocytes [shirt]

c. -Grossly- **Whitish Tan and Pale**

d. **-COMPLICATION**
   i. **-Early Onset Pericarditis** [heart shaped guitar case

Cardiac Pathology



1.3 Ischemia Is coming- Acute MI and Post MI Timeline

1. -3 days post MI-> chest pain-> but its sharp, and increases on swallowing or breathing (pleuritic; friction rub) [shark tooth necklace]
2. -VS viral/autoimmune: NOT DIFFUSE, inflammation only overlies infarction

11. -Days 3-14 (half a month) [half moon shield]

a. -Invasion of **Macrophages** [macro cage]
   i. -Even more little blue cells

b. **-Granulation tissue** [granny tissue] -> prom day 10-14
   i. -Activated myofibroblasts and vascularity [vask dress]
   ii. -Precursor to scar tissue

c. **-COMPLICATIONs**
   i. **-Rupture**

1. **-Papillary Muscle** [ruptured string holder]

a. **-Mitral Regurg** [regurg/2 leaves hat]
   i. -Holosystlic Blowing Murmur- [systolic spray]
   ii. -Acutely Worsening Dyspnea/Pulmonary Edema

b. -Posteromedial Pap Muscle
   i. -Supplied solely by PDA (90% from RCA)[wonky hat]

c. -3-14 days

2. **-Interventricular Septum** [rupt tamborine]

a. -More common with Left Occlusion

b. -Necrosis/Rupture
   i. -Immediate **L-> R shunt**
   ii. -Holosystolic murmur
   iii. -NO pulmonary symptoms (vs MR)

3. **-Left Ventricular Free Wall** [side of lute ruptured]

a. -Usually progress rapidly to HF and death

b. -Obstruction of LEFT [he's furthest left]

c. -Rapidly Fatal **Hemopericardium and cardiac tamponade** [guitar case filling with wine]
   i. -Tamp- muffled heart sounds, JVD, systemic hypotension
   ii. -Any form of rupture= Hypotension and Cardiogenic Shock [heart/lightening shield]

12. -After 14 days [after moon shield]

a. **-Fibrotic Scar Tissue** [scar on face]
   i. -Fibroblasts (activated by macrophages), deposit collagen and fibrotic tissue
   ii. **-DECREASED** risk of rupture [cork bounces right off]
   iii. -Grossly: Greyish/White
   iv. -Acellular under Microscope

b. **-COMPLICATION**
   i. **-Conduction Abnormalities and Fatal Ventricular Arrhythmias** [shaking heart accordion]

1. -Sudden Cardiac Death [death mask like very first dead guy]

a. -reason people die before people ever reach hospital
   ii. **-Loss of Myocardial Contractile Function** [floppy balloon]

1. -Eccentric Hypertrophy-> Chambers Dilate

13. -Long Term: Weeks to Months [many moons]

a. **-Dressler's Syndrome** [cross dresser]
   i. -Auto-Immune, Late Onset, Pericarditis [red/inflamed heart case]

1. -Formation of IgG autoantibodies against Myocardial Antigens exposed during acute MI [Ab arrows around him]

   ii. -GLOBAL infection of pericardium
   iii. -Friction rub [friction lines]
   iv. -Onset of sharp chest pain, worse with inspiration [shark tooth necklace]
   v. -Fever/Leukocytosis [red dress]
   vi. -Resolves with NSAIDS

b. **-Ventricular Wall Aneurysm** [peasant caving in tent]
   i. -Normally 4-8 wks
   ii. -Thinning of transmural scar

1. -Outpouching of Ventricular Wall

2. -Can cause systolic HF [balloon]

a. -Stroke volume diminishes
   iii. -Blood Stasis and Mural Thrombus Formation-> Embolization [birds nest in wall, sending out little bird poops] **-Ischemic Stroke**

Cardiac Pathology



2.1 - Congestive Heart Failure - Pathophysiology

1. Failing heart balloon: congestive heart failure
2. Systolic spray: systolic HF (ejection dysfunction)
3. Falling cake fraction: HF with reduced ejection fraction (systolic HF)
4. 40 shaped cake server: ejection fraction <40% (reduced ejection fraction)
5. Ultrasound horn: use cardiac ultrasound to measure ejection fraction
6. Weak arm lifting heart: reduced cardiac contractility → reduced ejection fraction (systolic HF)
7. High pressure balloon : ↑end diastolic PRESSURE (seen in systolic HF)
8. High volume balloon: ↑ end diastolic VOLUME (seen in systolic HF)
9. Diamond tiara: diastolic HF
10. Difficulty filling glasses: diastolic HF (filling dysfunction)
11. 55 cake topper: ejection fraction >55%(preserved ejection fraction)
12. Lifting cake fraction: HF with perserved ejection fraction (diastolic HF)
13. Fallen compliance papers: reduced ventricular compliance seen in diastolic HF
14. High pressure balloon: ↑ end diastolic PRESSURE with normal diastolic volumes(seen in diastolic HF)
15. Dysfunctions that cause systHF
16. Clogged coronary crown: cornoary artery disease (CAD) can cause cardiac ischemia →↓ contractility → systolic HF
17. Broken heart string: ACS (e.g. Acute myocardial infarction) can cause myocardial scarring → ↓ contractility→ systolic HF
18. Dilated heart sac: dilated CMP causes ↓ contractility→ systolic HF
19. Regurgitating drink: valvular insufficiency (e.g. Aortic or mitral regurg) can cause volume overload → systolic HF
20. Unbuttoned shirt: LtoR shunt (e.g. VSD) can casue volme overload → systolic HF
21. Dysfuctions that cause diasHF
22. Steonotic aortic hat(she pulls down her hat=stenosis): AS can cause pressure overload →ventricular hypertrophy→ diastHF
23. High pressure steam: long standing HTN can cause pressure overload →LVhypetrophy→diastolicHF(most common cause)
24. Big obstructed bagpipes: hypertrophic obstructive CMP causes ventricular hypertrophy →diasHF
25. Heart in restricted net: restricted CMP causes a non-compilant ventricle→diasHF
26. Clogged coronary crown: coronary artery diasease (CAD) can cause cardiac ischemia→ noncompliant ventricle→diasHF
27. Constricting bow(heart like gift) constricitve pericarditis causes a non-compliant ventricle→diasHF
28. Histology systHF
29. Pulling load(pulling by a jacket): sysytolic HF is associated with↑PRELOAD(volume-overload states)



2.1 - Congestive Heart Failure - Pathophysiology

30. Long eccentric eel: eccentric hypertrophy (sarcomers add in series) in response to volume-overload states→systolicHF
31. Dilated cave: systolic HF is assocaited with ↑ chamber size (due to eccentric hypertrophy)
32. Histology diasHF
33. Pusjing load: chronic HTN and valvular stenosis cause diastolic HF by ↑ afterload
34. Concentric conch shell: concentric hypertrophy (saromers add in parrallel) in response to ↑ afterload (e.g. HTN senotic valve) →diastHF
35. Small shell openin:diastHF with concentric hypertrophy is associated with ↓chamber size and ↑wall thickness
36. Bulgind septum(heart tube): HOCM casues distHF with isolated spetal hypertrophy
37. Normal cardiac bow: restricted CMP and constrictive pericardidis cause diastHF with normal chamber size and wall thickness
38. Dilated BNP blimp: brain natriuteic peptide(BNP) is released by streched CMP in the ventricles
39. ANP flag: atrial natriuertic pepitde(ANP) is released by streched CMP in the atria
40. Dilated sleeves: ANP and BNP cause vasodilation → ↓afterload(↓SVR)
41. Salty Na peanuts in water: ANP and BNP promote natriuresis→diuresis→↓preload
42. Falling rain umbrella:ANP and BNP ↓reninr production→↓aldosterone→natriuresis/diuresis
43. Pinched efferent straw: ANP and BNP causes efferen arteriolar vasoconstriction→increase GFR→natriuresis/diuresis
44. Physiological changes in response to HF
45. Increased ground filtration rate(waiter counting his tips) ANP and BNP ↑GFR
46. „OUTPUT LOW" HF is associated with ↓ CO→ compensatory mechanism
47. Fight or flight activator: ↓CO causes ↑sympathetic activation →↑HR and cardiac contractility
48. Twisted arterial sleeve: ↓CO causes ↑sympathetic activation →vasoconstriction(↑SVR)
49. Rain umbrella and tight red suspenders: ↓CO causes ↑renin activity →↑ antiotensin II→ vasocontriction (↑SVR)
50. Pusing load (guy with umbrella pushing on the door) sympathetic activation ↑afterload (vasoconstriction)
51. Wet rain umbrella and salty minerals: ↓CO causes ↑reninr activity → ↑aldosterone → salt and water retention
52. Water refill: ↓ CO causes ↑ ADH activity → ↑free water retention
53. Wet lifer preserved and peirpheral pants: compnsatory mechanism of HF (e.g. RAAS activation, ADH activation) axacerbate pulmonary and peirpheral edema
54. „REMODELING": long-term neurohormonal activation (RAAS, ADH, sympathetic) + ↑hemodynamic stress (HR/contractility, vasoconstriction, extracellular volume) →deleterious cardiac remodeling

Cardiac Pathology



2.2 - Congestive Heart Failure - Clinical Manifestations

1. Failing heart balloon: CHF
2. Left side HF(left side of sketch)
3. Wet life vest prince: left-side heart failure
4. Wet pulmonary vest: pulmonary edema: lef-sided HF)
5. Pink sea foam in abalone shells: frothy pink transudate on the intra-alveolar surface (left-side HF)
6. Rusty macro-cages: hemosiderin-laden alveolar macrophages – HF cells (lside HF)
7. Restrictive corset: pulmonary edema reduces pulmonary compilance
8. Difficult breath: HF can cause dyspne with exertion
9. „C" hook fishing line: pulmonary C fibers sense pulmonary edema →dyspnea
10. Reclining into water: orthopnea (left sided HF)
11. Gasping awake(guy in canal): paroxsmal nocutral dyspnea (PND- left sided)
12. Bilateral slurping snorkles: bibasilar inspiratory crackles(left-sided HF)(sound like slurping soda)
13. Wheezy part blower: peribroniach edema causes wheezing (left sided HF)(known as like „cardia asthma")
14. Skull and X bones: chest xray(imaging for suspected left sided HF)
15. White branches over the top sails: cephalization of the pulmonary vessels on CXR (left sided HF)
16. infiltrating fog: pulomnary edema looks like fluffy bilater („batwing" shape) opacites on CXR)(left sided HF)
17. Curly letter B: Kerler B lines (fluid accumulation between lobas) on CXR(left sided HF)
18. Shadow of captain on sail: air bronchogram(dark airwat agians opacified interstitium) on CXR (left sided HF)
19. Big heart: cardimegaly on CXR (HF)
20. Cardiac exam
21. „slushi3": s3 hear sound(more common in systolic HF) (comes after s1 and s2) sound like „slushing in", „slushing in"„slushing in"„slushing in"„slushing in"„slushing in"
22. Stiff s4 chair: S4 heart sound (more common in diastolicHF)(comes before s1 and s2)
23. sound like „stiff wall", „stiff wall", „stiff wall", „stiff wall", „stiff wall", „stiff wall"
24. Systolic spray murmur: left sided HF can present with a systolic murmur(mitral regur)
25. Regurgitating mitral hat jester: dilation of mitral annulus→ mitral regurg(left sided HF)
26. Dilated balloon: dilated atrium(due to left-sided HF(when mitral valve is open up and blood going in wrod direction→chronic dialtion od LA)
27. Irregulary irregular signal: Afib(due to atrial dilation in HF)



2.2 - Congestive Heart Failure - Clinical Manifestations

28. Left side HF can damage to endothelium lining of pulmonary vasculature
29. Damaged NO exhaust: left-sided HF causes dmg to the pulmonary vascular endothelium → ↓NO→vasoconstriction
30. Twisted arterial shirt: dmg to the pulmonary vacular endothelium →↓NA and ↑endothelins →vasoconstriction
31. That→pulmonary vasculature to remodeling→
32. Smooth muscular shark tattoo: pulmonary vascular remodeling→collagen deposition (intimal hypertrophy) and smooth muscle cell proliferation(medial hypertrophy)
33. Tense pulmonary tree: left-sided HF →pulmonary artery HTN→Right sided failure(most common cause)
34. Right side HF
35. Cork on the bottle: cor pulmonale (right-sided HF due to pulmonary HTN)
36. Embolic see:cucumbers: chronic pulomanry emboli→cor pulmonale(right-sided HF)
37. Embolic saddle: a saddle pulmonary embolism→ right heart strain and failure
38. Little mirmid pushing her father=pushing load: RV works against an ↑ afterload (cor pulomale)
39. Right-sided clinical findings
40. When RV fails →pressure ↑ and stretch open fibrous ring attached to tricuspid valve→tricuspid regurgitating
41. Regurgitating on three peaks: dilation of tricuspid annulus→tricuspid regurg (right-sided HF)
42. Systolic spraw murmur: right-sided HF can present with systolic murmur (tricuspid regurg)
43. More pressure in RA→backup to venous system
44. Distended blue jug: jugular vein distention (JVD) seen in right-sided HF
45. Liver knocking over distented jugular hepato-jugular reflux(right-sided HF)(pressue to RUQ)
46. Kaussmal sign(when you breath in lung sucks in blood into pulmonary vasculature, all this blood is coming from right side of heart, so the JV empty as well. This is normaly seen as ↓Jugular vein distention during inspiration
47. Cookie smell from distended jug: Kussmaul sign (JVD ↑ during inspiration) seen in right-sided HF
48. Swollen sweat pants(mirmid's): peripheral edema of lower extremities (right-sided HF)
49. Wet pleural shirt: pleural effusion (right-sided HF)
50. Wet heart case: pericardial effusion (right-sided HF)
51. Course III: zone3 (centrilobular) necrosis due to hepatic venous congestion (right-sided HF)
52. Nutmeg sprinkled liver: centrilobular necrosis apprears as „nutmeg liver” on gross pathology
53. Painful liver spot: hepatic congestion causes painful hepatomegaly (right-sided HF)
54. High pressure porthole: portal HTN seen in right-sided HF
55. If portal pressure ↑→fluid leaks out into peritoneal cavity
56. swollen inner tube: ascites due to portal HTN (right-sided HF)



3.1 - Dilated and Restrictive Cardiomyopathy

1. Dilated heart sack: dilated CMP
2. Idiot sack racer: dilated CMP is most commonly idiopathic
3. Dilated heart sack on fire: myocarditis (e.g. Due to viral idnfection) can cause dialted CMP
4. Systolic spray: dilated CMP causes SYSTOLIC HF
5. Failing heart balloon: dialted CMP causes contractile dysfunction →SystolicHF
6. Viral lantern igniting sack: viral myocarditis (e.g. Due to coxackie virus type B) can cause dilated CMP
7. Preceding viral lanterns: viral myocarditis can be preceded by flu-like symptoms (e.g. Fever, runny nose, myalgia)
8. „sCottisH GAmeS": Chagas dis can cause dilated CMP
9. Genetic pedigree tartan pattern: genetic mutation are 2nd most common cause of dilated CMP
10. Domino clap: heriditary dilated CMP is usually cuased by an autosomal dominan mutation
11. Cytosekelton sack pattern: genetic causes of dialted CMP include mutation in cytoskeleton protein
12. Duchenne and Becker clans: Duchenne and Becker muscular dystrophy (Xlinked) can cause dilated CMP
13. „Destroy" Duchene and Becker muscular dystrophy are cuased by a mutation in the protein dystrophin (connects myocyte cytoskeleton to the extracellular matrix)
14. „box-o-rubies" doxorubicin (anthracycline chemotherapeutic) can cause free radical dmg and cadriotoxicity →dilated CMP
15. Alcoholic sack racer:alcohol abuse can cause cardiotoxicity(due to EtOH and acetaldehyde)→dilated CMP
16. Bunch of blueberries: alcohol abouse can cause wet beriberi(alcohol to thimaine def) →dilated CMP
17. Pregnant sack racer: pregnancy can cause dilated CMP(peripartum CMP)
18. Sack with Iron weight: hemochromatosis can cause iron deposition in cardiomyocytes→dilated CMP(or restrictive)
19. Cardiac examination of dialted CMP
20. „slushi3" slushy: dialted CMP can present with an s3 heart sound
21. wall nestes: mural thrombie may be present in dialted CMP→thromboembolism and embolic stroke
22. CXR may show ↑silithous
23. Bull horn sound: USG can be used to dx dilated CMP (enlarged heart with dialtion of all 4 chamber)
24. Heart in restricitve net: restrictive CMP
25. Falling compilance rulebook: restricitve CMP is associated with ↓ ventricular compilance
26. Diamond tiara: restricitve CMP causes DIASTOLIC HF(
27. difficulty filling glasses: diastolic HF (filling dysfunction)



3.1 - Dilated and Restrictive Cardiomyopathy

28. Stiff S4 chair: restrictive CMP can present with an S4 heart sound
29. Distended blue jug: JVD seen in restricitve CMP
30. Falling
31. Y" glass: restricitve CMP can present with a prominet Y descent (in the JVP waveform)
32. Cookie smell from distended jug: Kussmaul sign (JVD ↑ during inspiration) seen in restricive CMP
33. Causes of restricitve CMP
34. Armored lady in light chainmail: amyloidosis (e.g. Ligh chain or transthyretin deposition) can cause restricive CMP
35. Amorphous pink areas: endomyocardial biopsy shows areas of amorphous and acellular pink material in the myocardium (H&E stain)
36. Bright green skirt: cardiac amyloidosis shows apple-green birefriengance under polariazed light microscopy (congo red stain)
37. Soccer balls: sarcoidosis can cause restricive CMP(present with nonceasting granulomas presenting with multinucleated giant cells)
38. Iron weight toss: hemochromatosis can cause Fe deposition in cardiomyocytes → restrictive CMP(usually dialted) (blue face=prussian blue detection)
39. Spillin garbage truck: lysosoaml storage dis (e.g. Hurler's syndrome, Fabry's dis) can cause restricitve CMP
40. Scaly red dragon: scleroderma can cause restricitve CMP(systemi sclerosis)
41. Radiation shield: chest irradtion can cause fibrosis of the myocardium→restricitve CMP
42. Fibrous heart log: enomyocardial fibrosis (prevalent in tropical regions) can cause restricitve CMP
43. Firbour heart log with elastic band holding lose kilt in a youg boy: endomyocardial fibroelastosis (in infants) can cause restricive CMP



3.2 - Hypertrophic Cardiomyopathy

1. Big obstructed heart bag: Hypertrophic obstructive cardiomyopathy (HOCM)
2. Wide septal stripe on heart bag: the interventricular septum shows the most significant amount of myocardial hypertriphy in HOCM.
3. Obstructive knot: the massive IV septum in HOCM can obstruct blood flow out of the LV.
4. Difficulty filling glasses: massive septal hypertrophy in HOCM causes diastolic dysfunction.
5. Failing heart balloon: HOCM can cause diastolic heart failure.
6. Domino sporran: HOCM is caused by an AD mutation of sarcomere proteins.
7. Beta-myosin rope on pipes: HOCM is commonly caused by a gain-of-function mutation in sarcomere proteins (e.g. beta-myosin heavy chain, myosin-binding protein C, troponin T) -> increased byofilament activity and hypertrophy.
8. Disorganized Plaid pattern: the gain-of-function mutations in sarcomere proteins cause disorganized myofibrillar prolifferation.
9. Dead musician with quivering heart: aberrant myofibers cause aberrant conduction pathways -> fatal arrhythmias (eg. VT, VF) and sudden cardiac death.
10. Athletic sweatband on bagpipes player: HOCM usually manifests before puberty and is the most common cause of sudden death in young athletes.
11. Obstructive knot below valve: the obstruction to blood flow from the left ventricle in HOCM occurs below the aortic valve in the left ventricular outflow tract (LVOT).
12. Bicuspid jester hat blown forward: systolic anterior motion of the mitral valve (and its contact with the hypertrophied interventricular septum) causes LVOT obstruction in HOCM
13. Spilling on bicuspid hat: contact of the anterior leaflet of the mitral valve and the interventricular septum causes the mitral valve to remain open during systole → mitral regurg
14. Murmur from obstructed pipe: HOCM can present with a harsh, crescendo-decrescendo systolic murmur best heard at the left sternal border (caused by the LVOT obstruction)
15. Standing and straining bagpiper: valsalva and standing decrease preload → higher degree of LVOT obstruction → increased murmur intensity
16. Squatting leg raise: leg raise (when supine) and squatting increases preload and left ventricular size → smaller degree of LVOT obstruction → decreased murmur intensity
17. Quiet bagpipes: maneuvers that increase preload (e.g. leg raise, squatting) or increase afterload (e.g. squatting, handgrip) decrease the murmur intensity of HOCM
18. Pulling load: maneuvers that increase preload (e.g. leg raise, squatting) decrease the murmur intensity of HOCM



3.2 - Hypertrophic Cardiomyopathy

19. Grappling and squatting: squatting and handgrip maneuvers increase SBP and afterload → slow movement of blood through LVOT → decreased murmur intensity
20. Pushing load: maneuvers that increase afterload (e.g. squatting, handgrip) decrease the murmur intensity of HOCM
21. Stiff S4 chair: HOCM can present with an S4 heart sound (blood hitting the stiff noncompliant ventricle)
22. Angina anvil: HOCM can cause angina (hypertrophic tissue impedes subendocardial blood flow)
23. Sinking in quicksand: HOCM can cause syncope from non-lethal arrhythmia or temporarily decreased CO
24. Muted bugle: HOCM can be treated with beta blockers (decrease inotropy and chronotropy)
25. Floppy bass strings: beta blockers treat HOCM by decreasing cardiac contractility (decreased inotropy) → slow blood flow across the LVOT obstruction
26. Non-dairy Calci-Yum ice cream: nondihydropyridine calcium channel blockers treat HOCM by decreasing cardiac contractility (decreased inotropy) → slow blood flow across the LVOT obstruction
27. Pulling load: beta blockers and nondihydropyridine calcium channel blockers treat HOCM by decreasing HR → increased time in diastole and left ventricular PRELOAD → decreased LVOT obstruction
28. Avoid sinkhole: several medications are contraindicated in HOCM (e.g. drugs that decrease preload such as diuretics, nitrates, or dihydropyridine calcium channel blockers; and drugs that increase contractility such as digitalis or milrinone)
29. Dairy Calci-Yum ice cream: avoid dihydropyridine calcium channel blockers in HOCM (vasodilation decreases afterload → increased velocity of blood in LVOT → increased obstruction)
30. Dilated arterial sleeves: avoid vasodilators in HOCM (decreased afterload → increased velocity of blood in LVOT → increased obstruction)
31. Sinking nitro box: avoid nitroglycerine in HOCM (venodilation decreases preload and left ventricular size → increased LVOT obstruction)
32. Falling aces: avoid ACE inhibitors in HOCM (decreased preload and afterload exacerbates LVOT obstruction HOCM)
33. Wet crotch: avoid diuretics in HOCM (decreased preload and left ventricular size → increased LVOT obstruction)
34. Toppling free drinks: Friedreich's ataxia (an AR trinucleotide repeat disorder that causes ataxia and cardiomyopathy) is associated with HOCM (the most common cause of death)



3.3 – Myocarditis

1. Late night at The Flaming Heart - Myocarditis
2. The Flaming Heart: myocarditis (inflammatory dmg to myocardium caused by infection, toxin exposure, or hypersentitivity reaction)
3. Cockatoo: infection with Coxsackie B (entorovirus can cause myocarditis)
4. Scattered blue bird seed(on the bar): viral myocarditis show an inflammatory infiltrate in the myocardium on histology
5. Spilled Ab toothpicks: viral dmg to myocytes causes the release of cross-reacive Ag→ Ab target heart tissue(viral myocarditis involve direct viral injury to myocytes
6. as well as further inflammation caused by own Ab response)
7. Dilated heart sack: myocarditis can lead to dilated CMP
8. Failing heart balloon: myocarditis can lead to systolic HF
9. Blowing nose: viral myocarditis may be preceded by flu-like symptoms(~` week prior)
10. The Flaming Heart: myocarditis (inflammatory dmg to myocardium caused by infection, toxin exposure, or hypersentitivity reaction)
11. +Nonviral causes
12. Che's gAs: Chagas dis (infection with the protozaon Tryponosoma cruzi) may include myocardial involvment→ myocarditis and dilated CMP
13. Protozoal bar nuts: T.zruzi infection of myocardium shows dense collection of protozoa on histology
14. Bacterial beer tap handle: bacterial infection (e.g. Borrelia, Rickettsia, Mycoplasma) can cause myocarditis
15. „Robin of Ixodes": Lyme diseases (infection woth the bacterium Borrelia burgdorferi) can include myocarditis
16. Heart shield: myocardial involvemen in Lym disease can manifest as heart block
17. Fungus beer tap handle: fungal infection(e.g. Candidia, Mucor, Aspergillus) can cause myocarditis
18. Immunocompromised cane: fungal myocarditis is more common in immunocompromised
19. Toxin beer tap handle: toxins exposure (alcohol, carbon monoxide, cocaine, diuretics, abx) can cause myocarditis
20. Chips and dip: C.diphteria toxin can cause myocarditis
21. Box of rubies: anthracyclines (e.g. Doxo/daunorubicin) can cause free radical dmg and myocarditis
22. Autoimmunity
23. Helper with squires(bottle): certain drugs can elicit a delay type IV hypersensitivity reaction (helper T cell mediated) → hypersensitivity myocarditis



3.3 – Myocarditis

24. Mortar and pestles: drugs that cause hypersensitivity myocarditis include sufla drugs, forosemid, HCTZ, ampicllin, azithromycin and zidovudine
25. Blue and pink shot glasses: hypersentitivity myocarditis manifestes histological with lymphocytic and eosinophilic interstitial inflammatory infiltrates
26. AB darts: autoimmine disease (e.g. SLE, scleroderma, and RA) can cause myocarditis
27. Rhubarb pie: ARH is associated with myocarditis (~2-4 weeks after S.pyogene pharyngitis via molecular mimicry)
28. Clinical Signs
29. Hot dyspneic dark thrower: myocarditis often presents with constitutional symptoms such as fever, malaise, and dyspnea
30. Dark in chest: myocarditis can produce a precordial chest pain that can mimic MI
31. Bucket of Ckicken and Tbone: inflammation and myocardial dmg from myocarditis can cause release of troponins and CK MB
32. Passed out with vibritin hear: abnormal cardiac conduction from inflammation in myocarditis can lead to fatal arrythmia and suddenc ardiac death



3.4 - Pericarditis Constrictive & Pericarditis

1. Red heart case: pericarditis
2. Flaming heart bar: many of the causes of myocarditis (e.g. viral infection, bacterial infection, toxins, and autoimmune disorders) can also cause pericarditis
3. Wolf on stage: pericarditis is one of the most common clinical features of systemic lupus erythematosus
4. Broken heart string: MI causes two forms of pericarditis, an initial inflammatory form and an autoimmune form that follows 2-4 weeks later (Dressler syndrome)
5. Elevated BUN bag: uremia can cause pericarditis
6. Throwing crab picks: metastases to the pericardium can cause pericarditis
7. Guitar player leaning forward with flame bandana: fever is a common constitutional sign seen in pericarditis
8. Elevated heart watch: pericarditis can present with tachycardia
9. Leaning forward with shark tooth necklace: the pain of pericarditis is characteristically precordial and sharp; worsened with inspiration and relieved with leaning forward
10. Friction marks: movement of the inflamed visceral and parietal pericardial layers against each other creates a friction rub on auscultation
11. Bunch of elevated street signs: pericarditis causes a characteristic diffuse ST elevation on ECG
12. Wet heart case: pericarditis can cause pericardial effusion
13. Ketchup packets in puddle: conditions such as uremia or malignancy can cause hemorrhagic pericarditis
14. Guitar case filled to brim: if a pericardial effusion becomes severe enough, it can impair cardiac filling and preload
15. “Speed kills”: the rate of pericardial filling (not necessarily the volume) that determines severity of effusion (and morbidity in cardiac tamponade)
16. Fist squeezing heart: cardiac tamponade (rapidly developing pericardial effusion that limits the heart’s ability to expand and fill in diastole)
17. “Beck’s triad”: cardiac tamponade presents with muffled heart tones, hypotension, and JVD (Beck’s triad)
18. Distended blue jug: tamponade can cause jugular vein distension (JVD) (compression of the heart raises right atrial pressure, impairing filling)
19. Passed out: cardiac tamponade can present with hypotension (and in extreme cases cardiogenic shock or death)
20. Heart earmuffs: cardiac tamponade presents with muffled heart sounds



3.4 - Pericarditis Constrictive & Pericarditis

21. "Pulsus paradoxus": cardiac tamponade can present with pulsus paradoxus (>10mm drop in SBP on inspiration)
22. Equally distributed weight: pulsus paradoxus is caused by all heart chambers having equal pressure due to extrinsic compression
23. Bowing to the left with inspiration: increased venous return during inspiration with a non-distensible right ventricle causes it to bow into the left ventricle → decreased LV chamber size and stroke volume
24. BP cuff falling: in cardiac tamponade, inspiration can cause a drop in systolic blood pressure >10 mmHg (pulsus paradoxus)
25. Straw in guitar case: the only treatment for severe cardiac tamponade is drainage via pericardiocentesis
26. Lasso around heart: constrictive pericarditis (scarring and fibrosis from pericarditis can leave the pericardium stiff and non-distensible → limited expansion during diastole)
27. Distended blue jug: constrictive pericarditis cause JVD (due to impaired right atrial filling)
28. Y shaped falling glass: constrictive pericarditis causes a prominent Y descent on the jugular venous waveform (due to rapid atrial emptying)
29. Sniffing cookie smell from jug: inspiration causes an increase in JVD in constrictive pericarditis (Kussmaul's sign)
30. Failing heart balloons: constrictive pericarditis can cause diastolic heart failure and symptoms of CHF
31. Knocking on table: ventricles expanding against a thickened pericardium in constrictive pericarditis causes a characteristic "pericardial knock" on auscultation
32. White brim: in chronic constrictive pericarditis, calcification of the pericardium is seen as a white rim around the heart on CXR or CT
33. Cavitary TB cactus: constrictive pericarditis can be caused by M. tuberculosis infection (tuberculous pericarditis)
34. Knife in heart: a common cause of constrictive pericarditis is scarring following open heart surgery
35. Radiation symbol: thoracic radiation for conditions such as breast or lung cancer can lead to constrictive pericarditis



4.1 - Acute Rheumatic Fever & Mitral Stenosis (Rheumatic Heart Disease)

1. Scrumptious Stenosis - Acute Rheumatic Fever Mitral Stenosis (Rheumatic Heart Disease)
2. Valvular stenosis: cause by primary abnormality in cuspid itself making it so valve diesnt want to open. This is ussualy chronic process
3. Valvular insufficiency: problem with valve or supporting structures around it, stretching it open allowing blood to regurgitating backward
4. Bicuspid chef hat: ARF primarily affects mitral valve
5. Rhubarb pie: rheumatic fever (ARF- acute multisystem inflammatory disease that can follow a GAS infection)
6. Striped pie chef: Strep pyogenes (GAS)
7. Red neck kerchief: streptococcal pharyngitis can lead to rheumatic fever (NOT skin or other GAS infection)
8. World map: ARF is prevalent in underdeveloped countries
9. Kids: ARF most often affects children between 5-15 years old
10. Later in the month(chef marking calendar): ARF usually develop ~2-3 weeks after strep pharyngitis
11. Ab tongs: cardiac dmg in ARF is caused by a type II hypersensitivity reaction (Ab mediated)
12. Kid mimicking cheg: Ab in ARF are formed by molecular mimicry
13. JONES cupcakes: JONES criteria for dx ARF (Migratory polyarthritis, myocarditis, sub-q, erythema marginatum, sydenham chorea
14. „J” with frostin on elbows: ARF commonly presents with migratory polyarthritis (usually large joints such as the elbow, knees, and ankles
15. „O”: ARF can cause pancarditis affecting pericardium, myocardium and endocardium(valves)
16. „N” with nodular candies: ARF can present with subcutaneous nodules (form mostly on extensor surface of forearm an may show central fibrinoid necrosis)
17. „E”: AFR present with a rash that consists of hove like C-shpaed area of erythema
18. „S” fallin: ARG present with rapid involuntary movements affecting all muscle thorought the body (may show up 1-8 months after infection)
19. Lysed jelly donuts and eaten helix donut: ASO and antiDNase B titers can be used to dx previous strep infection in ARF(cultures may be negative in pts)
20. Ourpule penicil: penicillin rx ARF (sometimes given fr years depending on severity of carditis)
21. Pan of heart cookies: ARF can cause pancraditis affecting pericardium, myocardium and endocardium(valves)
22. Red heart case: ARF can cause pericarditis
23. Heart on fire: ARF can cause myocarditis (most common cause of death)
24. Failing heart balloon: ARF induced myocarditis can cause acute heart failure (pulmonary and peripheral edema in a young person)
25. Multi-cupcake cage: granulomas composed of macrophage, multinucleated giant cells, lymphocytes and plasma cells can be found in any layer of heart in ARF



4.1 - Acute Rheumatic Fever & Mitral Stenosis (Rheumatic Heart Disease)

26. (granuloma=bunch of cages)
27. „hand off" Aschoff bodies (characterisitic granulomas histological finding in ARF)
28. Caterpillar cupcakes: Anitschow („caterpillar") cells(activated macrphages with slender, ribbon like nuclei) maybe be seen in granulomas of ARF
29. Flame in heart: ARF can cause endocarditis (specifically a valvulitis)(endocarditis also form cardiac valves)
30. Frosting on bicuspid hat: ARF can casue fibrinoid necrosis and sterile verrucous vegetation on the line of valve leaflet closure (mitral most common)
31. Valvulitis lead to valve dmg
32. Regurgitation bicuspid hat chef: valve dmg in ARF can cause MR(blood regurg backward during every systolic squeeze)
33. Murmur lines from regur: ARF can present with a new-onset harsh holosystolic murmur over the apxe that radiated to left axilla (mitral regur)
34. Regurgitation aortic princess hat: valve dmg in ARF can cause aortic regir(mitral more common)(diastolic= diamon)(incompetent aortic leaflet backward blood everybeat)
35. Recurring bacterial lanters: susbequently GAS infection cause repeat episodes of ARF and worsening symtoms →chronic reumatic heart dis
36. Chronic grandfather clocl: pts may present years later with rheumatic heart dise. Due to chronic dmg and repair → chronic rheumatic heart disease
37. Chef wringing bicuspid hat: years of inflammation and scarin of the mitral leaflets in chronic RHD can lead to mitral stenosis
38. Stenotic princes(behind chef) chronic RHD may also present with aortic stenosis (mitral more common)
39. Bulging heart balloon: mitral(or aortic) stenosis can cause LA dilation (LA has to pump blood through tiny stenotic opening→pressure↑ →LA dilation)
40. Irregularly irregular signal: LA enlargement can lead to atrial fib
41. Mural cupcakes: LA enlargement and A fib can cause blood stasis and mural thrombus formation
42. Chocolate spots on head: mural thrombi in LA enlargement can embolize→ischemic stroke
43. Recurrent reigns on horse: compression of left recurrent laryngeal nerve by a dilated LA can cause chronic cough or hoarseness
44. Gulping(horse's neck) compression of esophagus by a dialted LA can lead to dysphagia and regurgitation of food
45. Sweaty shirt(stenotic chef) MS→ ↑LA pressure →symptoms of LHF (e.g pulmonary edema)
46. Diamonds and rumbling stomach: MS presents with a mid-diastolic rumbling murmur
47. „Snap!" mid-diastolic murmur of MS is preceded by an openien snap (head over apex of left sternal border)
48. 2 scared sisters: closer the opening snap is to s2 hear sound, greater severity of MS
49. (snap is heard during diastole, which means it comes right after s2, when lots of pressure ↑behind stenotic valve it opens sooner in diastole the closer snap is to s2 the more severe stenosis
50. Grany with calcifications around the mouth: MS can be also caused by annular calcifications(degenerative calcium deposition in fibrous ring of the mitral valve in older people) though uncommon



4.2 - Mitral Valve Regurgitation Mitral Valve Prolapse

1. Regurgitating bicuspid jester hat: mitral regurgitation
2. Parasailing jester with #1 finger: mitral valve prolapse is the number one cause of mitral regurgitation
3. Mixer on the parasailer: myxomatous degeneration (pathologic deterioration of connective tissue) causes mitral valve prolapse
4. Broken heart string: acute mitral regurgitation can be caused by papillary muscle rupture following MI
5. Strings broken on paraglider: myxomatous degeneration can cause chordae tendinae rupture and acute mitral regurgitation
6. Flame in heart lantern: infective endocarditis can damage the chordae tendinae → rupture and acute mitral regurgitation
7. Broken heart flashlight: acute mitral regurgitation decreases forward stroke volume → acute drop in cardiac output
8. Pulling load: acute mitral regurgitation increases left ventricular end diastolic volume and PRELOAD
9. Wet life vest: acute mitral regurgitation can cause pulmonary venous hypertension and flash pulmonary edema
10. Pushing load: acute mitral regurgitation causes a second low-resistance outlet for the ventricle → decreased afterload
11. Raised heart fraction: the decreased afterload in acute mitral regurgitation leads to an increased ejection fraction (but lower forward stroke volume)
12. Falling lightning bolt batteries: acute mitral valve regurgitation can cause severe hypotension and cardiogenic shock
13. Rhubarb pie: acute rheumatic fever causes valvulitis → mitral regurgitation
14. Flame in heart lantern: infective endocarditis can cause vegetations to form on the mitral valve → mitral regurgitation
15. Floppy heart balloon: heart failure can cause dilation of the left heart chambers and mitral annulus → functional mitral regurgitation (can be reversible)
16. Dilated heart bag: dilated cardiomyopathy can stretch the mitral annulus → mitral regurgitation
17. Chronic grandfather clock in the dilated balloon: chronic mitral regurgitation allows for the left atrium dilation and hypertrophy → less pressure transmitted to pulmonary circuit (no significant pulmonary edema)
18. Raised fraction: an increased ejection fraction maintains cardiac output in chronic compensated mitral regurgitation
19. Pulling load: chronic mitral regurgitation causes a chronically elevated preload in the left ventricle
20. Eccentric myocardial ribbon: chronically increased preload in chronic mitral regurgitation causes eccentric hypertrophy of the left ventricle
21. Failing heart balloon: chronic mitral regurgitation can progress to decompensated congestive heart failure
22. Murmur from systolic spray: mitral regurgitation presents with a blowing, holosystolic murmur
23. Jester in armpit: the systolic murmur of mitral regurgitation is heard best over the cardiac apex with radiation to the axilla
24. Hologram: the murmur of mitral regurgitation is holosystolic
25. Sloshing Slushi3: dilation of the left ventricle with chronic mitral regurgitation can cause an S3 heart sound



4.2 - Mitral Valve Regurgitation Mitral Valve Prolapse

26. Wet crotch closing bicuspid hat: functional mitral regurgitation (due to acute left ventricular volume overload) can be corrected with diuresis (decreased murmur)
27. Martian with mixer: connective tissue diseases such as Marfan syndrome, osteogenesis imperfecta, and Ehlers-Danlos can cause mitral valve prolapse (due to myxomatous degeneration)
28. Clicking carabiner between S1 and S2: mitral valve prolapse presents with a mid-systolic click (sudden tensing of the chordae as valve leaflets prolapse) between the S1 and S2 heartsounds
29. Straining next to S1: maneuvers that decrease preload (e.g. Valsalva) cause the mid-systolic click in MVP to move closer S1
30. Elevated heart watch next to S1: Tachycardia (decreases the diastolic filling time and preload) will cause the mid-systolic click in MVP to move closer to S1
31. Propping legs up next to S2: maneuvers that increase preload (e.g. straight leg raise) cause the mid-systolic click in MVP to move closer to S2
32. Squatting next to S2: maneuvers that increase preload (e.g. squatting) cause the mid-systolic click in MVP to move closer to S2
33. Sustained grip next to S2: maneuvers that increase afterload (e.g. sustained hand grip) cause the mid-systolic click in MVP to move closer to S2



4.3 - Aortic Stenosis & Aortic Regurgitation

1. A murmur is a dream the heart makes – AS, AR
2. Squeezing aortic princess hat: aortic valve stenosis
3. Milk on lips: calcific degeneration of aortic valve leaflets si mcc of AS in US
4. Black aortic hat tip: calcific degenration of aortic valve is associated with endothelial and fibroblast cell death
5. Clogged arterial candle: risk factors for calcific degeneration of aortic valve include risk factors for atherosclerosis (eg HTN, hyperlipidemia, DM, infmmation)
6. Crusty tip on candle: calcific degenration of aortic valve shows up as fine, fritty white clumps on histology
7. Bicuspid horse mouth next to milk: bicuspid aortic vavles is at risk of early dystophic calcification
8. Concentric conch: chronically increased afterload in AS leads to concentric hypertrophy of LV(when ventricle is chronically pressure overloaded, like when it has to pump against tinny stenotic valve, myocardium getc buffer by adding sarcomers in parralel, like concentric layer of spirally conch. This help heart preserve SV and maintain CO
9. Failing heart balloon: AS can cause diastolic HF
10. Dilated left wing: aortic stenosis causes chronically elevated pressure in the left ventricle and atrium →LA dilation and hypertrophy
11. Irregularly irregular signals: AS can cause aFib (due to LA dilation)
12. Clinical manifestation of AS
13. Mouse huffing and puffing: AS can present with HF symptoms (dyspnea on exertion)
14. Dim heart light: AS can cause „fixed CO" (unable to ↑ with stress)
15. Angina anvil: AS can cause angina (due to a fixed CO and ↑o2 demand form cardiac hypertrophy)
16. Sinking quicksand: AS can cause syncope (due to fixed CO thta cannot during standing or exercise → ↓brain perfusion)
17. Murmur from systolic spray: AS can present with harsh, cescendo-decrescendo holosystolic murmur
18. Pair of vibrating pipes: murmur of AS is best heard at right sternal border and radiates to carotid arteries
19. Stiff S4 chair: concetnric hypertrophy in AS lead to LV wall stiffnes→S4 sound
20. „Parvus and Tardus": sever A present with a weak slow0rising pulse („pulsus parvus et tardus") (bcz blood from heart is impedent by stenotic valve carotid pulse will be delated=tardus and weak=parvus)
21. Late bloomer: more sever AS present with a late peak in the crescendo
22. Crossed out second sister: sever AS present with diminished S2 heart sound (s1=mitral valve closure, s2=aortic closure)



4.3 - Aortic Stenosis & Aortic Regurgitation

23. Lysed tomatoesL jet stream through a AS valve can cause hemolytic anemia(schistocytes on blood smear)
24. +Maneuvers that ↑murmur AS
25. Squatting Cinderella: maneuvers that ↑ preload (stright leg raise, squatting) ↑ murmur of AS (due to ↑ SV across valve)
26. +To ↓murmur AS
27. Straining to grip tail: maneuvers that ↓preload (standingm valsalva) or ↑afterload (handgrip) reduce the murmur of AS (due to reduced SV across the valve)
28. AR
29. Regurgitating aortic princess hat: AR
30. Rhubarb pie in the center: valvulitis in ARF can casue AR(mcc in developing world) chronic rheumatic heart dis can cau se AS
31. Regurgitating milk: dystrophic calcaification can also cause AR(mcc in devel. World)
32. Bulging aortic hat base: aortic root dilation can cause AR
33. Bark on aortic tree: aortitis in tertiary syphylis („tree-barkin") can cause AR(due to aortic root dilation)
34. Inflamed tre base: large vessel vasculitides(eg Takayasu arterities, giant cell arterities(can cause AR (due to aortic root dilation)
35. Bamboo spine: Asondylitis can cause AR (due to sclerosis of aortic root)
36. Martian: collagen vascular dis (eg. Marfan, Ehlers-Danlos) can cause AR (due to aortic root dilation)
37. Flame in heart: infective endocarditis can cause AR (due to valve dmg)
38. Eccentric myocardial ribbon: AR can cause chronically ↑ EDV and pressure→ LV eccentric hypertrophy
39. Ejecting heart: eccentric hypertrophy of the LV allows for ↑ SV to maintain CO
40. Bulging up and down: ↑SV in AR causes ↑SBP and ↓DBP→ widened pulse pressure (e.g. 160/60)
41. Hammering water: AR causes rapid fillinf and collapse of blood vessles (corrigan or „water hammer" pulse)
42. Bobbing doll head: AR can cause characterisitic head bob with each pulsation (de Musset sign)
43. Jumping on nail bed: ↑ pilse pressure in AR can cause pulsation in the lips or nailbeds (quincke pulse)
44. +Murmur findings
45. Murmur and diamonds: murmur of AR is described as blowing, decrescendo diastolic murmur (best appreciated at left sternal border in 3 or 4 intercostal space) (heard right after s2) (derescendo sound lik drinkin bottle of milk, „gulk gulk gulk gulk"
46. Sloshing Slushi3: dilation of LV with AR can cause S3heart sound.

Cardiac Pathology



5.1 - Left-to-right Shunts

1. General
   a. **Dr. Eisenmenger & Alter-Ego:** Next Video: R→L shunts are cyanotic at birth ("Blue Babies"). L→R shunts are not cyanotic ("Pink Babies") but this can reverse in **Eisenmenger Syndrome** (extra R-sided blood → pHTN → Shunt Reversal → Cyanosis). Prevent this by early surgical reversal.
      i. Only occurs if shunt is large enough.
   b. **Blue and Red Comic Book Stand:** L→R shunts shunts increase the O_2 concentration on the Venous (right, blue) side, from 75% to 80%.
      i. Look for the Right-sided chamber that is extra oxygenated to determine where the septal defect is (If RA 80%, this is ASD. If RA 75% and RV 80%, this is VSD. If RA/RV 75% but PA 80%, this is PDA).
2. VSD
   a. **Victory Man opening the Superior Portion of his Shirt**: most VSD occur in membranous region (thinnest, most superior portion of septum, **Victory Man is opening the superior portion of his shirt**).
   b. **Puny Victory Man:** Small VSD leads to loud, blowing, holosystolic (**"systolic spray"** and **holographic comic book**) murmur at LLSB, first heard 4-10d post-delivery and usually asymptomatic (**baby protected from bully**).
   c. **Stroller Knocked Over:** Large VSD can lead to Failure to Thrive, HF (**Floppy Heart Balloon**), Diaphoresis with Feeding.
      i. Large VSD may not have a murmur since the large defect leads to equalization of pressures on the Right and Left.
3. ASD
   a. **"Please Use Ostium Secundum":** The ostium primum closes and the ostium secundum forms in the septum primum. The septum secundum grows in next (**glass panels covering door**) to cover up the septum secundum. Failure to form the septum secundum (**Mini-Hulk holding the panels apart**) leads to ASD.
      i. Unlike VSD, ASD does not usually close on its own (**Mini-Hulk is "always angry"**).
      ii. A patent foramen ovale (PFO) occurs when there fusion (from pressure on the left > pressure on the right) is incomplete (**incomplete fusion**).
      iii. ASD or PFO can lead to "paradoxical embolism" (Cryptogenic Stroke) since emboli can flow from RA to LA (**Firing gun through the PFO/Ostium Secundum**) when straining/valsalva/sneezing (**Mini-Hulk is Straining**)
   b. ASD leads to:
      i. Systolic murmur (**Systolic Spray on Astro-Girl's Arm Cannon**),
      ii. Wide, Fixed Splitting of S2 (**Mom keeping Children Apart**; lub-dub-dub during both inhalation and exhalation)
      iii. Diastolic Rumble **(Rumbling in "Diastolic Diamond Cave" Comic)**, a low-pitched rumble heard after S_1 and S_2 because of a higher-than-normal flow over the Tricuspid Valve **(Right side of Mom is Soaked)**
      iv. Positive Bubble Study on Echocardiogram, UNLIKE PFO (**Bubbles flowing from Astro-Girl's Arm Cannon**).



5.1 - Left-to-right Shunts

4. PDA
    a. Ductus Arteriosus (**Air Ductus**) may stay patent in Congenital Rubella (**Robot with Ruby**) or in preterm infants. PGE_2 keeps the DA open (**Pro-Slugger Bat**), which drops after birth. Indomethacin (**NSAID Fire-Extinguisher**) can reduce PGE_2 to close the DA.
    b. PDA leads to a continuous machine-like murmur with increased pulse pressure (**Ductus Prime Flexing and Raising up the Ground**).
    c. If PDA leads to Eisenmenger's Syndrome, this will be present in the lower extremities only (**Blue Legs, Red Arms**) since deoxygenated blood is delivered distal to the L Subclavian A.
5. Coarctation of the Aorta (**Colorful Arc Rainbow**)
    a. Congenital vascular defect that can present similarly to PDA, from narrowing of the descending aorta near the insertion of the DA (**Girl sitting on Aortic Pipe leading to Constriction near Air Ductus**). Common in Turner Syndrome (**Turning Windmill**), a condition with X0 (**X-shaped Windmill**) that also can involve Bicuspid Aortic Valve that calcifies (**Horse Puppet's Mouth with White Stripes**).
    b. Can lead to differential cyanosis between upper and lower extremities (**Blue Legs, Red Arms**), and PDA is needed to carry oxygenated blood past the coarctation. When PDA closes, neonates can get heart failure/shock (**floppy heart balloon**). Can also lead to HTN (**Painter with High-Pressure Steam**), Aortic Dilation/Dissection, Intracranial Hemorrhage (from ↑ cerebral blood flow; **Red Streak of Paint on Hat**), BP discrepancy b/t upper and lower extremities (**Steam Above where Painter is Holding, No Steam Below**), Delayed/Diminished lower extremity pulses (**Delayed Schedule**), and lower extremity claudication (**Black Spots on Pants**).
        i. Anastomoses can bypass the coarctation, leading to inferior rib notching (**Notched Ladder**)
6. Infective Endocarditis (**Flame from Within**)
    a. ¾ with Infective Endocarditis have a preexisting structural abnormality, including many of the things in this sketch (except for ASD; **Astro-girl is beating the Endocarditis Monster**).
7. **SUMMARY**: ASD, VSD, and PDA are L→R shunts ("pink babies") and cyanosis can develop later (Eisenmenger's) when the shunt reverses. PDA gives continuous machine-like murmur, PDA is systolic murmur with fixed split S_2 and possibly diastolic rumble, VSD has holosystolic murmur when small and no murmur when large. Large VSD can manifest as FTT/HF in newborn. PFO/ASD can lead to cryptogenic stroke. Both PDA and Coarctation can lead to differential cyanosis of the LE, but Coarctation has more pressure symptoms (high pressure above, delayed lower pulses). If vignette has cyanosis in 7yo think of a R→L shunt, but if cyanosis in a neonate think of a L→R shunt.



5.2 - Right-to-left Shunts

1. Read manga right to left: right-to-left shunts (e.g. truncus arteriosus, TGV, tricuspid atresia, TOF, TAPVR)
2. Blue baby: right-to-left shunts cause early onset cyanosis
3. Large purple trunk: truncus arteriosus (right-to-left shunt)
4. Large V shirt: truncus arteriosus often occurs with VSD
5. Neural crest shield: failure of neural crest cell migration causes truncus arteriosus
6. “22” and “11” helmet: failure of neural crest cell migration (e.g. truncus arteriosus) is associated with 22q11 deletion syndromes (e.g. DiGeorge)
7. Monster trainer station: transposition of the great vessels (TGV - a right-to-left shunt)
8. Independent right and left circuits: TGV results in an independent deoxygenated systemic circuit and oxygenated pulmonary circuit (aorta and pulmonary artery are transposed)
9. “PDA VS ASD”: TGV is incompatible with life without a VSD, ASD, or PDA (left-to-right shunts)
10. Murmur between the circuits: TGV can present with a murmur form an associated left-to-right shunt
11. Red ponytail in front of blue: with TGV, the aorta is anterior to the pulmonary artery (on cardiac echo)
12. Monster ball on a string: with TGV, the cardiac silhouette looks like an “egg on a string” on CXR
13. Throwing up candy: diabetes in the mother is a risk factor for TGV
14. Defeated spiral monster: failure of the aorticopulmonary septum to spiral results in TGV
15. Tricuspid “Z” warrior: tricuspid atresia (right-to-left shunt)
16. Hole in septal window: tricuspid atresia is often associated with an ASD
17. “Tetra Sailors”: tetralogy of Fallot (Right-t-left shunt)
18. Earth sailor with constricted pulmonary trees: pulmonary valve stenosis (feature of TOF)
19. Earth sailor’s blue face: pulmonary valve stenosis causes cyanosis (the degree of stenosis dictates the severity of disease)
20. Water sailor’s conch shell: TOF is associated with right ventricular hypertrophy (concentric) due to pressure overload
21. Water sailor’s large boots: right ventricular hypertrophy (feature of TOF) seen on CXR as a “boot-shaped heart”
22. Fire sailor’s big V neck: ventricular septal defect (feature of TOF)
23. Air sailor’s red ponytail flying overhead: overriding aorta (feature of TOF)
24. Neural crest shield: failure of neural crest cell migration causes TOF
25. “22” and “11” jewelry: failure of neural crest cell migration (e.g. TOF) is associated with 22q11 deletion syndromes (e.g. DiGeorge)
26. Systolic spray: TOF can present with a harsh systolic crescendo/decrescendo murmur (due to pulmonary valve stenosis)



5.2 - Right-to-left Shunts

27. Evil choking spell: TOF can present with hypercapnic spells (“tet spells”)
28. Squatting to dodge spell: squatting relieves symptoms during a hypercapnic spell
29. Geyser shooting upward: squatting increases SVR forcing more blood upward into the pulmonary circulation
30. “Tap VR”: total anomalous pulmonary venous return (TAPVR - right-to-left shunt)
31. Right, down, right, down...: in TAPVR, the pulmonary veins drain back into the right heart (with the systemic circulation)
32. Dilated right tap dancer: TAPVR causes a dilated right atrium and ventricle
33. Hole in septal window: in TAPVR, an ASD allows some oxygenated to enter the systemic circulation
34. “Upstairs”: Ebstein’s anomaly can present in infancy with cyanosis
35. Large atrium map: Ebstein’s anomaly is associated with dilation of the right atrium
36. “Event in atrium”: the abnormal dilation of the right atrium and inferior displacement of the tricuspid valve into the ventricle is termed “atrialization” of the right ventricle
37. Regurgitation on tricuspid wig: Ebstein’s anomaly is associated with a malformed tricuspid valve and tricuspid regurg
38. Failing heart balloon: Ebstein’s anomaly is associated with right sided heart failure (due to severe tricuspid regurg)
39. Pregnant mother on “lift-ium”: Ebstein’s anomaly is caused by lithium exposure in utero

Lung Pathology



1.1 - COPD & Emphysema

1. **Obstructive Lung Disease**
2. In COPD, obstruction prevents air from leaving the lungs (trapped in distal airways) (OBSTRUCTING STREET)
3. COPD causes irreversible obstruction (NO U TURN)

a. In comparison to asthma is a transient **reversible process,** caused by hyperactive airways

4. Cigarette smoking is the most important risk factor for COPD (SMOKER)
5. Emphysema occurs distally, while chronic bronchitis involves the airways the more proximal airways

a. Respiratory bronchiole (PROXIMAL STREET)
b. Alveolar duct: (DISTAL CUL-DE-SAC PATH)
c. Alveolar sac: (END OF CUL-DE-SAC PATH)

6. **Emphysema: Pink Puffer**

a. Affects the distal airways in the alveolar walls
b. **Definition**: Permeant Enlargement of the distal airspaces of the corresponding lung hyperinflation and chronic air trapping

i. **Centriacinar:** affects **respiratory bronchioles** and spares the alveolar ducts and sacs (YELLOW GRASS)
   1. Affects the upper 2 lungs of the lung preferentially (SWEATY UPPER HALF OF JERSEY)
   2. Toxins collect in the respiratory bronchioles and activate an inflammatory response (TOXIC HOCKEY PUCK)
   3. **Neutrophils** recruited to distal airways
   4. Produce **elastase** (FIRST RESPONDER CUTTING THE ELASTASE)
   5. This leads to **raised COMPLIANCE** in the distal airway (Raised compliance book) = floppy
   6. Collapse at the distal terminal bronchioles causes air trapping (Collapsed At The Terminal Street)

ii. **Panacinar:** Associated with alpha-1 antitrypsin deficiency but can be seen in sever emphysema (N
   1. AAT is the **major serum inhibitor** of neutrophil elastase (AA trimming)
   2. AAT deficiency à uninhibited neutrophil elastase à destruction of distal airways
   3. Occurs throughout the lung (leaves all over the cul-de-sac)
   4. Effects the lower lobes (Bottom of the shirt is torn)
   5. AAT is produced in the liver so this accumulates in the hepatocytes à leads to liver damage and cirrhosis
   6. Non-secreted AAT stains PAS positive (PASS FRISBEE)
   7. Young patients (young trimmer): **Inherited**
   8. Smoking increases emphysema risk in patients with AAT deficiency (Directly inhibits AAT)
      a. Increases neutrophils to the area because of inflammation
      b. Directly oxidizes and activates AAT
   9. Smoking with Early AAT will develop symptoms way earlier

c. **Signs and Symptoms:**

i. Emphysema presents with **gradually progressive dyspnea** (Huffing and Puffing)
ii. Bilateral Wheezing (Party Blower)
iii. Tripod position: armed is propped up (KID SITTING DOWN)
iv. **Purse lips**: helps maintain pressure to inflate distal airways (purse lips)
v. May cause weight loss (hockey man lost weight)
   1. Muscles are used for breathing
vi. Emphysema can cause **pulses paradoxes** (causes a >10mmHg decrease in systolic pressure during inspiration)
vii. Distant lung and heart sounds (heart and sailboats fall away)

Lung Pathology



1.1 - COPD & Emphysema

d. **X-ray:**
   i. **Hyper inflated:** Lungs expand and push the chest out
   ii. Chest X-ray: flat diaphragm, **10+ posterior rib shadows**, increased parenchymal radiolucency, lengthened cardiac silhouette (vertical heart)

b. **Pulmonary Function Test:**
   i. COPD causes increased total lung capacity (Full "Total Load"
   ii. COPD causes increased functional residual capacity "Full Residual bin" (left over after a normal expiration)
   iii. **FEV1:** 1 second is not enough time for them to breath otherwise the lungs will collapse
      1. (ForeEVer #1" sign)
   iv. **FVC: Forced Vital Capacity:** Exhale all of the air after a full breath: Also decreased because of air trapping just not as much
      1. FEV1/ FVC (FEV1 is really low and FVC is low)
      2. Low ratio (Both signs are dropping)
      3. Less than .7 (The hockey stick)
   v. Emphysema causes a low DLCO (Diffusion capacity of the lung for carbon monoxide (Trash on the street and on the groud)
      1. How well oxygen can go from the alveoli into the lung
      2. Decreased because of damage into the alveoli
      3. Hyperventilation EARLY in the course maintains normal arterial oxygen levels (Normal PaO2) (Pink face)
         a. Hyperventilation early in the course causes **respiratory alkalosis** (Blowing OH bubbles)
      4. In LATE emphysema there is severe air trapping (CO2 retention an **respiratory Acidosis**)
         a. Can't blow off the CO2 anymore so the bubbles start to pop
         b. Severe decrease in DLCO à decreased PaO2 à cyanosis

e. **Bronchitis: (Blue Bloater)**
   c. Occurs in the terminal bronchioles (ROAD TERIMNATES)
   d. Chronic Bronchitis: Defined as a productive cough (hacking up sports drink)
   e. Lasts for at least 3 months (NUMBER 32)
   f. Chronic Bronchitis involves mucus gland hypertrophy and hypersecretion in larger airways (trachea bronchi and bronchioles) (MUCUS ON TRACHEAL STICK)
   g. Mucus hypersecretion **causes mucus plugs** in the bronchioles à distal airway obstruction à distal airway obstruction (In chronic bronchitis)
   h. Chronic bronchiolitis (as part of chronic bronchitis) causes **goblet cell metaplasia and proliferation** (Goblet bottles in terminal street)
   i. **Early in course:** mucus plugs trap air in distal airways à increased PaCO2 and **respiratory ACIDOSIS** (in chronic bronchitis) (CO2 FUMES)

f. **Cyanosis of the skin**
   j. O2 supplementation can decrease RR causing respiratory failure in COPD patients and inhibits the firing of peripheral chemoreceptors (aortic arch and carotid bodies sense decrease in PaO2) (O2 knocking over arch)
   k. **Heart:**
   l. Hypoxic goalie stretching net: Chronic hypoxemia in COPD à hypoxic vasoconstriction à pulmonary arterial hypertension
   m. Corked hear bottle: Pulmonary hypertension due to hypoxic vasoconstriction in COPD can lead to right heart failure (COR PULMMONAE)

Lung Pathology



1.2 - Asthma & Bronchiectasis

1. **Asthma**
2. **General:**
   a. In asthma, obstruction prevents air from leaving the lungs (trapped in distal airways): (Kid obstructing exit)
   b. Asthma is characterized by a hyperactive airway (HYPERACTIVE TO BEE)
   c. Asthma In comparison to COPD is a transient **reversible process,** caused by hyperactive airways that leads to intermittent airway inflammation and obstructive symptoms (BACKWARDS CAP)
   d. ASHTMA is characterized by **chronic bronchial Inflammation** with **eosinophils** (Flame with a slingshot)
   e. Asthma is characterized by **smooth muscle hypertrophy** and hyperactivity and increase mucus section (MUCUS DRIPPING and GRIP ON LIMB)
   f. Atopic asthma involves a **type I hypersensitive reaction,** with common triggers being animal dander, pollen, dust and other environmental antigens (ANTIGENIC SQUIRREL)
3. **Mechanism of Action:**
   a. The antigen is picked up by an antigen presenting cell and then presented to a TH2 helper T cell where it gets too activated
      i. Interleukins 4, 5, 13 are activated
      ii. Interleukins 4, 13 will activate B cells that **will make a lot of IgE**
      iii. This signals to the B cells to produce IgE (IL4 and IL13) (IgE archer aiming at beehive)
   b. The inflammatory reaction in asthma is a type 1 hypersensitivity reaction (IgE production and mast cell degranulation) (1 finger in the air)
      i. BEE HIVE = Mast cell
   c. When antigen is reintroduced it binds to the IgE on mast cells and crosslinks the IgE which leads to degranulation (SQUIREEL CROSS LINKING BEEHIVE)
      i. This degranulation release leads to release of histamine, acetylcholine, leukotrienes and other pro-inflammatory cells (BEE RELEASE)
4. **Phases of Asthma:**
   a. Early Phase:
      i. Pro-inflammatory molecules released by mast cells induce **bronchoconstriction,** mucus production and vasodilation in large airways (GRIPPING DROOLING, DILATED SLEEVES)
   b. Late Phase:
      i. Inflammation consisting of eosinophils, neutrophils and T-cells occurs 4-8 hours after the early phase (LATE FLAME CAP)
      ii. **Eosinophils** are a characteristic finding of Asthma
      iii. This is causing damage to the airways (EOSINOPHILS EVERYWHERE)
      iv. A major source of damage form eosinophilic inflammation is release of major basic protein, an anthelmintic toxin that causes epithelial damage, histamine release and further eosinophil chemotaxis (DAMAGED MAJOR BASE SIGN)
      v. Chronic inflammation form repeated attacks causes permeant structural changes to bronchial wall (CHRONIC FLAME CAPE)
   1. This includes thickened basement membrane and smooth muscle hypertrophy and hypertrophy of submucosal mucosal glands (THICK CONCRETE BASE AND A BUFF KID AND MUCOUSY EATER BOTTLE)
   c. Histology:
      i. **Mucus plugs** in bronchi and bronchioles (Can plugged with mucus)
      ii. **Eosinophilic infiltration of the airways** is one of the hallmarks of atoptic asthma (eosinophils in sputum and eosinophilia)
      iii. Slothing of epithelium can lead to the formation of **Kurshmann spirals,** which are whorled deposits of epithelial cells (Curly string from plugged can)
      iv. **Charco-Layden crystals** are thin, needle like concretions of eosinophilic proteins seen in the sputum of asthmatics (PINK JACKS)



1.2 - Asthma & Bronchiectasis

5. Clinical Presentation:

a. **Expiratory wheezing** from bronchoconstriction is common in asthma exacerbation (KID WITH PARY BLOWER)
b. **Acute dyspnea** is a common symptom of asthma exacerbation (KID PUFFING OUT AIR)
c. **Chronic cough** especial nocturnal cough, in children it may be the only symptom (kid waking up form cough)
d. Asthma is highly associated with atopy, so a family history of allergies is common (FAMILY PHOTO)
e. Severe asthma attacks can lead to pulsus paradoxus, a drop in systolic BP> 10mmHg on inspiration (PULSUS PARADOXUS)

6. Imaging:

a. Air trapping in acute exacerbations can be seen on chest x-ray as a hyper inflated lung (flattened diaphragm, and lengthening of the cardiac silhouette) (KITE with XRAY)

7. Pulmonary Function Tests:

a. Classic spirometry findings in asthma are a FEV1/FVC <.7 and an FEV1 <80% expected (FALLING FEV1/FVC)
b. In between attacks these attacks are probably normal

8. Laboratory Tests:

a. Patients with acute asthma exacerbations will have an initial respiratory alkalosis form hyperventilation (can progress to acidosis as severity increases) (BLOWING OH bubbles that end up popping)

9. Non-atopic Asthma:

a. **Viral infections** are a common inciting cause of non-atopic asthma exacerbations (VIRAL Lantern)
b. **Second hand smoke** are another common inciting cause of non-atopic asthma exacerbations (ASHTRAY)
c. **Aspirin** is a the most common drug induced cause of non-atopic asthma exacerbations (UMPIRE HOLDING LACROSS STICK)
    i. Inhibiting COX-1 shifts AA metabolism to LOX pathway à Leukotrienes à bronchoconstriction

1. LTC4, LTD4, LTE4

10. Bronchiectasis

11. Bronchiectasis is characterized by permanent dilation of the bronchi and bronchioles (due to infections and inflammation that destroys the muscle and elastic tissue supporting the airway) (DILATED POMEGRANATES)

a. Same area of the lung each time
b. Recurring bacteria lanterns: bronchiectasis is caused by **chronic recurrent bacterial infections**
c. **Tumors** causing obstruction can lead to distal infection, thus initiating the cycle of infection/ inflammation à bronchiectasis
d. **Chronic Fibrosis** is the most common cause of bronchiectasis in the US (thick secretions cause obstruction leading to infection/inflammation) (tree sap)
e. **Primary cilia dyskinesia** is another possible cause of bronchiectasis (secretions are not cleared due to dysfunctional cilia)
f. Tuberculosis is the most common cause of bronchiectasis worldwide

12. Bronchiectasis primarily affects the lower lobes (Seen on CXR and CT as CROWDED bronchial markings extending to the edge of the lung periphery (CROWDED LOWER POMEGRANATES)
13. Bronchiectasis is characterized by copius sputum production, often described as "cup fulls"

a. Can have hemoptysis

Lung Pathology



2.1 - Restrictive Lung Disease (Overview)

1. Torn compliance contract: lung compliance decreased in restrictive lung disease
2. Total “Load” Capacity overturned: total lung capacity (TLC) decreased in restrictive lung disease. Therefore unable to take a very large breath
3. 5 second rule!
4. Elevated FEV1/FVC signs: Forced Expiratory Volume in 1sec / Forced Expiratory Volume (FEV1/FVC) is elevated (>80%) in restrictive lung disease
5. Falling FVC sign: FVC decreases in restrictive lung disease (FEV1/FVC increases)
6. FEV1 banner pulled tight: increased elasticity of pulmonary interstitium (interstitial restrictive lung disease) → airway widening and decreased resistance to expiratory flow → maintains FEV1 (though still decreased)
7. Overturned residual capacity: Functional Residual Capacity (FRC) is decreased in restrictive lung disease.
8. Restrictive corset cough: non-productive cough in interstitial lung disease (INTRINSIC restrictive lung disease)
9. Over-exerted breath: restrictive lung disease starts with dyspnea on exertion and can progress to dyspnea at rest
10. Ripping corset velcro straps: interstitial lung disease (INTRINSIC restrictive lung disease) can cause dry crackles (“velcro rales”) usually heard best at the lung bases.
11. X jolly roger: interstitial lung disease (INTRINSIC restrictive lung disease) can be seen on x-ray (diffuse reticulo-nodular opacities)
12. Reticular knotted pattern: interstitial lung disease (INTRINSIC restrictive lung disease) commonly presents with reticulo-nodular, diffuse, and bilateral opacities on x-ray
13. Tight red corset ribbons: chronic interstitial lung disease can cause pulmonary hypertension (destruction of lung parenchyma and reduction in alveolar capillaries → increased pulmonary arterial resistance)
14. Corked bottle with heart ship: Pulmonary hypertension can cause right heart failure (COR PULMONALE)
15. Pleural shirt: Pleural diseases (e.g. mesothelioma) and pleural effusions can cause EXTRINSIC restrictive lung disease
16. Muscles and cut communication wire: neuromuscular diseases (e.g. polio or myasthenia gravis) can cause EXTRINSIC restrictive lung disease when diaphragmatic and intercostal muscles affected
17. Locked chest of drawers: Spine malpositioning (e.g. kyphoscoliosis, ankylosing spondylitis) can restrict chest wall expansion and cause EXTRINSIC restrictive lung disease
18. Obese Governor Pickwick: Obesity can limit chest wall expansion and cause EXTRINSIC restrictive lung disease
19. Shallow breathing into bag: obese patients may take faster smaller breaths due to extrathoracic restriction (retention of carbon dioxide)
20. Low extra reserves: the most common indicator of obesity-related restrictive lung disease is a reduction in Expiratory Reserve Volume (ERV)
21. Hypoxic blue face: obese patients may develop chronic restrictive lung disease → retention of carbon dioxide (Obesity Hypoventilation Syndrome) with high PaCO2 and low PaO2

Lung Pathology



22. 2.1 - Restrictive Lung Disease (Overview)
23. Tight vascular vest chains: obesity can cause chronic hypoxia → chronic pulmonary vascular constriction → pulmonary hypertension
24. Corked bottle with heart ship: pulmonary hypertension caused by obesity-related restrictive lung disease can lead to right heart failure (COR PULMONALE)
25. fibrotic pulmonary trees: idiopathic pulmonary fibrosis (INTRINSIC restrictive lung disease)
26. Dusty factory: pneumoconioses (INTRINSIC restrictive lung disease)
27. Soccer player: sarcoidosis (INTRINSIC restrictive lung disease)
28. Odorless colorless plastic trash littered on ground: DLCO is LOW in INTRINSIC restrictive lung disease only (e.g. pulmonary fibrosis, pneumoconiosis) because diffusion surface is destroyed
29. Ground glass mirror: reticulo-nodular opacities may be described as “ground glass”



2.2 - Idiopathic Pulmonary Fibrosis (IPF)

1. Restrictive corset: interstitial lung diseases (e.g. idiopathic pulmonary fibrosis (IPF) produce restrictive lung disease
2. Fibrotic pulmonary tree: pulmonary fibrosis (a component of many of the interstitial lung diseases)
3. "Idiot": Idiopathic pulmonary fibrosis (IPF) is the prototypical fibrosing disorder
4. Repeating red grapes: IPF is associated with repeated cycles of alveolitis (of unknown origin)
5. Cracks in epithelial stones: recurring inflammation damages type 1 and type 2 alveolar cells in the alveolar epithelium
6. Dumping coins: damaged type-1 pneumocytes release cytokines → TGF-beta-1 activates fibroblasts → pulmonary fibrosis
7. Patchy distribution of grapevines: IPF is associated with a patchy fibrosis (due multiple fibroblastic foci) on histology
8. "jUIcy graPe": usual Interstitial pneumonia (UIP) is the patchy fibrotic histology seen in IPF
9. Cobblestone patio: IPF is associated with a cobblestone appearance of the pleural surface (retraction scars along the interlobular septa)
10. Bare lower branches: fibrotic changes in IPF appear as bilateral or diffuse reticular opacities, most prominent in LOWER LOBES (on X-ray or CT)
11. Branches under shirt: the opacities of IPF distribute along SUB-PLURAL regions and interlobular septa
12. Honeycomb treat: alveoli collapse and dilated proximal airways in IPF appear as "honeycombing" on CT and gross pathology
13. CAP gun going "BOOP": cryptogenic organizing pneumonia (COP) also known as bronchiolitis obliterans organizing pneumonia (BOOP) is another cause of pulmonary fibrosis
14. Plug in gun: COP is associated with intraluminal plugs of granulation tissue leading to alveolar collapse and consolidation → alveolar collapse and consolidation
15. Sudden gunfire: COP causes acute onset of cough and dyspnea
16. Fire bandana: COP presents with fever and weight loss
17. Moon face: COP can be treated with oral corticosteroids
18. Mortar and pestle: many drugs (e.g. amiodarone, bleomycin, methotrexate) can cause pulmonary fibrosis
19. Fibrous radiation shield: patients with history of thoracic radiation can develop radiation pneumonitis and pulmonary fibrosis
20. Wet pleural shirt: radiation pneumonitis can present with pleural effusion
21. Moon face: radiation pneumonitis can be treated with oral corticosteroids
22. Lupus wolf: collagen vascular diseases (e.g. lupus) can cause pulmonary fibrosis
23. Scaly dragon: systemic sclerosis can cause pulmonary fibrosis
24. Inflamed joint lanterns: rheumatoid arthritis can cause pulmonary fibrosis

Lung Pathology



2.3 - Pneumoconioses

1. Particulates in air: pneumoconioses are interstitial lung diseases caused by the inhalation of organic and inorganic particulates
2. Restrictive corset: pneumoconioses can present with a restrictive lung disease picture (reduced lung compliance, FEV1, FVC, and TLC)
3. Screw with nuts: in the macrophages, asbestos fibers are coated with an iron containing proteinaceous material → ferruginous bodies (brown "beaded appearance" on H&E)
4. Larger particles on belt: larger particles (10-15 microns) will get trapped in upper airway
5. Sweeping medium particles: particles 5-10 microns in diameter are cleared by mucociliary transport in the trachea and bronchi
6. Small particles trapped at bifurcations: particles 1-5 microns in diameter lodge at the bifurcation of respiratory bronchioles → phagocytosed by macrophages
7. Small particles in cages: particles 1-5 microns in diameter are engulfed by alveolar macrophages → cytokine release
8. Dropping coins: cytokines (PDGF, IGF) released from macrophages are the cause of inflammation and fibrosis in pneumoconioses
9. Shark tattoo: collagen production from the release of growth factors leads to pulmonary fibrosis and restrictive lung disease
10. Cigar: tobacco smoke worsens symptoms and clinical course of all the pneumoconioses
11. Black panther coal: pulmonary anthracosis consists of asymptomatic pigment deposition in interstitial tissue and hilar nodes (contained in macrophage "dust-cells")
12. Streaked black sails: streaks of anthracotic pigment are seen throughout the lungs (lymphatic spread of "dust cells")
13. Hilar coal cages: anthracotic pigment is deposited in the hilar lymph nodes (lymphatic spread of "dust cells")
14. Coal on lung coral: simple CWP is characterized by "coal macules" and focal fibrotic "coal nodules" (predominantly in the upper lobes)
15. X-ray flag: simple CWP shows small, rounded, opacities, in the upper lobes
16. Puffer fish in center: simple CWP produces centriacinar emphysema (mostly in the upper lobes)
17. Bigger chunks on lung coral: Complicated CWP is characterized by massive blackened opacities and fibrosis (predominantly in the upper lobes)
18. Sandblaster: exposure to silica occurs in foundries, mines, sandblasting (quartz is particularly fibrogenic)
19. Sand crystals on lung coral: silicotic nodules are found mostly in the upper lung fields
20. Whorled shell: silicotic nodules contain concentrically arranged collagen
21. Fragrance from whorled shell: silicotic nodule will appear as weakly birefringent particles under polarized light
22. Honeycomb pattern: nodules coalesce to form large scars with areas of honeycombing in between (cystically dilated)
23. Hilar shells: silicosis causes "egg-shell" calcification of the hilar lymph nodes (fibrosed lymph nodes
24. Cowboy breaking cage: silicosis increases risk of TB infection (disrupt phagolysosome and promote apoptosis)
25. Big rust holes: In the setting of a pulmonary TB infection, nodules of silicotuberculosis can form, containing a central zone of cassation
26. Pink insulation: asbestos exposure can cause asbestosis: a pneumoconiosis characterized by slow progressive and diffuse pulmonary fibrosis)
27. Ship builder: asbestos can be found on ship plumbing insulation, ceiling tiles and floor tiles
28. Nails and screws: asbestos fibers may be straight, stiff, and brittle (amphibole) or curly and flexible (serpentine)
29. Straight nail in shirt: amphibole fibers can penetrate the epithelium and enter the interstitium (more pathogenic than "serpentine")
30. Lower barnacles: the fibrosis of asbestosis predominantly affects the subpleural lower lung fields
31. Large buttons: pleural plaque formation is the most common manifestation of asbestos exposure (benign, no asbestos bodies)
32. Honeycomb shape: in asbestosis, fibrosis progresses to Large inelastic fibrous tissue segments with intervening areas of "honeycombing

Lung Pathology



2.4 - Sarcoidosis & Berylliosis

1. Soccer ball: sarcoidosis (a multisystem granulomatous disease with major pulmonary findings)
2. Intact macro-CAGES: sarcoidosis is associated with non-caseating granulomas (a collection of macrophages without an area of central necrosis)
3. Black female soccer captain: sarcoidosis is most common in African Americans (particularly young females between 20-39)
4. No smoking sign: sarcoidosis is more common in non-smokers
5. Helper T squires: CD4+ helper T-cells are activated in Sarcoidosis
6. “BAL” bottle: bronchoalveolar lavage shows an elevated CD4+ to CD8+ ratio (> 2:1) in sarcoidosis
7. No reaction to feather: sarcoidosis can cause anergy to common skin antigens that usually elicit type-IV (delayed) immune reactions (e.g. Candida, PPD test)
8. Antibody keys: sarcoidosis can cause polyclonal hypergammaglobulinemia (due to Helper T cell dysregulation)
9. Multiple purple panels: granulomas may contain multinucleated giant cells (formed by the fusion of activated macrophages)
10. Ball with star panels: giant cells may contain asteroid bodies (stellate inclusions)
11. Show-man with purple cleat: granulomas may contain Schaumann bodies that show up as a purple spot on histology
12. Calcified leather cleat: Schaumann bodies contain laminated calcium and protein
13. Balls in the field: non-caseating granulomas can be found throughout the lung interstitium in sarcoidosis
14. Soccer balls at the midline: non-caseating granulomas can occur in hilar and paratracheal lymph nodes → hilar lymphadenopahty
15. Hilar soccer balls in lung tree: in sarcoidosis, enlarged bilateral hilar and mediastinal lymph nodes can be seen on chest x-ray
16. Fibrotic lung tree: in sarcoidosis, pulmonary granulomas can be replaced by diffuse interstitial fibrosisv
17. Dyspneic player: pulmonary sarcoidosis presents with a gradual onset of dyspnea (on exertion)
18. Coughing player: pulmonary sarcoidosis can present with a dry cough
19. Skinny goalie with flame bandana: sarcoidosis presents with other constitutional symptoms (malaise, fever, anorexia, weight loss)
20. Painful spotted shin guards: sarcoidosis can present with erythema nodosum (raised red painful nodules on anterior legs; no granulomas)
21. Gravel nodules: sarcoidosis can present with subcutaneous nodules (non-painful; contain abundant granulomas)
22. Purple face paint: sarcoidosis can cause lupus pernio (violaceous rash on nose and cheeks)
23. Blurry red rimmed goggles: sarcoidosis can cause anterior uveitis → redness, blurry vision, glaucoma
24. Retina street lights with broken wires: sarcoidosis can present with retinal and optic nerve involvement → vision loss
25. Dry water bottle: sarcoidosis can present with lacrimal and salivary gland involvement → dry eye and dry mouth
26. Liver spot cow: sarcoidosis can involve the liver → granulomatous hepatitis
27. Restrictive net: cardiac sarcoidosis may cause restrictive cardiomyopathy
28. Raised milk glass: Sarcoidosis can cause hypercalcemia (due to hypervitaminosis D)



2.4 - Sarcoidosis & Berylliosis

29. 1-α Box: activated macrophages in granulomas produce 1-α-hydroxylase (converts Vitamin D into its active form, 1-25-dihydroxyvitamin D)
30. Sunny street lights: extra 1-α-hydroxylase produced in the granulomas may lead to hypervitaminosis D → hypercalcemia
31. Stones in leaked milk: sarcoidosis can present with hypercalciuria → calcium kidney stones
32. Raised ACE card: sarcoidosis can present with increased levels of angiotensin converting enzyme (ACE) (produced in the granulomas)
33. Moon face balls: progressive sarcoidosis can be treated with glucocorticoids
34. Building aircraft: beryllium dust is found in nuclear and aerospace industries (exposure can lead to berylliosis)
35. Macro-CAGES with soccer ball: berylliosis presents with non-caseating granulomas (similar to sarcoidosis)
36. Particles falling on top of fibrotic lung tree: interstitial fibrosis in berylliosis may be more prominent in upper lobes



3.1 - Lung Carcinoma

1. METropolitan bus:: metastases are the MC cancers in the lung
2. Crab bra, kidney purse & colon belt: breast, renal and colon CAs commonly metastasize

Risk Factors

3. Risky red dice: risk factors for developing lung CA (e.g. smoking, radiation, pulmonary fibrosis, toxins (, i.e. asbestos, radon, metals, and aromatic hydrocarbons)
4. Smoking: **most important** risk factor (20x increased risk)

Presentation

5. Clutching chest: **chest pain** (esp in younger patients); Thin arm: **weight loss**; Falling food: ¯ **appetite**; Gasping: **dyspnea**
6. Coughing warden & wheezy party blower: **coughing & wheezing** (especially central tumors)
7. Recurrent bacterial lanterns & bloody air duct: **recurrent pneumonia & hemoptysis** (especially central tumors)

Small cell lung carcinoma – Small prison cell

8. "Sentral Cell Block": centrally located tumors include Small cell and Squamous cell carcinoma
9. Sheets of bubble wrap: contains sheets of round blue (basophilic) cells with scant cytoplasm
10. Granite cell: granular chromatin ("salt & pepper") and stains **chromogranin +** (neuroendocrine marker)
11. Neuroendocrine wiring: neuroendocrine tumor
12. Escaping prisoner: metastasizes early (discovered diffusely in both lungs)
13. Radiation window & chemistry set: sensitive to radiation & **chemotherapy**

Paraneoplastic syndromes

14. Inappropriately wet head: **SIADH** (ADH release from tumor)
15. Antibody keys & empty calci-yum cups**: Lambert Eaton Myasthenic Syndrome (LEMS)** (Ab against voltage-gates Ca+ channels)
16. Acetyl-cola trash bin & struggling to get up: LEMS causes decreased ACh release due to blocked presynaptic Ca+ channels → proximal muscle weakness
17. Antibody keys under cerebral turban: **neurological syndromes** (e.g. cerebellar degeneration, encephalomyelitis) which are due to autoimmune responses against antigens in neural tissue
18. Cushion: **Cushing's syndrome** (ACTH-like substance release from tumor)

Squamous cell carcinoma (non-small cell) – Squamous epithelial tile

19. Columnar cells: normal respiratory epithelium is pseudostratified columnar
20. Temporary metal plates: replaced with resistant stratified squamous (reversible squamous metaplasia)
21. Disgusting squamous tiles: squamous metaplasia can progress to dysplasia (disordered squamous cells with hyperchromasia & mitotic figures)
22. Cells breaking through floor: SCC in situ can progress to invasive carcinoma (invades BM)
23. Pearl necklaces: well-differentiated SCC exhibits **keratin pearls & intercellular bridges**
24. Necrotic skull in cavity: may exhibit central necrosis & cavitation



3.1 - Lung Carcinoma

Paraneoplastic syndromes

25. Raised calcium cup: **humoral hypercalcemia of malignancy** (s"ca++"mous CC) (PTHrP release from tumor)
26. Knocked out PhD & PhD in disguise: humoral hypercalcemia of malignancy is assoc. w. suppressed PTH levels (PTH-independent hypercalcemia) and is caused by PTH related protein (PTHrP) release from tumor

Adenocarcinoma (non-small cell lung carcinoma) – "Dining Den"

27. "No smoking" in Dining Den: MC type of lung CA in non-smokers
28. Young lunch lady: MC lung CA in women and patients < 40 y/o
29. Smoker in Dining Den: MC type of lung CA (in smokers and non-smokers)
30. Glandular hair net: glandular characteristics on histology (e.g. acinar, papillary, mucinous)
31. Behind the glass plate: adenocarcinoma in situ (AIS) has not yet crossed the basement membrane (BM)
32. Layer lining food containers: AIS consists of tall columnar cells spreading along alveolar septae (appears to thicken alveolar walls)
33. Leopard print: surface alveolar growth (as seen in AIS) is called LEPIDIC growth pattern
34. Coughing up mucus: cells in AIS and adenocarcinoma can be mucinous → mucus production, copious sputum production
35. Mucus blob on chest: AIS may present like pneumonia on CXR (hazy consolidation)
36. Jello cubes beyond glass barrier: adenocarcinoma has cuboidal to **low columnar cells** (hyperchromatic with prominent nuclei)

Paraneoplastic syndromes

37. Clubbed fingers: **hypertrophic osteoarthropathy** (HOA) (digital clubbing)
38. Wrapped joints: HOA causes sudden arthropathy of the hands and wrists (less commonly elbows, knees, ankles)

Large cell carcinoma (non-small cell) – Large prison inmate contains large undifferentiated anaplastic cells (with large nuclei & prominent nucleoli)

Regional tumor spread to mediastinum

39. Wet pleural shirt & pericardial case: lung CA can cause **pleural & pericardial effusions**
40. "Pancoast Airlines": **Pancoast syndrome** occurs with regional tumor spread to superior pulmonary sulcus
41. Electric plexus fence: Pancoast tumors can invade the medial roots of the brachial plexus causing shoulder pain, arm/neck pain, hand muscle wasting
42. Air raid horn: **Horner's syndrome** occurs with regional tumor spread to the sympathetic chain ganglia
43. Droopy search light & constrictive horn: ptosis, miosis (and anhydrosis) in Horner's
44. Mediastinal mast: lung CA may extend medially involving mediastinal structures
45. Horse with laryngeal reigns: hoarseness due to **recurrent laryngeal nerve involvement**
46. Red balloon face: **SCV syndrome** → compression of superior vena cava causes swelling of face, neck & UE

Renal Pathology



1.1 - Renal Function Tests & AKI

1. Credit card: creatinine (used to measure kidney function)
2. "$1 MENU": creatinine has a normal serum concentration of ~1.0 mg/dL (ranging from 0.6 to 1.2)
3. "Free filtered": creatinine is freely filtered at the glomerulus
4. "NEVER REABSORBED!": once in the nephron, creatinine is NOT resorbed and only minorly secreted (Cr filtered load ≈ Cr urinary excretion)
5. "*May contain minor secretions": creatinine is secreted in small amounts into the nephron → urine conc. is slightly higher than serum conc. (slightly overestimate GFR)
6. "Grounds Filter Rate": glomerular filtration rate (GFR) is the amount of fluid that filters across the glomerulus into Bowman's space (~125ml/min)
7. Credit card cleared: creatinine clearance can be used to approximate GFR (slight overestimation) because Cr is freely filtered at the glomerulus and is neither secreted (almost!) nor reabsorbed
8. "CUP → ": C=UV/P (creatinine clearance equation used to estimate GFR)
9. "100% real": creatinine clearance (estimation of GFR) is normally >100 ml/min mg/dL (<100 ml/min is abnormal, <10 indicates renal failure)
10. Elderly man knocking over filtered coffee: GFR decreases with age (renal dosing of drugs)
11. BUN bag: Blood Urea Nitrogen (BUN) is cleared by the kidney (final breakdown product of nitrogen containing compounds)
12. "N" order cycle: BUN comes from the urea cycle in the liver (amino acid metabolism
13. Pyrimidine hexagon titles: BUN also comes pyrimidine metabolism (nitrogenous bases)
14. "Order 10": BUN has a normal serum concentration of ~10 mg/dL (ranging from 7-20)
15. Spilled filtered coffee: a decrease in GFR (renal injury or dysfunction) will cause an increase in BUN
16. "Pro Car Track" absorbing BUN grease: once in the nephron BUN is actively reabsorbed at the Proximal Convoluted Tubule
17. MEGAKING: Acute Kidney Injury (acute pre-renal, renal, or post-renal azotemia)
18. Trickle next to credit card: Acute Kidney Injury (AKI) manifests as increased serum creatinine and/or decreased urine output (oliguria)
19. Ketchup hemorrhage: hypovolemia or hemorrhage can cause PRE-RENAL AKI (kidney is hypoperfused)
20. Failing heart balloon: low output states (e.g. heart failure, shock) can cause PRE-RENAL AKI (kidney is hypoperfused)
21. BUN grease reabsorption: urea resorption in the proximal tubule is INCREASED during low perfusion states → INCREASED BUN/Cr ratio (>15)
22. Lifted BUN bag over credit card: increased BUN/Cr ratio (>15) in PRE-RENAL AKI
23. FENa fries dropping: decreased fractional excretion of sodium (FENa <1%) in PRE-RENAL AKI (sodium is conserved during low perfusion states)

Renal Pathology



1.1 - Renal Function Tests & AKI

24. "UP/UP N away!": UNaPCr/PNaUCr (FENa equation used to assess ability to reabsorb sodium)
25. Pepper in the consOSMents: PRE-RENAL AKI is associated with a UOsm >500 (concentrated urine to conserve volume)
26. Necrotic chocolate straw: acute tubular necrosis (ATN) is the most common cause of INTRINSIC RENAL AKI
27. Blue spotted kidney tray: acute interstitial nephritis (AIN) causes INTRINSIC RENAL AKI
28. Dripping glomerular curly straw: glomerulonephritis can cause INTRINSIC RENAL AKI
29. Falling BUN Bag over Credit card: BUN/Cr ratio >15 in INTRINSIC RENAL AKI (but both BUN and Cr are elevated)
30. Elevated FENa fries: FENa is >2% in INTRINSIC RENAL AKI (unable to reabsorb sodium)
31. Empty condOSMents bottle: INTRINSIC AKI is associated with a UOsm <350 (unable to conserve water)
32. Elevated BUN bag over Credit card: the BUN/Cre is >15 in POST-RENAL AKI (back-pressure enhances urea reabsorption)
33. Obstructive spit balls: bilateral nephrolithiasis can cause POST-RENAL AKI
34. BPH Fire hat: benign prostatic hyperplasia (BPH) can cause POST-RENAL AKI
35. Cancer crab buckle: cancer of the ureter, bladder, or urethra can also cause POST-RENAL AKI
36. Fallen BUN bag and Credit card: the BUN/Cr ratio can be decreased in severe or prolonged POST-RENAL AKI
37. Toys behind cracked kidney glass: AKI can cause hyperkalemia, acidosis, hypertension, and uremia (see chronic kidney disease video)

Renal Pathology



1.2 - Acute Tubular Necrosis

1. Necrotic muddy drain pipe: acute tubular necrosis (ATN) is the most common form of acute kidney injury (AKI)
2. Ischemic zombie: ATN is caused by ischemia of tubule cells
3. Empty kidney water gun: ATN is usually caused by decreased renal perfusion (prerenal AKI)
4. Bloody wound: severe blood loss → systemic hypoperfusion → prerenal AKI → ischemic damage to kidney → ATN
5. Broken heart string: MI → systemic hypoperfusion → prerenal AKI → ischemic damage to kidney → ATN
6. Constricted red exhaust pipe: ischemia damages endothelial cells → decreased nitric oxide (vasodilator) and increased endothelin (vasoconstrictor) production
7. Constricted red sleeve: ischemic injury to the endothelium of the afferent arteriole leads to vasoconstriction
8. Zombies stuck at AFFERENT entry way: vasoconstriction of the damaged afferent endothelium impedes blood flow to the glomerulus
9. Broken grounds filter rate: glomerular filtration rate (GFR) is decreased in ATN
10. Muddy epithelial leaves: ATN causes “muddy brown” casts in the urine sediment (sloughed tubular cells)
11. Obstructing epithelial leaves: sloughed epithelial cells accumulate in the tubular lumen, causing obstruction
12. Mud spilling on grounds filter rate: obstruction of tubular lumen by sloughed tubular cells in ATN further reduces GFR
13. Broken down PRO CART TRACK: The proximal convoluted tubule is particularly susceptible to ischemic injury in ATN
14. Broken down loop-de-loop: The thick ascending limb of the loop of henle is particularly susceptible to ischemic injury in ATN
15. Patchy tube lining: in ATN, the nephron will show dilated tubules with a patchy loss of epithelial cells
16. Broken tube edge and rusty holes: in ATN, sections of the nephron will show ruptured basement membrane and vacuolization of epithelial cells
17. “Come on IN”: the initial insult (e.g. MI, sepsis, hemorrhage) occurs during the INITIATION phase of ATN (lasts ~ 36 hours)
18. Smiling clown face: the INITIATION phase of ATN is associated with fairly normal kidney function and urine output
19. Maintenance shed: AKI develops during the MAINTENANCE phase of ATN with severe metabolic derangements and reduced urine output (lasts ~1-2 weeks after initial insult)
20. Cracked kidney on maintenance shed: the maintenance phase of ATN is associated with symptoms of AKI (e.g. oliguria, increased creatinine, fluid overload, metabolic abnormalities)
21. BUN bag: BUN is elevated during the maintenance phase of ATN
22. Credit card slot: creatinine is elevated during the maintenance phase of ATN



1.2 - Acute Tubular Necrosis

23. Trickle: the maintenance phase of ATN is associated with oliguria (<400mL/24hr)
24. Covering up with epithelial jacket: tubular re-epithelialization occurs during the recovery phase of ATN (!1-2 weeks after initial insult)
25. Wet crotch: the recovery phase of ATN is marked by profound diuresis (urine output up to 3-5 L/day)
26. Spilled banana peels, peanut shells, Calci-Yum cups, and magazine trash: the recovery phase of ATN can cause electrolyte abnormalities (e.g. hypokalemia, hyponatremia, hypocalcemia, and hypomagnesemia)
27. Toxic waste at the Pro Cart Track: the proximal convoluted tubule is the primary site of injury in NEPHROTOXIC ATN
28. Sai weapon: aminoglycosides can cause nephrotoxic ATN
29. Chomped chicken leg: damaged muscle (e.g. crush injury, rhabdomyolysis) can cause nephrotoxic ATN
30. Heme ninja stars: damaged muscle releases nephrotoxic heme pigments into the bloodstream → nephrotoxic ATN
31. Yin-yang: IV contrast can cause nephrotoxic ATN

Renal Pathology



1.3 - Tubulointersititial Nephritis

1. Flaming kidney: tubulointerstitial nephritis (e.g. acute interstitial nephritis - AIN) is associated with acute renal interstitial inflammation
2. Anti-inflammatory fire extinguisher: NSAIDs can precipitate acute interstitial nephritis (AIN)
3. Furious kid under the loop de loop: furosemide (a loop diuretic) can precipitate AIN
4. Pencils in kidney: penicillin can precipitate AIN
5. Stinky sulfur eggs: sulfonamide drugs (e.g. TMP/SMX) can precipitate AIN
6. Degranulating bee hive: drug-induced interstitial nephritis can be mediated by a type I hypersensitivity reaction (cross-linking Ig-E on mast cells → release of proinflammatory substances)
7. Helper squire running by cage: drug-induced interstitial nephritis can be mediated by a type IV ("delayed-type") hypersensitivity reaction (antigen presenting cells activate TH2 helper T-cells)
8. Blue lights dotting kidney: AIN shows interstitial edema with a diffuse inflammatory infiltrate on histology
9. Slingshot with pink granules: AIN can cause eosinophilia
10. Eo-slingshot granules in puddle: AIN can cause eosinophiluria
11. White knights, squires, and archers in puddle: AIN can present with white blood cell casts
12. BUN bag and credit card: AIN can present with elevated serum BUN and creatinine)
13. Trickling water: AIN can present with oliguria
14. Cracked kidney mirror: AIN causes intrinsic AKI (elevated serum BUN and creatinine and numerous metabolic and hemodynamic derangements)
15. Flaming head: AIN can present with fever
16. Spotted clown outfit: AIN can present with rash
17. Delayed demolition: AIN symptoms occur 1-2 weeks after inciting agent (type IV hypersensitivity reaction)
18. Chronic grandfather clock: chronic tubulointerstitial nephritis (TIN) (e.g. analgesic nephropathy)
19. Anti-inflammatory fire extinguisher: chronic NSAID use can cause analgesic nephropathy (chronic TIN)
20. Kicking in the BACK: Chronic pain patients (e.g. BACK pain, migraines) are at risk for chronic TIN due to chronic NSAID use
21. Pointy pyramids in renal tunnel: NSAIDs accumulate at the renal papillae (the tips of medullary pyramids)

Renal Pathology



1.3 - Tubulointersititial Nephritis

22. Oxidizing sparks: NSAIDs cause injury to the renal interstitium via free radical damage
23. Patchy blue sparks: → NSAIDs cause patchy inflammation in the renal interstitium
24. Calcium deposits: NSAIDs cause calcification in renal papillae (in areas of chronic inflammation)
25. Fibrotic bush: chronic inflammation in analgesic nephropathy causes interstitial fibrosis
26. Decaying pyramids in renal tunnel: in analgesic nephropathy causes microvascular damage AND vasoconstriction of afferent renal vessels → ischemia → renal papillary necrosis
27. Shrunken kidney pendulums: chronic TIN causes chronic kidney disease → bilaterally small scarred kidneys
28. Lead paint cans: chronic lead exposure can cause chronic TIN (i.e. lead nephropathy)
29. “Liftium”: chronic lithium use can cause chronic TIN
30. Antibody lights: autoimmune diseases (e.g. Sjögren syndrome, lupus) can cause chronic TIN

Renal Pathology



2.1 - The Nephrotic Syndrome

1. Endothelial shields: glomerular capillary (ENDOTHELIUM)
2. The wall: the glomerular basement membrane is thick, electron dense, and made of collagen, laminins, and glycoproteins
3. Minus signs: the GBM is normally negatively charged
4. Foot soldiers: podocytes (EPITHELIUM) have foot processes with filtration slits (selectively permeable)
5. Supportive field: the mesangium surrounds the capillaries and provides structural support to the glomerulus
6. Excretory river: Bowman's space→ renal tubule
7. Falling minus bricks: injury to the basement membrane can cause loss of negative charge → NEPHROTIC syndrome
8. Coins: in NEPHROTIC syndrome, injury to the glomerulus via cytokines (NOT cellular infiltrate, inflammation) → NEPHROTIC syndrome
9. Meat cart #35: NEPHROTIC syndrome is characterized by marked PROTEINURIA (> 3.5 grams/day)
10. Falling album: NEPHROTIC syndrome is characterized by HYPOALBUMINEMIA due to loss of albumin into the urine (hyperalbuminuria)
11. Edematous king: hypoalbuminemia → decreased oncotic pressure → fluid shifts into interstitium → generalized edema (NEPHROTIC syndrome)
12. Butter in front of liver tent: hypoalbuminemia → liver synthesis of proteins (including lipoproteins) → hyperlipidemia (NEPHROTIC SYNDROME)
13. Fat oval pigs: fatty casts and "oval fat bodies" in urine (lipiduria)
14. Dropping throm-beaver cage: proteinuria includes loss of antithrombin III → hypercoagulable state
15. Stained with red paint: amyloid appears pink when stained with Congo red
16. Firewood thrombus: decreased antithrombin III → increased thrombin activity (hypercoagulable state)
17. Stabbing in flank: hypercoagulable state → renal vein thrombosis (flank pain, gross hematuria)
18. Wormy left pant leg: left renal vein thrombosis can cause left varicocele
19. Falling antibody keys: proteinuria includes loss of gamma-globulins in the urine → hypogammaglobulinemia → increased risk of encapsulated bacterial infections
20. Frothy river: massive proteinuria can cause frothy urine
21. "MINIMUM": minimal change disease primarily affects children and causes "minimal" changes on histology (normal light microscopy, no immune complexes on immunofluorescence)
22. Hugging kid foot soldiers: minimal change disease causes podocyte effacement and fusion (visible on electron microscopy)
23. Cowering footsoldier: podocytes effacement, slit diaphragm disruption, depletion → NEPHROTIC SYNDROME
24. Blowing nose: minimal change disease develops several weeks after an upper respiratory infection, allergic reaction, insect sting, or immunization
25. Photos falling from album: minimal change disease causes selective leakage of albumin ("selective albuminuria") due to loss of negative charge on the basement membrane

Renal Pathology



2.1 - The Nephrotic Syndrome

26. Moon face: minimal change disease responds glucocorticoids
27. “FOCAL ATTACK”: focal segmental glomerulosclerosis (FSGS) is “focal” (affecting only some glomeruli)
28. “SEGMENTAL ATTACK”: focal segmental glomerulosclerosis (FSGS) is “segmental” (affecting only some segments of a glomerulus)
29. SCALY sclerotic snake: focal segmental glomerulosclerosis (FSGS) causes sclerosis (light microscopy shows: obliterated capillaries with hyalin deposition)
30. Hugging foot soldiers: FSGS causes podocyte effacement and fusion (visible on electron microscopy)
31. Cracked kidney rocks: FSGS frequently causes end stage kidney disease
32. Virus lantern: FSGS can be caused by viral infections (HIV, hepatitis)
33. Syringe: FSGS can be caused by heroin abuse or systemic disease (diabetes, hypertension, vasculitis, sickle cell)
34. Glycosylated kidney lollipops: diabetic nephropathy generally causes a nephrotic syndrome
35. Wall thickened by pink deposits: early on, diabetic nephropathy causes basement membrane thickening (due to nonenzymatic glycosylation)
36. Big pink lollipop in mesangial field: later stage of diabetic nephropathy causes nodular glomerulosclerosis, characterized by Kimmelstiel-Wilson nodules (light microscopy shows pink round deposits of laminated mesangial matrix)
37. SCALY sclerotic snake: nodular glomerulosclerosis (diabetic nephropathy) causes sclerosis (light microscopy shows: obliterated capillaries with hyalin deposition)
38. Wall thickened by long cape: membranous glomerulopathy causes diffuse thickening of the glomerular basement membrane (visible on light microscopy)
39. Antibody arrows injuring foot soldier: membranous nephropathy can be caused by autoantibodies against the phospholipase A2 receptor on podocytes → leads to subepithelial antibody deposits)
40. Dome-like helmet decorated with spikes: subepithelial deposits have a “spike and dome” appearance on electron microscopy (in membranous glomerulopathy)
41. Wall engulfing antibody arrows: “spike” appearance is due to the basement membrane engulfing “domes” of subepithelial immune deposits (visible on electron microscopy in membranous glomerulopathy)
42. Crab chest plate: membranous nephropathy can be secondary to solid tumors (lung, breast, prostate, colon)
43. Viral quiver: membranous nephropathy can be secondary to viral infections (hepatitis B or C)
44. Lupus wolf: membranous nephropathy can be secondary to lupus erythematosus
45. Fluorescent green arrows: immunofluorescence microscopy shows granular deposits of immunoglobulin and complement along the basement membrane (in membranous glomerulopathy)
46. Green perfume bottle: amyloid displays apple green birefringence in polarized light
47. Moon shield: membranous nephropathy can be treated with corticosteroids
48. Armored lady: amyloidosis (a systemic disorder that involves deposition of misfolded proteins in tissues) can cause nephrotic syndrome
49. Armoured lady in mesangial field: in early renal amyloidosis, there are focal amyloid deposits within the mesangium
50. Armoured lady in capillary circle: in later renal amyloidosis, amyloid obliterates glomerular capillaries

Renal Pathology



2.2 - The Nephritic Syndrome

1. Supportive field: the mesangium surrounds the capillaries and provides structural support to the glomerulus
2. Circle of endothelial warriors: glomerular capillary (ENDOTHELIUM)
3. The Great Wall: the glomerular basement membrane
4. Footsoldiers: podocytes (EPITHELIUM) have foot processes with filtration slits (selectively permeable)
5. Excretory river: Bowman's space→ renal tubule
6. Endothelial warriors around **fire**: in nephritic syndrome, glomerular injury is a result of **inflammation**
7. First responders carrying away endothelial warrior: inflammatory infiltrate (including neutrophils) → glomerular **capillary damage** → hematuria and AKI (nephritic syndrome)
8. Blood in river: nephritic syndrome is characterized by hematuria (gross or microscopic)
9. Dysmorphic red soldier: nephritic syndrome presents with dysmorphic RBCs (hallmark of **glomerular** injury)
10. Collecting red helmets: nephritic syndrome presents with RBC casts (hallmark of **glomerular** injury)
11. White soldier in river: nephritic syndromes can present with WBC in the urine sediment
12. Collecting white helmets: nephritic syndrome can present with WBC casts
13. Trickle: nephritic syndromes can present with oliguria (AKI)
14. High pressure steam: nephritic syndromes can present with hypertension (due to salt and volume retention)
15. Puffy face: nephritic syndromes can cause periorbital (and less commonly peripheral) edema (due to salt and volume retention)
16. Raised BUN bag: nephritic syndrome can present with an elevated BUN and creatinine (AKI)
17. Dropped meats: nephritic syndrome causes proteinuria (> 150 mg/day - less than nephrotic range of 3.5 g/day)
18. IgA dummy soldiers in the field: IgA nephropathy (Berger disease) is caused by deposition of IgA and IgA immune complexes in the mesangium)
19. Blowing nose and grabbing stomach: IgA nephropathy may present 1-2 days after an upper respiratory or GI infection (abnormal IgA synthesis and glycosylation)
20. Berger: Berger disease (IgA nephropathy)



2.2 - The Nephritic Syndrome

21. Blood trickling: IgA nephropathy usually presents with gross hematuria that lasts for several days
22. Periodic blood puddles: patients with IgA nephropathy may have episodic hematuria
23. Shoeshine: Henoch-Schonlein purpura (HSP) causes a renal disease similar to IgA nephropathy
24. Proliferating army in the field: focal or diffuse mesangial proliferation (IgA nephropathy, post-strep, diffuse proliferative, membranoproliferative glomerulonephritis, dense deposit disease
25. Granular green glow: immunofluorescence shows a granular pattern in the mesangium due to IgA immune complex deposition
26. Moon-face shield: IgA nephropathy can be treated with glucocorticoids
27. Pyogenes pie: post-streptococcal glomerulonephritis (PSGN)
28. **Membranous** sash along wall: **membrano**proliferative glomerulonephritis (MPGN) causes diffuse GBM thickening
29. Pie on face and neckerchief: PSGN can occur after group A strep (Strep. pyogenes) infection, including pharyngitis OR skin infection
30. Pie in mesangial field: PSGN is associated with immune complex deposition in the mesangium
31. Pie behind endothelial soldiers: PSGN is associated with subendothelial immune complex deposition
32. Pie landing on the back of epithelial foot soldier: PSGN is associated with subepithelial immune complex deposition
33. “Week 3” on calendar: post-streptococcal glomerulonephritis (PSGN) occurs 1-3 weeks after a skin or pharyngeal infection with nephritogenic strains of group A strep
34. Cola bottles: hematuria in PSGN is often described as “cola-colored”
35. First responders with blueberry pie: in PSGN, light microscopy shows marked leukocyte infiltration (lots of nuclei present) in the mesangium and endothelium
36. Granular green pie tins: in PSGN, immunofluorescence microscopy shows granular pattern (due to IC deposition)
37. Lysed donuts and helical donuts: serum antistreptolysin-O (ASO) and anti-DNase B titers may be elevated after a group A strep infection (ASO less likely with skin infection)
38. Diffusely proliferating lupus wolves: diffuse proliferative glomerulonephritis is the most common presentation of lupus nephritis
39. Antibody posts holding double helix: DNA anti-DNA immune complexes (seen in diffuse proliferative glomerulonephritis)
40. Double helical fence around endothelial soldiers: DNA anti-DNA immune complexes deposit in the subendothelial space (diffuse proliferative glomerulonephropathy)


2.2 - The Nephritic Syndrome

41. Looped wire around endothelial soldiers: light microscopy shows “wire looping” of the capillaries due to subendothelial immune complex deposition (diffuse proliferative glomerulonephritis)
42. Green granular glow: immunofluorescence shows a granular pattern due to immune complex deposition
43. Moon-face shield: treatment of diffuse proliferative glomerulonephritis with glucocorticoids and cyclophosphamide may slow progression to chronic kidney disease
44. Lobulated shovel: light microscopy shows hypercellularity and enlarged, lobular glomeruli (MPGN)
45. Wall splitting: electron and light microscopy show splitting of the glomerular basement membrane due to ingrowth of mesangium (“tram tracking”) (MPGN)
46. Just walk it off, buddy. You'll be fine.
47. Viral, bacterial, and antibody lanterns: MPGN can be caused by viral infections (hepatitis B or C), bacterial infections (endocarditis, shunt nephritis), or autoimmune diseases (due to chronic IC formation)
48. IC lanterns behind endothelial soldiers: immune complexes deposit in **subendothelial** space (MPGN)
49. IC lanterns behind endothelial soldiers: immune complexes deposit in subendothelial space (MPGN)
50. Dense bomb deposits: dense deposit disease involves deposition of a material of unknown composition in the basement membrane
51. Dense ribbon: the GBM eventually transforms into a long irregular and extremely electron-dense ribbon (DDD)
52. Excessive complements: dense deposit disease is associated with overactivation of the alternative complement pathway
53. 3 friendship bracelets: dense deposit disease is associated with the formation of the autoantibody, C3 nephritic factor → stabilized C3 convertase → overactive alternative pathway (low C3 with normal C4)
54. Deadly crescent weapon: rapidly progressive glomerulonephritis (RPGN) causes crescents in the glomerulus (rapid decline in kidney function)
55. Deadly IC mace: immune-complex mediated glomerulonephritides (e.g. PSGN, diffuse proliferative glomerulonephritis, IgA nephropathy, HSP) can lead to RPGN
56. Decaying break in wall: on light microscopy, RPGN glomeruli will show segmental necrosis and breaks in the glomerular basement membrane
57. Scattered fibrous twigs: plasma proteins and fibrin deposit in the crescents formed in RPGN
58. Advancing epithelial army: crescent formation in RPGN is caused by epithelial cell proliferation from the capsule (parietal) → obliteration of Bowman’s space

Renal Pathology


2.2 - The Nephritic Syndrome

59. Green granular glow: immunofluorescence microscopy shows a granular pattern in the immune complex glomerulonephritides progressing to RPGN
60. Crescent warrior shooting ankle: pauci-immune RPGN (no IC deposition) may be associated with anti-neutrophilic autoimmune vasculitides like Wegener's granulomatosis (c-ANCA) and microscopic polyangiitis (p-ANCA)
61. Crescent warrior shooting wall: anti-GBM antibody-mediated RPGN (e.g. Goodpasture's disease) is caused by antibodies directed against antigens in the GBM
62. Linear layer of green arrows: anti-GBM antibody-mediated RPGN shows a linear pattern on immunofluorescence microscopy
63. Blood on chest: while anti-GBM can be isolated to the kidney, involvement of the pulmonary capillary bed leads hemoptysis (Goodpasture's syndrome)
64. "IV": anti-GBM antibody-mediated RPGN involves IgG autoantibodies directed against type IV collagen in the GBM (also pulmonary capillaries in Goodpasture's)

Renal Pathology



3.1 - Congenital & Cystic Kidney Disease

1. Horseshoe game: horseshoe kidney (the most common congenital renal malformation)
2. Caught on inferior post: during embryologic ascent, a horseshoe kidney gets stuck at the inferior mesenteric artery
3. X shaped pinwheel toys: Turner syndrome (monosomy X) is associated with horseshoe kidney
4. Cancer crab toy: horseshoe kidney increases risk of Wilms tumor
5. Stones in the dunk tank: congenital and cystic disorders of the kidney (e.g polycystic kidney disease) increased risk of kidney stones
6. Red dunk tank water: congenital and cystic disorders of the kidney (e.g polycystic kidney disease) can present with hematuria and flank pain (due to kidney stones)
7. Infected bladder cup: congenital and cystic disorders of the kidney (e.g polycystic kidney disease) can increase risk of urinary tract infections
8. Recurring bacterial lanterns: congenital and cystic disorders of the kidney (e.g polycystic kidney disease) can cause recurrent urinary tract infections
9. Dysplastic bunch of balloons: renal dysplasia (abnormal development of one or both kidneys) is the most common cystic disease in children
10. Dysplastic shark toy: renal dysplasia is associated with abnormal mesenchymal tissue (e.g. cartilage and bone)
11. Popped kidney balloon: renal agenesis (congenital absence of renal parenchyma)
12. Tightly wrapped Potter the bear: bilateral renal agenesis can result in oligohydramnios → Potter sequence (flattened nose, clubfeet, lung hypoplasia)
13. Kid hiding from bunch of kidney balloons: autosomal recessive polycystic kidney disease (ARPKD - symptomatic in early childhood)
14. Balloon with little cysts: ARPKD can present with bilaterally enlarged kidneys with diffuse small cysts on fetal ultrasound
15. Corduroy fibers: ARPKD is caused by a mutation in PKHD1 (fibrocystin gene)
16. Stepping in collecting duct: in ARPKD, cysts develop in the collecting ducts
17. Square tiles lining collecting duct: in ARPKD, cysts are lined by cuboidal epithelium
18. Tightly wrapped Potter the bear: ARPKD can cause oligohydramnios → Potter sequence (flattened nose, clubfeet, lung hypoplasia)



3.1 - Congenital & Cystic Kidney Disease

19. Bulging flank: ARPKD can present with bilateral flank masses
20. High pressure steam: ARPKD can cause hypertension in first months of life
21. Balloons caught in liver tree: ARPKD can cause cystic dilation of intrahepatic bile ducts, hepatomegaly, and hepatic fibrosis
22. Domino: autosomal dominant polycystic kidney disease (ADPKD - usually presents in adulthood)
23. Polygon pattern: ADPKD is caused by a mutation in PKD1 or PKD2 (less common) which code for polycystin-1 and polycystin-2
24. Nephron fun zone sign: cysts in ARPKD develop throughout the nephron
25. Growing balloons: cysts in ARPKD grow larger over time
26. High pressure steam: ADPKD can cause hypertension
27. Popping balloon hat: ADPKD can cause berry aneurysms in the circle of willis → subarachnoid hemorrhage
28. Balloons caught in liver tree: ADPKD can also present with hepatic cysts
29. Pancreatic balloon bag: ADPKD can also present with pancreatic cysts
30. Balloon belt: ADPKD can also present with diverticulosis
31. Central sponge gloves: medullary sponge kidney (multiple cysts in renal medulla)
32. Cleaning the end of the collecting duct: the cysts in medullary sponge kidney develop along the terminal collecting duct
33. Dilated kidney water balloon: horseshoe kidney can cause hydronephrosis



3.2 - Chronic Kidney Disease (CKD)

1. Fossilized kidney-shaped eggs: chronic kidney disease (CKD) (kidneys appear bilaterally shrunken with a red-brown, diffusely granular surface)
2. Empty grounds filter rate: CKD presents with decreased GFR
3. Coffee levels 1-5: the 5 stages of CKD are defined by GFR, with stage 5 being end-stage renal disease requiring dialysis
4. Credit card: CKD presents with increased creatinine (decreased GFR → decreased Cr clearance)
5. Photo album: CKD presents with albuminuria due to kidney damage
6. 3 month expedition: CKD is diagnosed by 3 months of reduced GFR or elevated urine albumin
7. DiaSweeties candies: poorly controlled diabetes one of the MOST COMMON causes of CKD (due to microvascular damage)
8. High pressure steam: chronic hypertension is one of the MOST COMMON causes of CKD (due to microvascular damage)
9. Frayed glomerular knots: chronic glomerulonephritis can cause CKD
10. Kidney shaped bunch of balloons: polycystic kidney disease can cause CKD
11. Constricting red kidney straps: bilateral renal artery stenosis can cause CKD (due to ischemic nephropathy)
12. Pineapples: chronic pyelonephritis can cause CKD (due to progressive renal scarring)
13. Chomping glomerular reeds: initial injury leading to CKD
14. Mesozoic om nom nom
15. Tall glomerular reeds in the river: the remaining healthy glomeruli increase filtration to preserve GFR (adaptive hyperfiltration)
16. Dead glomerular reeds: the remaining hyperfunctioning glomeruli eventually become damaged by the extra load (labs start to show CKD)
17. Dry sclerotic glomerular reeds: CKD shows advanced scarring of the glomeruli on histology
18. Fibrotic kidney-shaped nest: CKD eventually leads to interstitial fibrosis
19. Acid volcano: CKD can cause metabolic acidosis due to impaired hydrogen excretion, impaired bicarbonate reabsorption, and accumulation of uric acid
20. Elevated bananas: CKD can cause hyperkalemia (due to decreased filtration of potassium due to decreased filtration of potassium and the H+/K+ buffering system with metabolic acidosis)
21. Wet body: CKD can cause fluid retention (leading to both diffuse and pulmonary edema)
22. Wax arm in water: CKD can present with waxy casts in the urine
23. High pressure steam: CKD can cause hypertension (due to volume overload)
24. Cracked draining kidney: CKD can cause a normocytic anemia (due to decreased erythropoietin production)



3.2 - Chronic Kidney Disease (CKD)

25. “P” fossils: CKD can cause hyperphosphatemia (due to decreased filtration and increased bone resorption in CKD-bone mineral disease)
26. Falling calci-yum ice cream: CKD can cause hypocalcemia (due to decreased vitamin D production and hyperphosphatemia)
27. Falling "D”: CKD can cause hypovitaminosis D (due decreased activity of 1-alpha-hydroxylase, and decreased production of 1,25-dihydroxyvitamin D)
28. PthD paleontologist: CKD can cause secondary hyperparathyroidism (hypocalcemia stimulates the parathyroid gland to release parathyroid hormone (PTH))
29. Bone fossil with dirt-filled holes: secondary hyperparathyroidism causes CKD-mineral and bone disorder (CKD-MBD) → osteitis fibrosa cystica (bone resorption causes cystic “brown tumors” that fill with fibrosis and hemosiderin)
30. Crumbling skeleton from Malaysia: secondary hyperparathyroidism and decreased vitamin D causes CKD-MBD → osteomalacia (decreased mineralization of bone osteoid)
31. “**JUREA**SSIC”: CKD can cause uremia (elevated BUN)
32. Vomiting: uremia can cause nausea and vomiting
33. Flapping wings: uremia can cause asterixis (tremulousness) and other serious neurologic effects
34. Broken plates: uremia can cause platelet dysfunction → pathologic hemorrhage throughout the body
35. Cracked heart shell: uremia can cause serous pericarditis (or hemorrhagic if comorbid with platelet dysfunction)
36. Brain-head dino: uremia can cause significant neurologic symptoms (e.g. peripheral neuropathy, encephalopathy, seizure, coma, death)
37. Little itchy mammal: uremia can cause severe pruritis
38. Clogged coronary crown: CKD is an independent risk factor for developing coronary artery disease

Renal Pathology



4.1 - Hydronephrosis & Urinary Tract Obstruction

1. Dilated pelvic and calyceal hoses: hydronephrosis (dilated renal pelvis and calyces)
2. Crushed deflated tire: hydronephrosis can cause pressure atrophy of the renal medulla and cortex
3. Tarnished papillary hubcap: sudden onset hydronephrosis can cause renal papillary necrosis
4. Horn sound: hydronephrosis can be diagnosed with ultrasound
5. Abdominal pocket mass: newborns with hydronephrosis can present with an abdominal mass
6. Kid kinking proximal hose: ureteropelvic junction obstruction is the most common cause of unilateral fetal hydronephrosis
7. Puddle girl spraying back water: vesicoureteral reflux (VUR) can cause hydronephrosis in children (unilateral or bilateral)
8. Right angled spray nozzle: perpendicular insertion of the ureters into the bladder can predispose to vesicoureteral reflux
9. Bladder juice boxes: VUR predisposes to recurrent urinary tract infections (UTIs)
10. Renal pineapple: VUR predisposes to chronic pyelonephritis → scarring
11. High pressure steam: VUR can cause hypertension (scarring from chronic pyelonephritis leads to renal insufficiency)
12. Obstructing top of urethral pole: posterior urethral valve can cause urinary tract obstruction in boys → hydronephrosis (bilateral)
13. Oh by all means, eat your fast food, enjoy your foam finger! Hey, even hack at a wall with a scalpel, guys...don't worry about this over here
14. Manly wolf shirt: posterior urethral valve is made up of a wolffian duct remnant
15. Tightly wrapped Potter the bear: posterior urethral valve can cause oligohydramnios → Potter sequence (flattened nose, clubfeet, lung hypoplasia)
16. Second dilated fire truck: obstruction distal to the ureters can cause bilateral hydronephrosis (e.g. VUR, posterior urethral valve, BPH)
17. Falling stones obstructing hose: urolithiasis is the most common cause of urinary tract obstruction in adults (can cause unilateral hydronephrosis)
18. Slashing scalpel axe: the ureters can become damaged or unintentionally ligated after pelvic surgery (causing urinary tract obstruction and unilateral hydronephrosis)
19. Recurrent bacterial lanterns: urinary tract outflow obstruction can cause recurrent UTIs
20. Stone striking flank: acute urinary tract obstruction (e.g. urolithiasis, surgical injury) can present as sharp flank pain radiating to the ipsilateral groin



4.1 - Hydronephrosis & Urinary Tract Obstruction

21. Bleeding down pant leg: acute urinary tract obstruction (e.g. urolithiasis, surgical injury) can present with gross hematuria
22. Nauseated firefighter: acute urinary tract obstruction (e.g. urolithiasis, surgical injury) can present with nausea and vomiting
23. Crab buckle: pelvic and abdominal cancers (e.g. bladder cancer, uterine cancer) can cause chronic urinary tract obstruction and hydronephrosis (unilateral or bilateral)
24. Fibrous back wall of trees: retroperitoneal fibrosis can cause chronic urinary tract obstruction and hydronephrosis (unilateral or bilateral)
25. 4 IgG lights: retroperitoneal fibrosis is associated with IgG-4 related systemic disease (including autoimmune pancreatitis, Riedel's thyroiditis, sclerosing aortitis)
26. Enlarged fire chief grabbing urethral pole: benign prostatic hyperplasia (BPH) is a common cause urinary tract obstruction in older men (can cause bilateral hydronephrosis)
27. Broken spinal power lines: neurogenic bladder (e.g. due to spinal cord injury, diabetes) can cause bilateral hydronephrosis
28. Fast food BUN bag and credit card: BILATERAL urinary tract obstruction can cause elevated serum BUN and creatinine (postrenal azotemia)

Renal Pathology



4.2 - Calcium oxalate stones & Calcium phosphate stones

1. Dried up river deposits: all renal stones form due to supersaturation (adequate hydration is cornerstone of treatment)
2. Milk dripping into river bed: high concentration of calcium in the renal tubule → calcium stones (calcium oxalate most common)
3. Ox in river bed: too much oxalate in the renal tubule → calcium oxalate stones
4. Milk dripping from udders: hypercalciuria (e.g. idiopathic, or due to hypercalcemia, chronic acidosis) can cause calcium stones
5. Normal milk bucket: hypercalciuria with normocalcemia → calcium stones
6. First place dairy cow: hypercalciuria with normocalcemia is the most common metabolic abnormality causing calcium stones
7. GI cow spot: absorptive hypercalciuria (excessive gut absorption of calcium) is the most common cause of hypercalciuria with normocalcemia
8. Leaking kidney milk bucket: renal hypercalciuria (defect in proximal reabsorption of calcium) can cause hypercalciuria with normocalcemia
9. Bone cow spot: resorptive hypercalciuria (excess resorption of calcium from the bone) can cause hypercalciuria with normocalcemia
10. Elevated milk buckets: hypercalcemia (e.g. due to PHPT, cancer) can cause hypercalciuria and calcium stones
11. Acid on bones: acidosis can cause hypercalciuria and calcium stones (calcium-phosphate buffer system)
12. Citrus crate with milk: citrate binds calcium in the renal tubules (soluble complex prevents stone formation
13. Acid miners: acidosis can cause calcium stones (due to hypocitraturia)
14. Acid miner grabbing citrus crate: acidemia promotes resorption of citrate from tubule → less citrate bound to calcium in tubule → calcium stones
15. Spewing mud: diarrhea can cause calcium stones (due to volume depletion, and acidemia with hypocitraturia)
16. Meat eater: high protein diets can cause calcium stones (acidemia causes hypocitraturia)
17. Crushed citrus crate: vitamin C deficiency can cause calcium stones (due to hypocirtaturia)
18. Cow eating salty peanuts: increased dietary sodium intake can cause calcium stones (reduced Na+ and Ca2+ reabsorption in the nephron through their symporter)
19. Spilling milk: decreased dietary calcium promotes calcium oxalate stone formation (due to increased GI absorption of unbound oxalate)



4.2 - Calcium oxalate stones & Calcium phosphate stones

20. Oxen stampede: increased oxalate GI absorption (e.g. due to decreased dietary Ca2+, vegan diet, malabsorption) promotes calcium oxalate stone formation
21. Ox eating plants: pure vegan diets (without calcium supplementation) can cause calcium oxalate stones
22. Milk collecting in damaged GI path: fat malabsorption (e.g. Crohn's, short gut) binds calcium in the gut → GI absorption of unbound oxalate → calcium oxalate stones
23. Fossil mining kids: calcium phosphate stones are the most common stone found in children
24. Acid cylinder: type 1 renal tubular acidosis (RTA) promotes calcium phosphate stone formation (acidemia, plus alkaline urine environment)
25. Elevated “pH” shape: alkaline urine environment promotes calcium pHosphate stone formation
26. Envelopes from ox cart: calcium oxalate crystals have an “envelope” shape on microscopy
27. Wedge shaped fossil mine car: calcium phosphate crystals have an “elongated wedge” shape on microscopy
28. Pale thighs: hydrochlorothiazide can help prevent calcium stone formation by increasing reabsorption of calcium in the distal tubule

Renal Pathology



4.3 - Magnesium Ammonium, Phosphate (MAP) Stones, Uric Acid Stones, & Cystine Stones

1. Frontier MAP: magnesium-ammonium-phosphate (MAP) renal stones (second most common in adult)
2. Stag antlers: MAP stones can present as “struvite” or “staghorn” calculi
3. Urease spray: MAP stones can form during UTI with urease positive organism (urea → ammonium + CO2)
4. Blue puddles: basic urine decreases the solubility of phosphate → MAP stone formation
5. Goblet with ureteral straws: MAP stones can form during a UTI with a urease positive organism (e.g. Proteus, S. Saprophyticus, Klebsiella)
6. Coffin lid: MAP crystals have a characteristic “coffin lid” or rectangular prism shape on microscopy
7. Needles in uric acid yarn: uric acid (urate) stones
8. Yarn ball on toe: gout causes hyperuricemia → uric acid stones
9. Raised white archers and knights: conditions with rapid cell turnover (e.g. leukemia and lymphoma) can cause hyperuricemia → uric acid stones
10. Falling shards: tumor lysis syndrome can cause hyperuricemia and uric acid stones
11. Mysterious acid secretions: idiopathic acidic urine (50% of patients with uric acid stone)
12. Acid puddles: uric acid stones preferentially form in an acidic urine environment
13. Draining mud: metabolic acidosis (e.g. caused by chronic diarrhea) → increased H+ excretion → uric acid stones
14. Dumping alkaline fluid: alkalinization of the urine (e.g. with potassium citrate, potassium bicarb) can effectively treat and prevent uric acid stones
15. Pure nun: allopurinol can prevent uric acid stones (with high cell turnover, or high purine metabolism)
16. Diamond windows: uric acid stones have characteristic diamond-shaped, yellow-brown crystals on microscopy
17. “Cistern”: cystine stones (occur in cystinuria)



4.3 - Magnesium Ammonium, Phosphate (MAP) Stones, Uric Acid Stones, & Cystine Stones

18. Acid pools: cystine stones form preferentially in an acidic urine environment
19. COAL: cystinuria is caused by a defect in PCT reabsorption of cystine, ornithine, arginine, and lysine
20. Receding shy kid: cystinuria is caused by an autosomal recessive defect of resorption of amino acids in the PCT
21. Kids carrying coal: cystinuria usually presents in childhood with recurrent, non-calcium, renal stones
22. Stag antler: cystine stones can also present as “stag-horn” calculi
23. Hexagonal coal briquettes: cystine crystals have a characteristic hexagonal shape on microscopy
24. Blue “Nitro-pressure” smoke: the diagnostic test for cystinuria is the sodium cyanide-nitroprusside urine test
25. Pink stream in the smoke: urine of a patient with cystinuria will turn red-purple in a positive sodium cyanide-nitroprusside test
26. Pencil MINE: in severe cases, penicillamine can be used to chelate and lower cystine levels (prevent cystine stones)
27. Grasping crane: chelating agent (penicillamine)
28. Translucent X-ray flag on church: uric acid and cystine stones are radiolucent (Calcium and MAP stones are radiopaque)
29. Translucent X-ray flag on COAL mine: uric acid and cystine stones are radiolucent (Calcium and MAP stones are radiopaque)