Arterial supply, venous and lymphatic drainage of upper limb

By Glenn André Breivik

studyaid

Agenda

1. Arterial supply:
- Arch of aorta anatomy review
- Subclavian artery with branches
- Axillary artery with branches
- Brachial artery with branches
- Arteries of the forearm with branches
- Arterial arches of the hand

2. Venous drainage

3. Lymphatic drainage

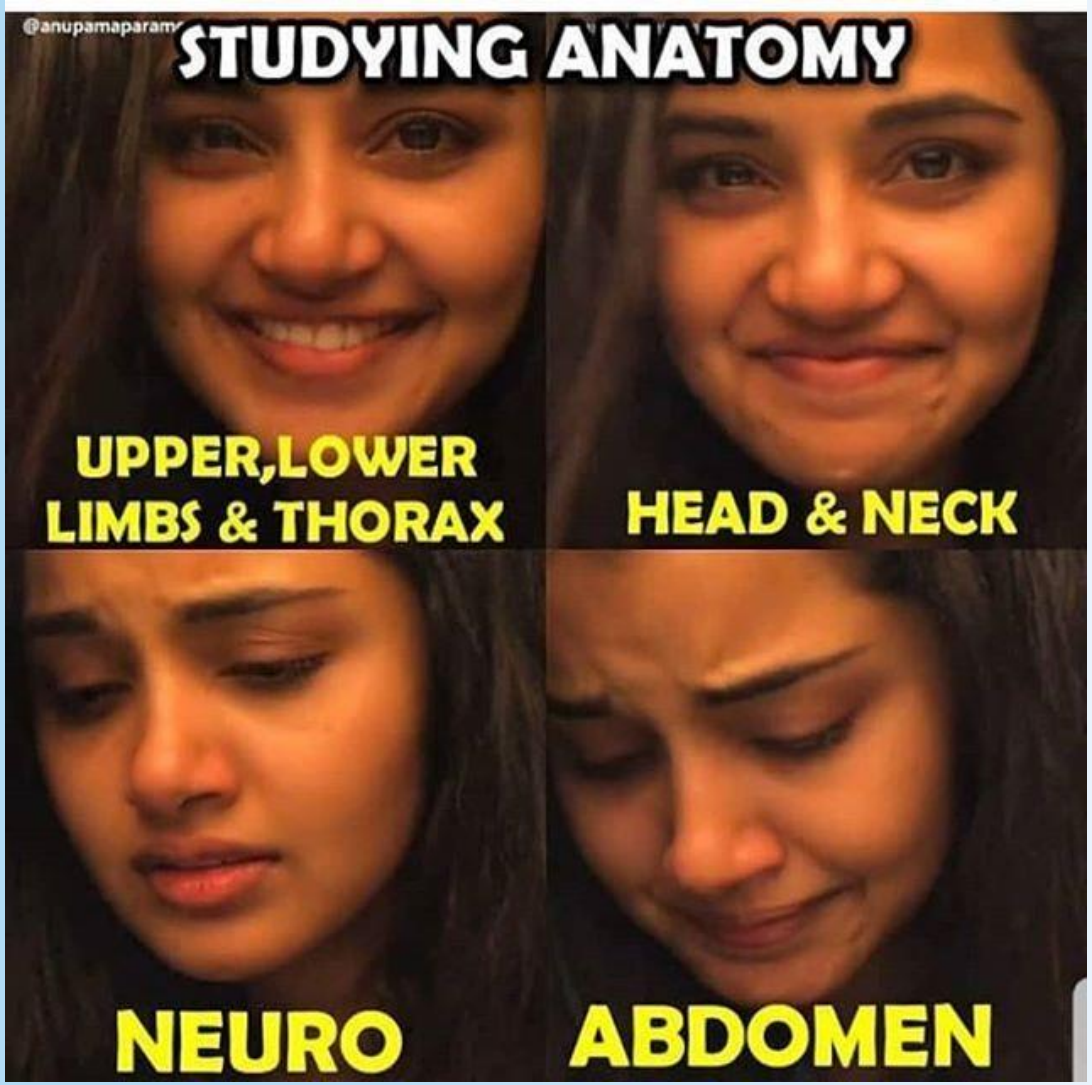

studyaid

Do you use mnemonics to learn anatomy?

Reconsider.

studyaid

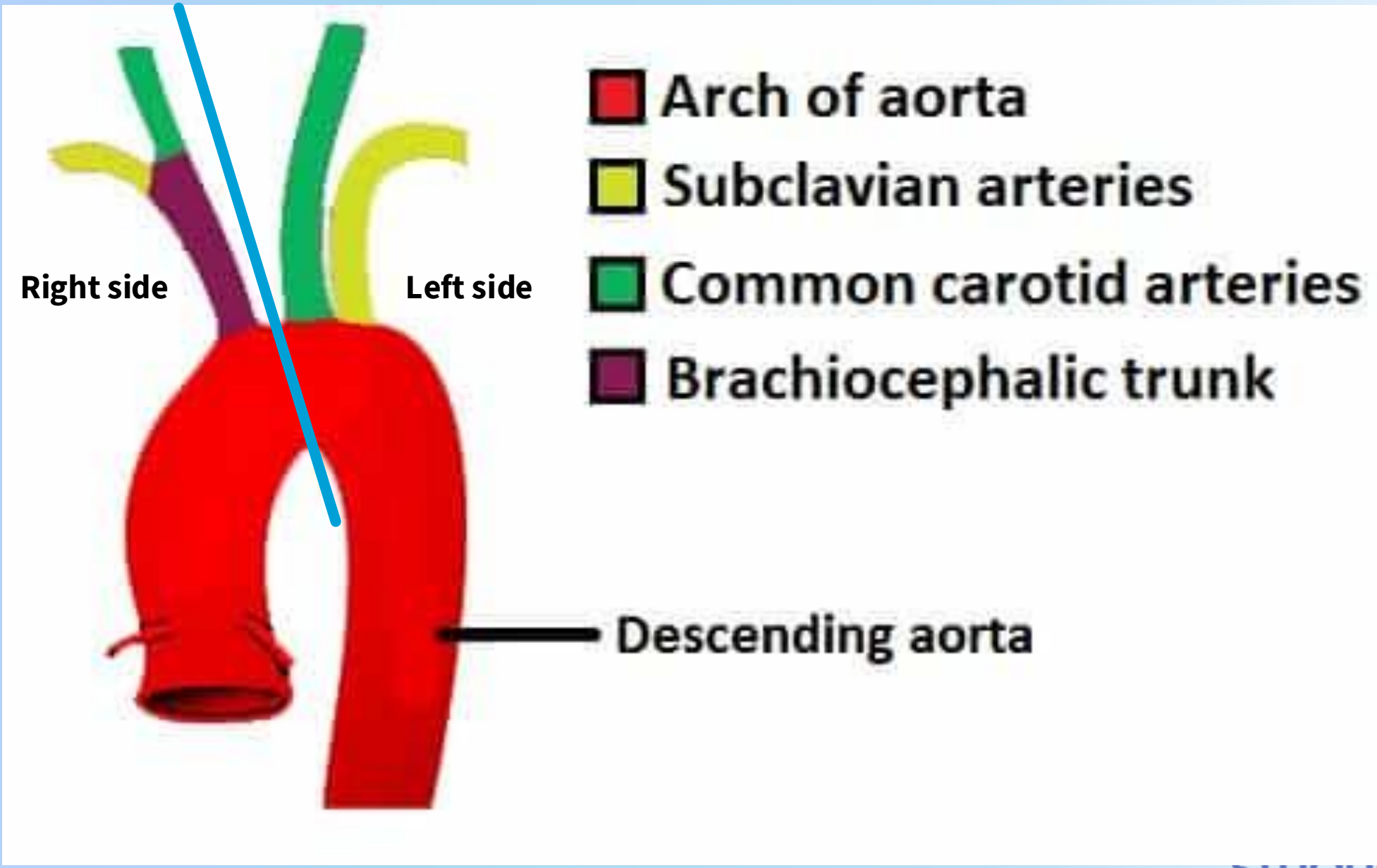
Right side
Left side
Arch of aorta
Subclavian arteries
Common carotid arteries
Brachiocephalic trunk
Descending aorta

Orientation of the subclavian artery

Common carotid artery

3rd segment = 1 branch

2nd segment = 1 branch

1st segment = 3 branches

3

2

1

311, Subclavian artery, what is your branchurgency?



Embryology:

First segment (proximal part) derives from the 4th pharyngeal arch!

And so does the arch of aorta!

Brachiocephalik trunk

Arch of aorta

Two major landmarks

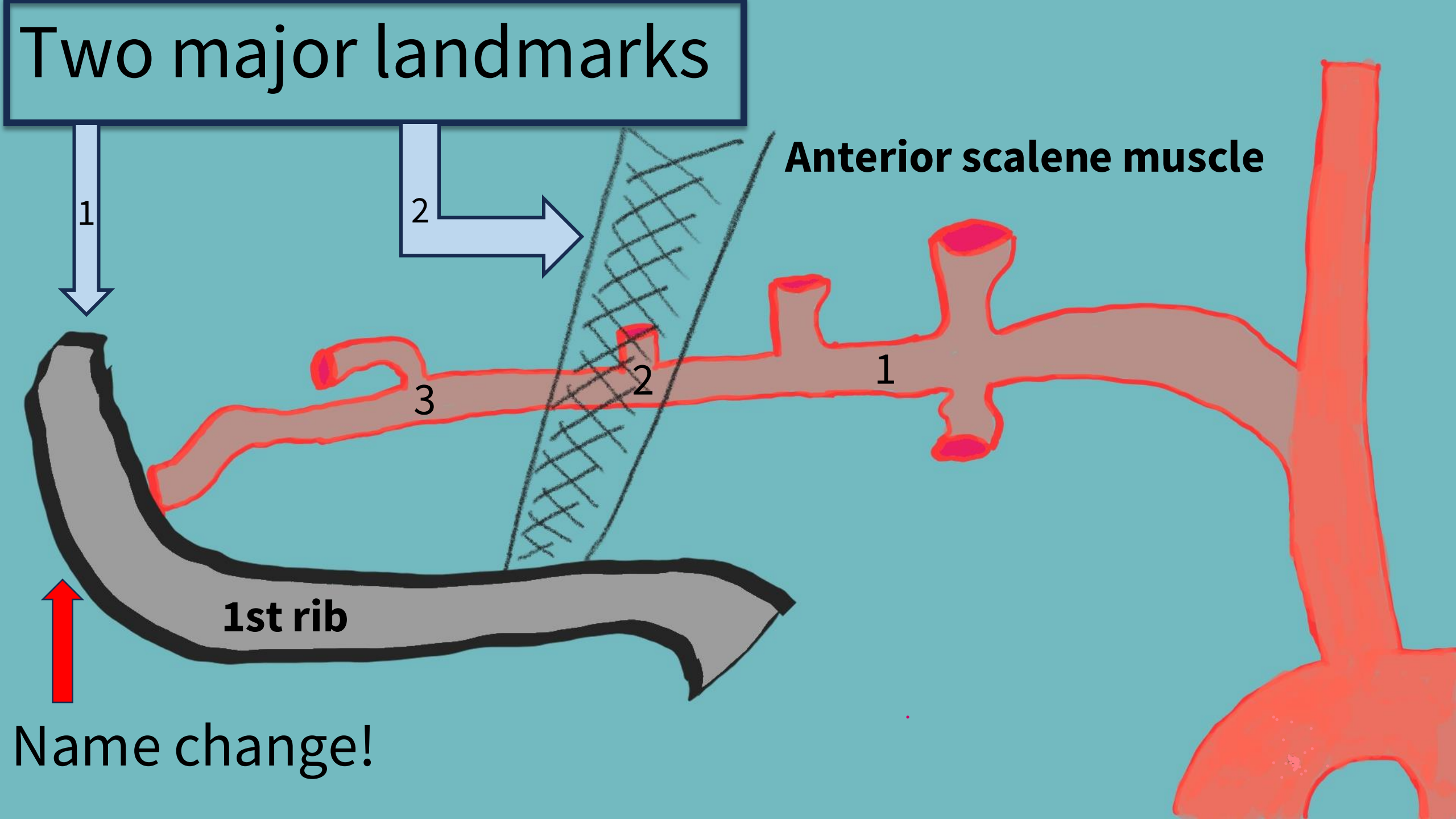

Name change!

Subclavian artery branches - first part

Vertebral artery

- Spinal cord (C1-C6)

- Brainstem

- Cerebellum & posterior part of brain

Thyrocervical

(Inferior thyroid artery, Suprascapular artery, Ascending and Transverse cervical arteries).

- **Thyroid**
- **cervical structures** (pharynx, larynx and *anterior* muscles of the neck)

- Scapula and trapezius muscle. (suprascapular artery)



Internal thoracic artery

- **Thoracic wall and breasts** (mammary artery)

- *Muscular part of the diaphragm* (musculophrenic artery)

- *Pericardium* (Pericardiophrenic artery)



studyaid

Subclavian artery branches - Second part

Costocervical

(Deep cervical artery and Superior intercostal artery)

- ***Ribs (costals)***
- *Parietal pleura*
- *C7 and T1 vertebrates*
- *Skin of the chest at 1st and 2nd intercostal space*

- **Cervical structures**

(*Posterior/Deep* muscles of the neck)
– often directly in relation to the spine.
(Semispinalis capitis and Cervicis muscles)

studyaid

Subclavian artery branches - Third part

Dorsal scapular artery

- Joins the **scapular arterial complex**

- **Muscles:**
  - Levator scapulae muscle
  - Rhomboid muscles (minor and major)
  - Trapezius muscle

Summary - does it make sense though? - YES!

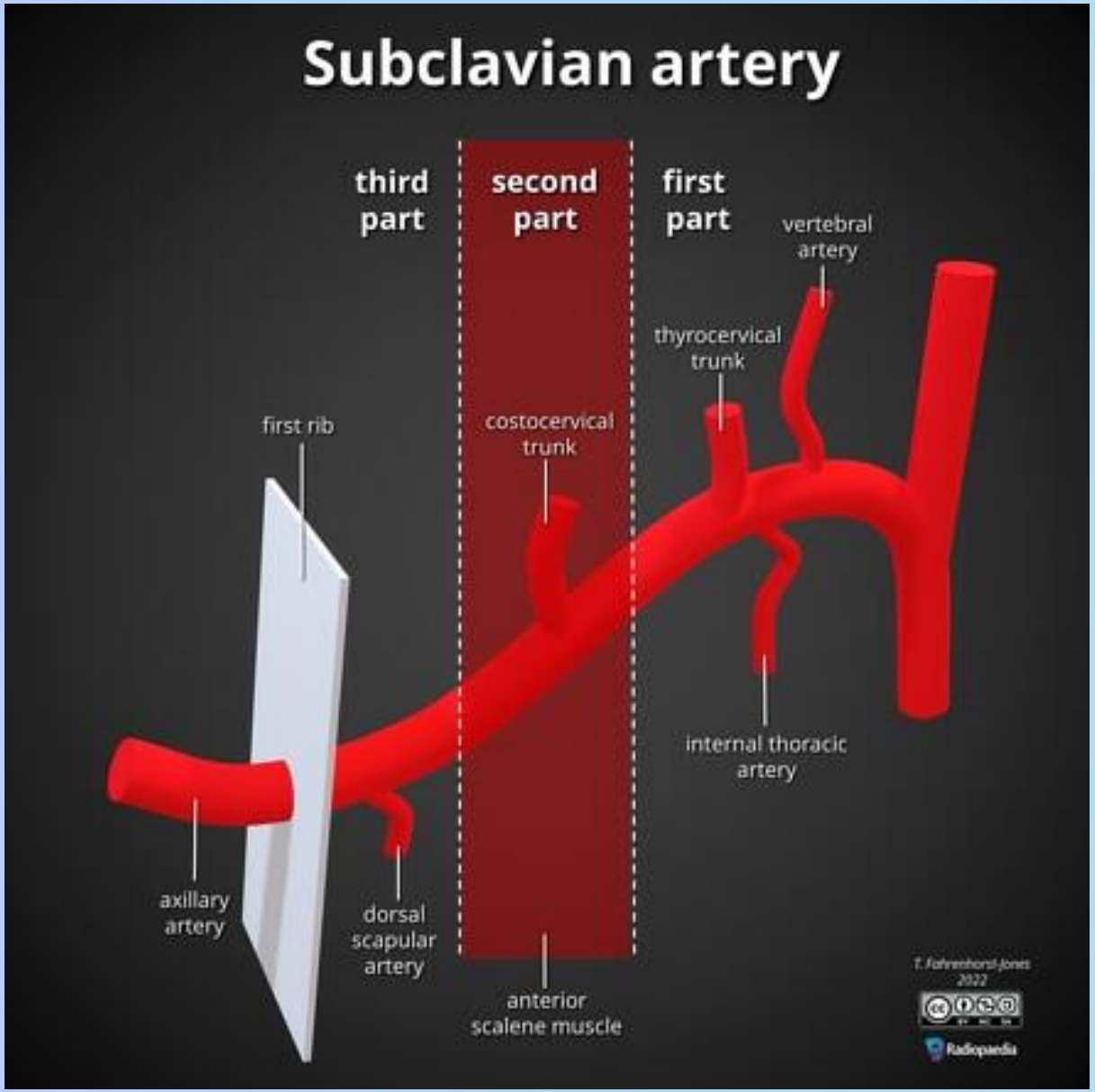

- Thyrocervical trunk
  = ANTERIOR neck muscles
- Costocervical trunk
  = POSTERIOR neck muscles
- **Pericardiophrenic artery branches off the internal thoracic artery while supplying the pericardium and anterior part of diaphragm.**
- Proximal part (1st segment) derives from the 4th pharyngeal arch embryologically.

studyaid

Axillary arteries

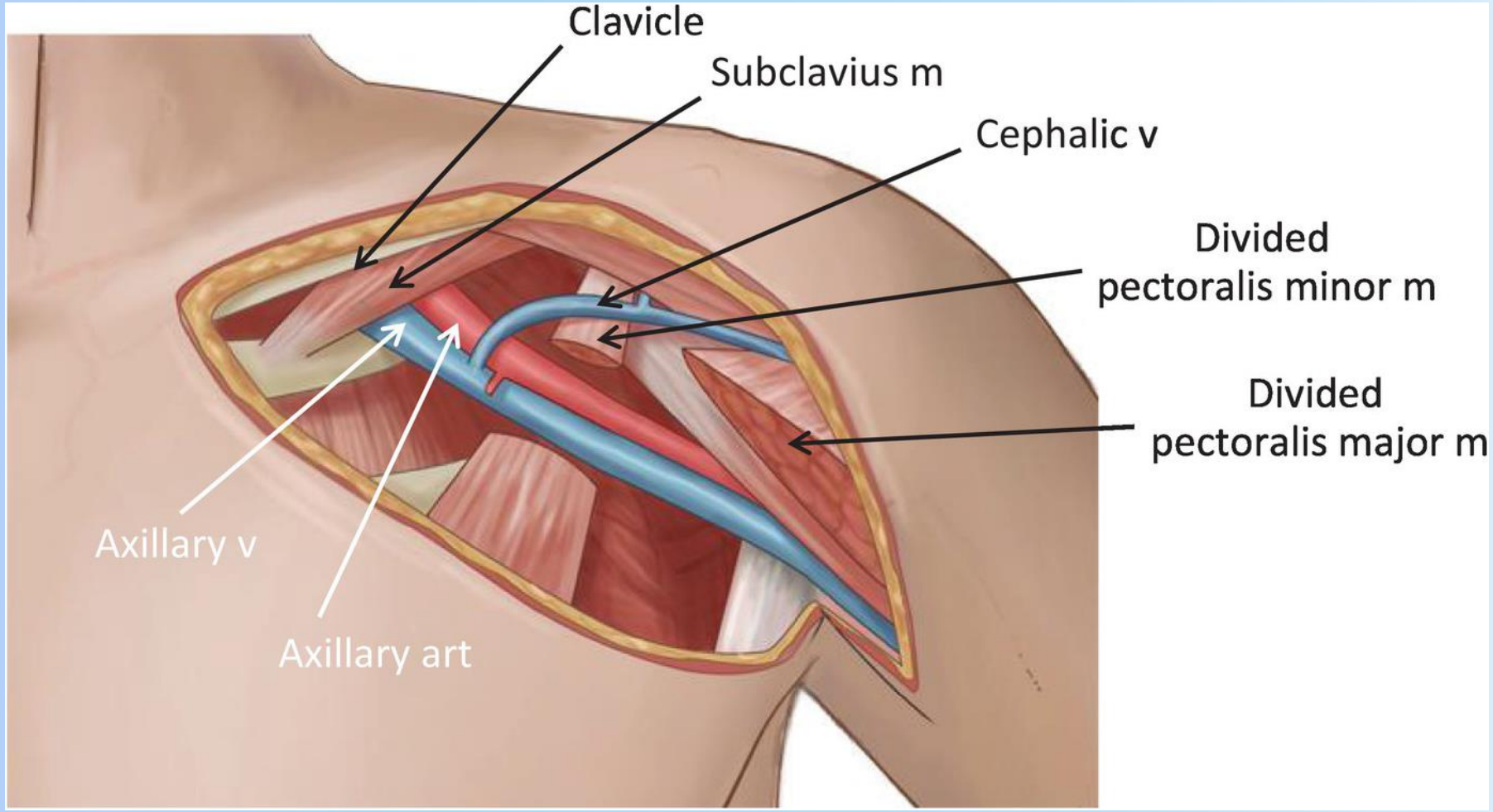

studyaid

Axillary arteries segment and borders

3 segments:

- 1st segment = 1 branch
- 2nd segment = 2 branches
- 3rd segment = 3 branches

3 Borders, 3 landmarks:

- 1st segment = 1st rib to Pectoralis minor
- 2nd segment = Behind Pectoralis minor
- 3rd segment = Pectoralis minor to Teres major muscle

studyaid

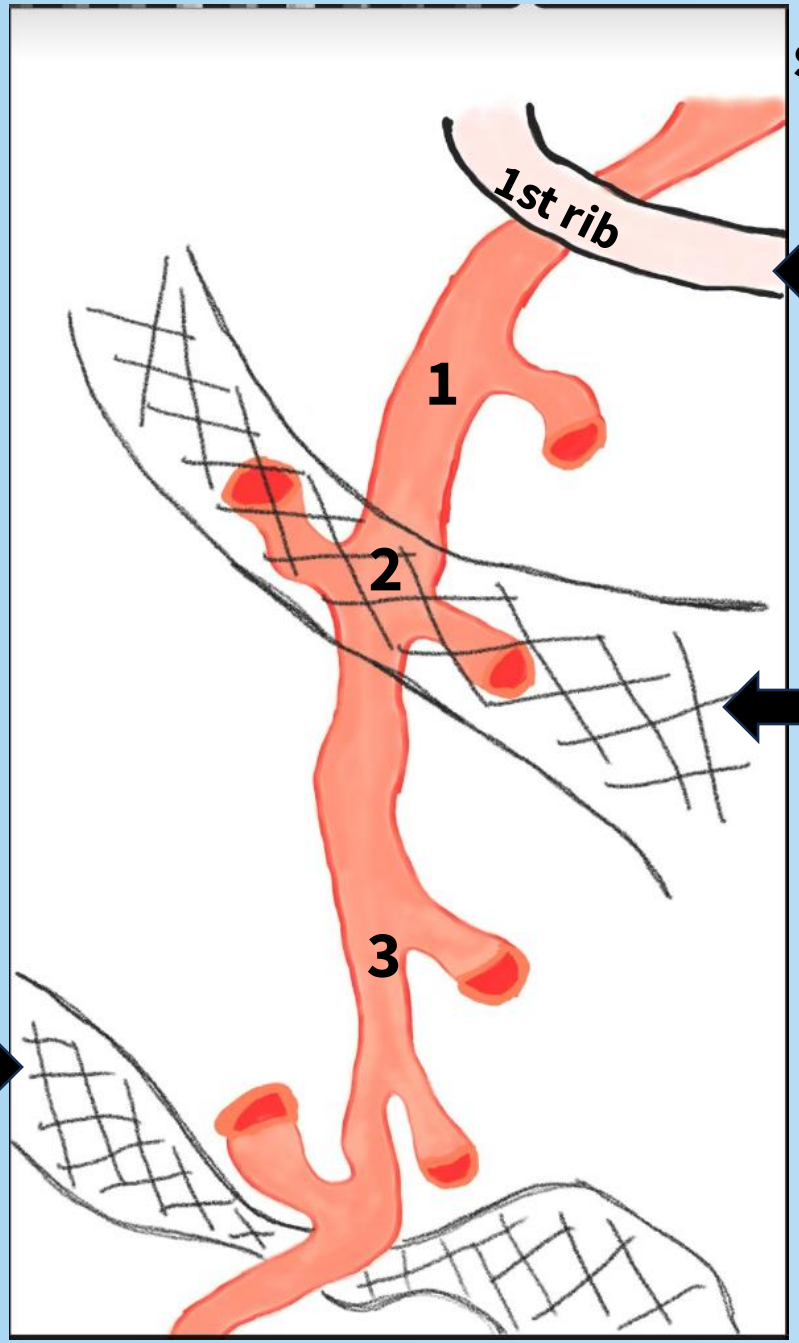

Subclavian artery

1

2

Pectoralis minor muscle

3

Teres major muscle

Name change!

studyaid

Branches of axillary artery

1st segment:

1. Superior thoracic artery
(Pectoralis major and minor, subclavius muscle, 1st and 2nd intercostal muscles + skin)

2nd segment:

1. *Thoracoacromial artery*
(Pectoralis major and minor, deltoid, acromion + clavicle)

2. Lateral thoracic artery
Axillary lymph nodes, serratus anterior, pectoralis muscles.

3rd segment:

1. Subscapular artery
(Thoracodorsal artery + **Circumflex Scapular Artery**)

2. Anterior humeral circumflex artery

3. Posterior humeral circumflex artery

studyaid

Does it make sense though?

studyaid



1st segment:

1. Superior thoracic artery
   (Pectoralis major and minor, subclavius muscle, 1st and 2nd intercostal muscles + skin)

studyaid

2nd segment:

1. *Thoracoacromial artery*
(Pectoralis major and minor + deltoid)

2. Lateral thoracic artery
Axillary lymph nodes, serratus anterior, pectoralis muscles and subscapularis

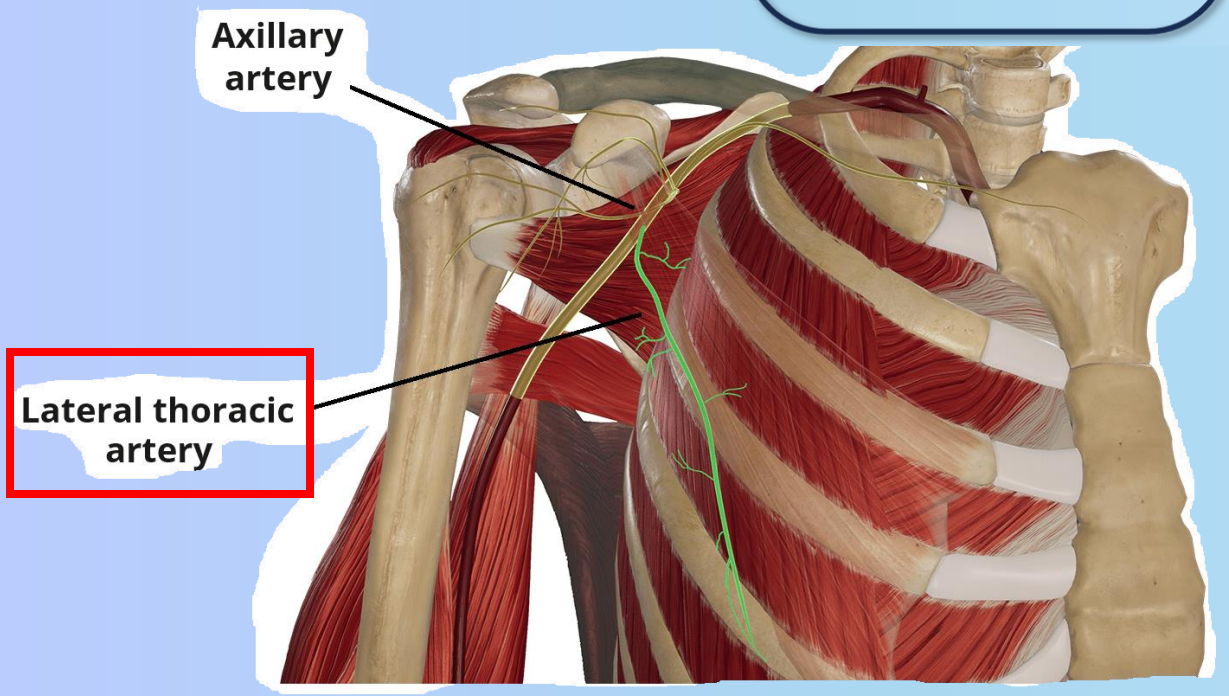

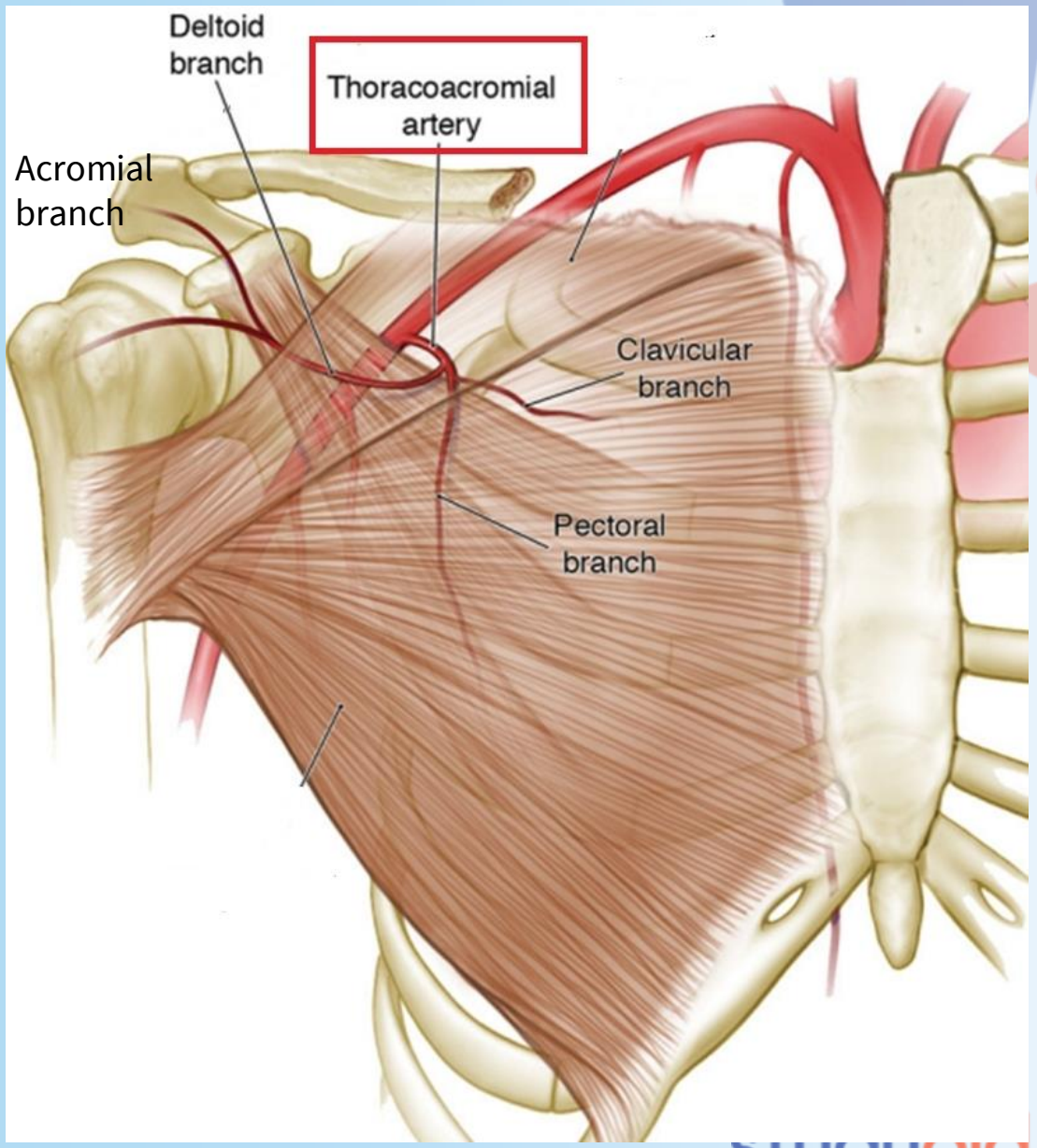

<u>Surgical neck of humerus.</u>
Clinically important!

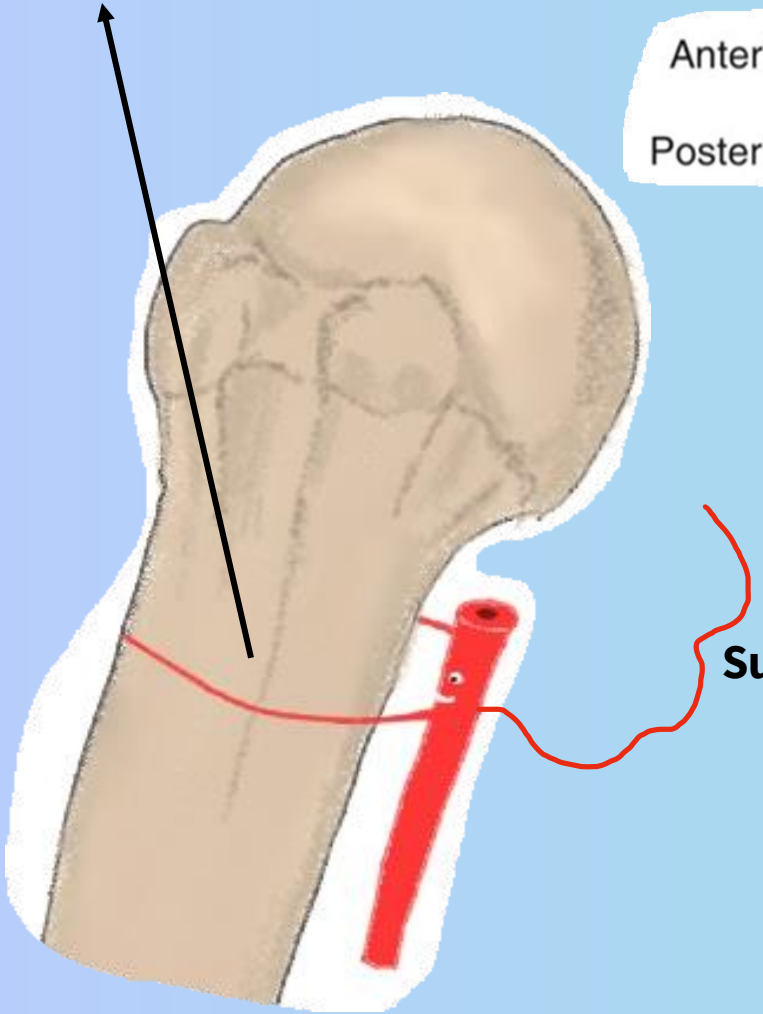

Subscapular artery

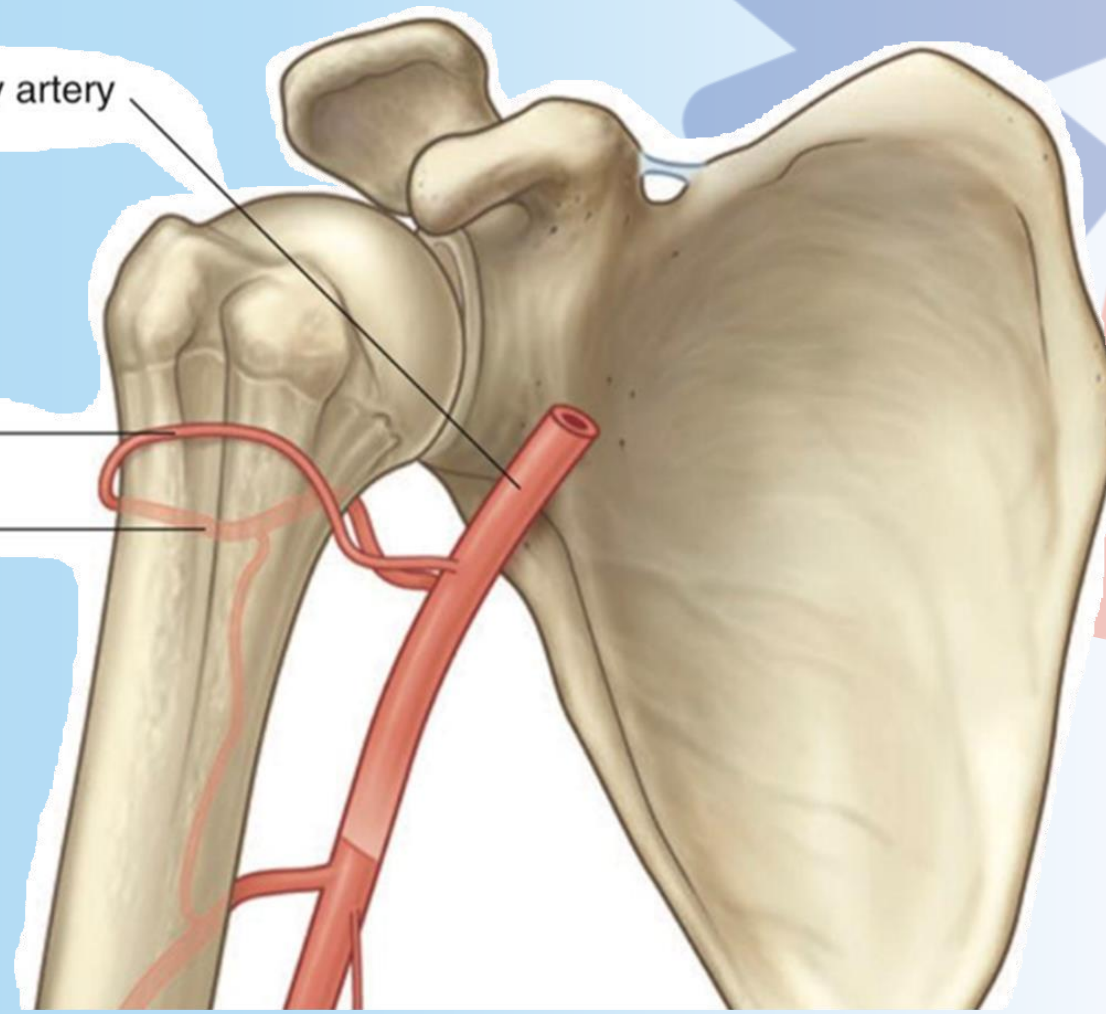

Did you collect us?

studyaid

Arterial supply of scapula

(Scapular collateral circulation)

Suprascapular artery

Branch of thyrocercival trunk

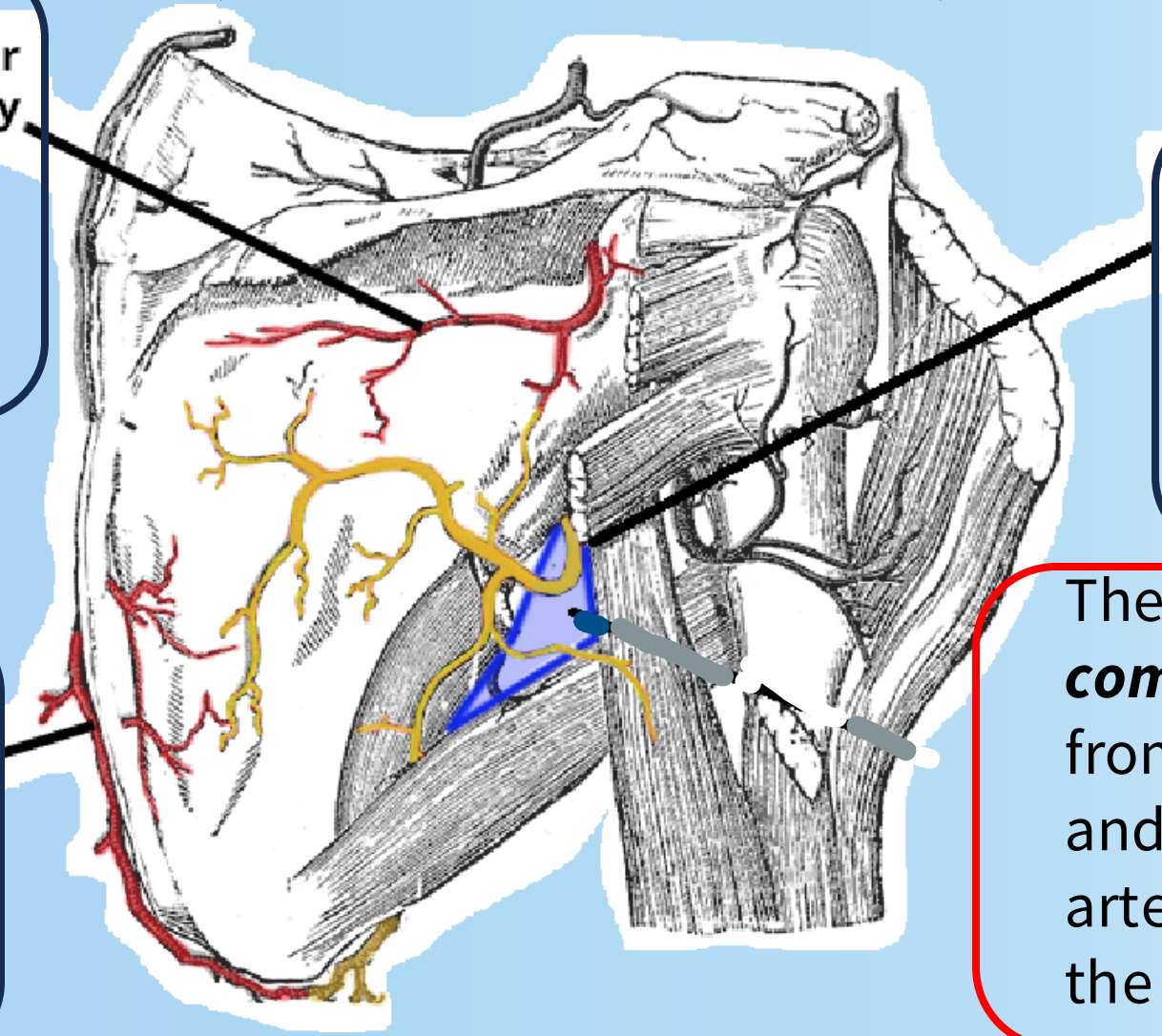

Circumflex scapular artery

Branches off from the **subscapular artery** (3rd segment of axillary artery)

Dorsal scapular artery

3rd segment of subclavian artery

The ***scapular arterial complex*** consists of arteries from *both* subclavian artery and axillary artery. These arteries will anastomose at the dorsal scapular

studyaid

Scapular collateral circulation

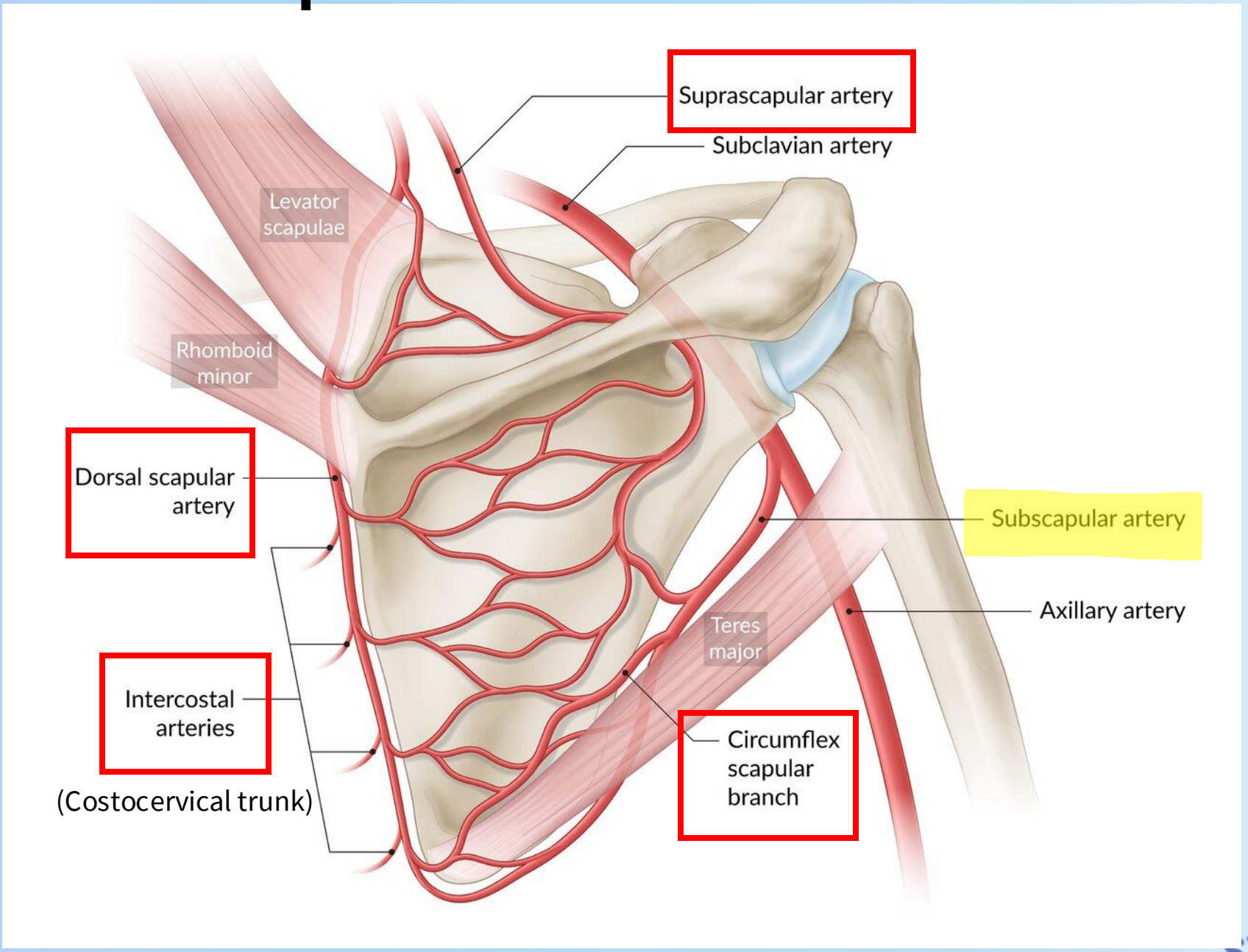



Brachial artery

My red blood cells when the brachial artery is ruptured or blocked.



studyaid

Brachial artery

- No actual borders!
- **Starts:**
  Where the Teres major muscle crosses.
- **Ends:**
  Bifurcation in cubital fossa.
- **Coursing:**
  In the groove between the biceps and triceps muscles (quite superficial).

  It courses together with ulnar and median nerves.
- In the cubital fossa, it will be accompanied by the ***basilic vein***.

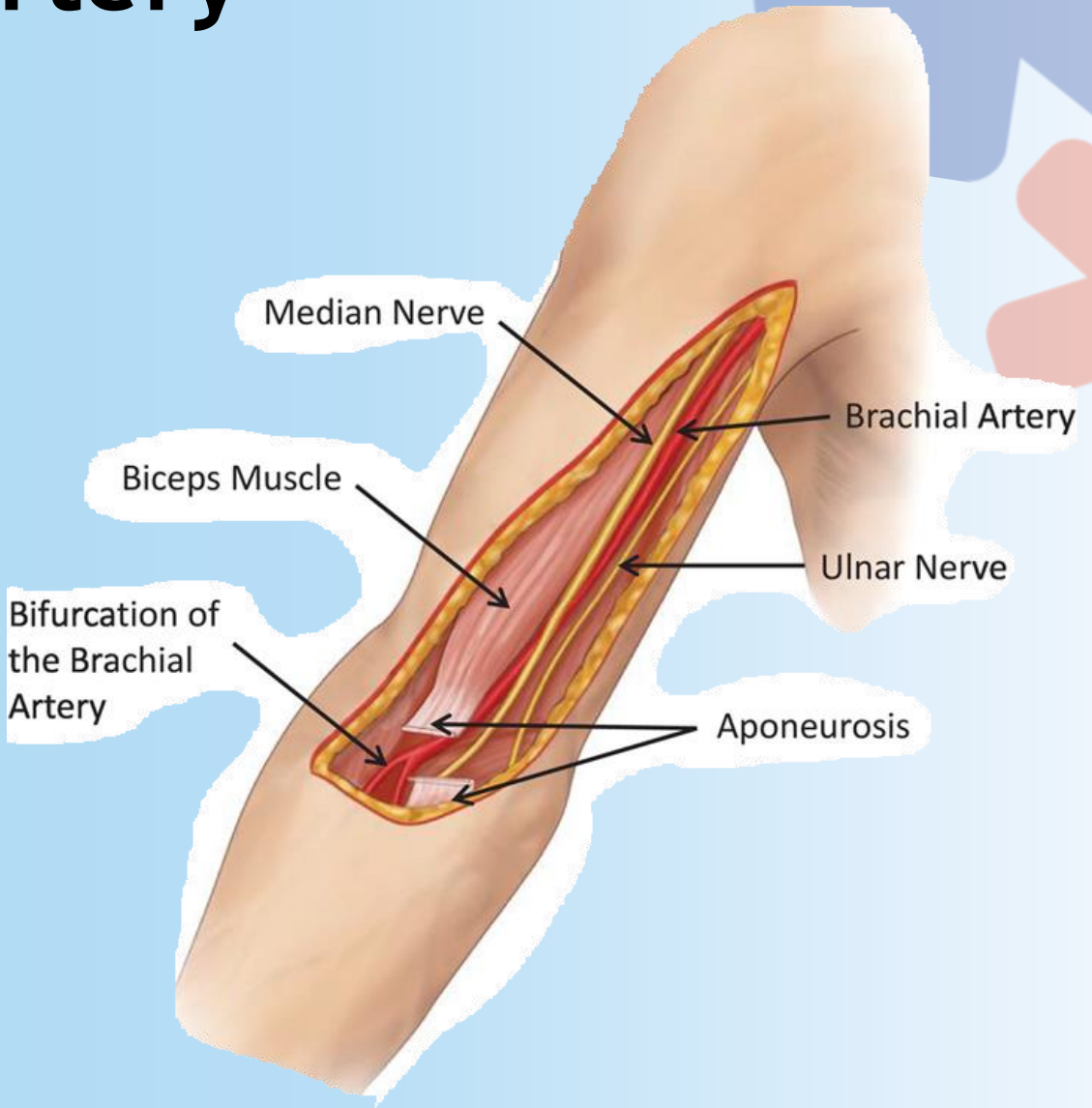

studyaid

Branches of brachial artery

«the reinforcement branches»



4 branches:

1. **Profunda Brachii artery (Deep brachial artery)**
   *- Ascending branch – **Posterior humeral circumflex artery***

   *- Bifurcates into **Middle** and **radial collateral** arteries (elbow joint anastomoses arterial plexus)*

2. **Superior Ulnar Collateral artery**
   (elbow joint arterial anastomoses plexus)

3. **Inferior Ulnar Collateral artery**
   (elbow joint arterial anastomoses plexus)

4. **Humeral nutrient artery**
   (Enters the nutrient canal around the middle of the humerus, anteromedial surface).



studyaid

What happens if there is an occlusion or trauma here?

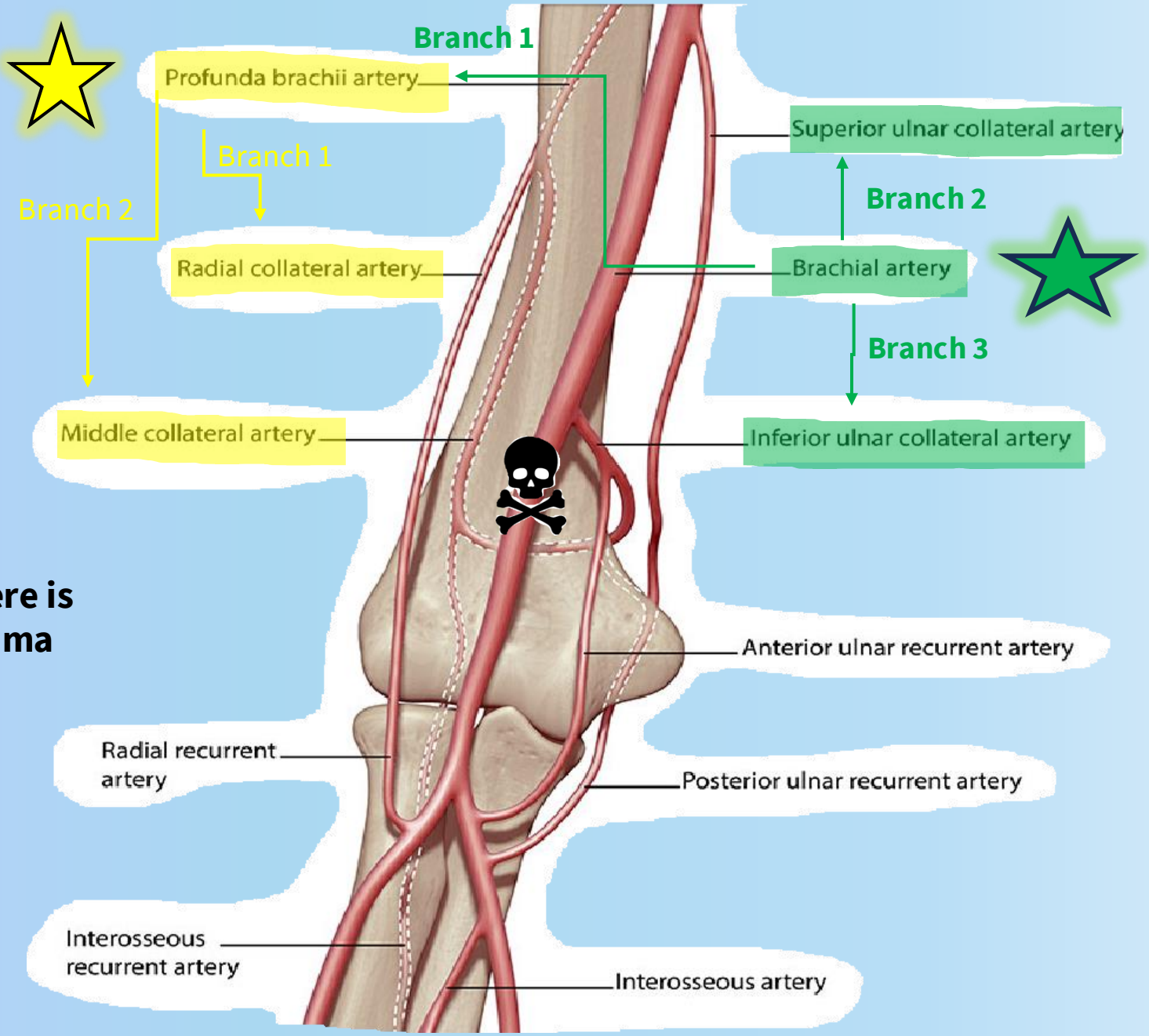

Rules:

1. Collateral = Recurrent

2. Same «side» (radial + radial) f.ex.

Name change at the medial epicondyle!

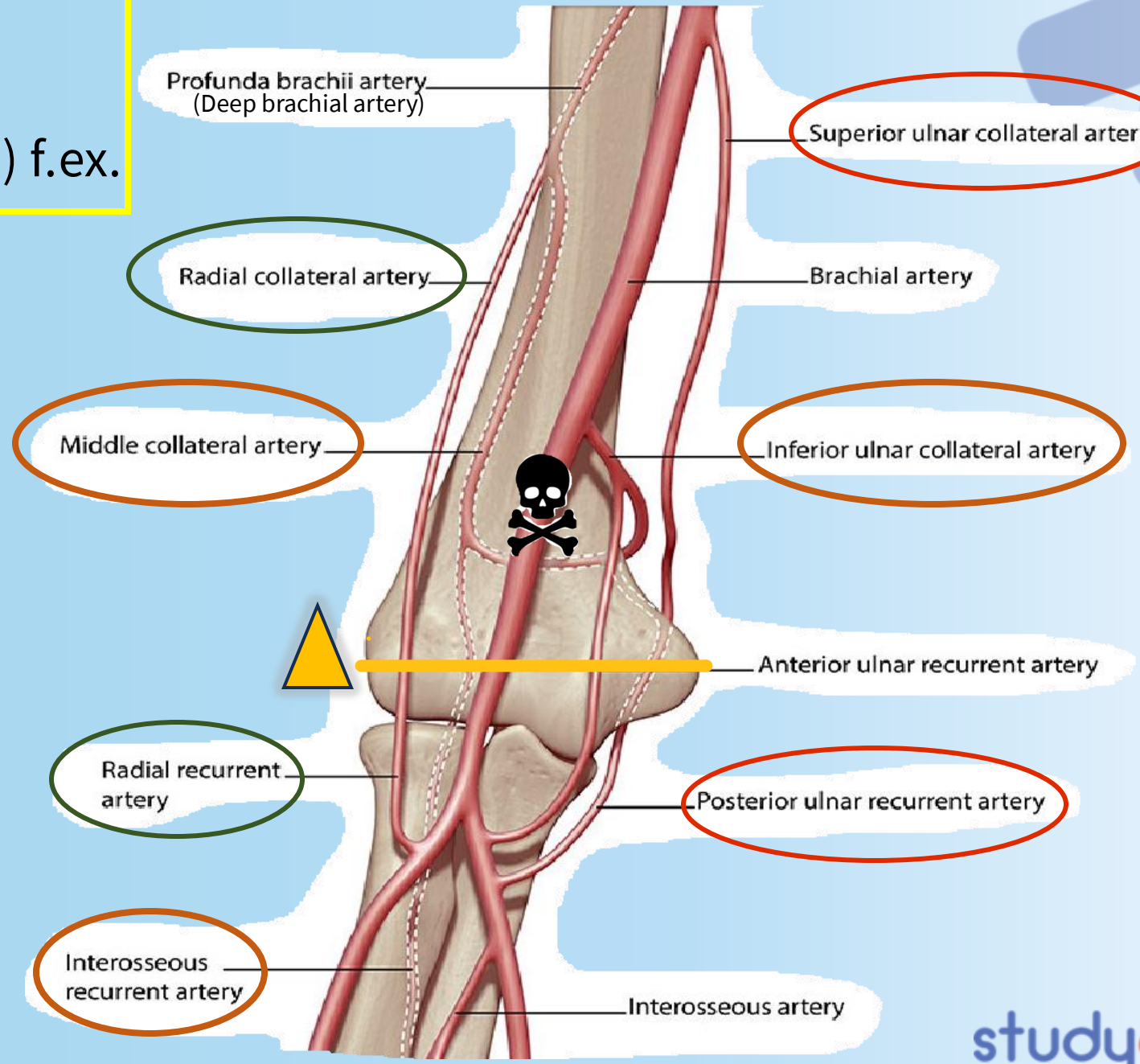

studyaid

Radial and ulnar arteries



studyaid

Endgoal: 4 Arches in wrist and hand

1. Superficial *palmar* arch
2. Deep *palmar* arch
3. *Palmar* carpal arch
4. *Dorsal carpal arch (or Dorsal carpal Rete)*

studyaid

Arch 1 and 2:

Deep palmar arch

Superficial palmar arch

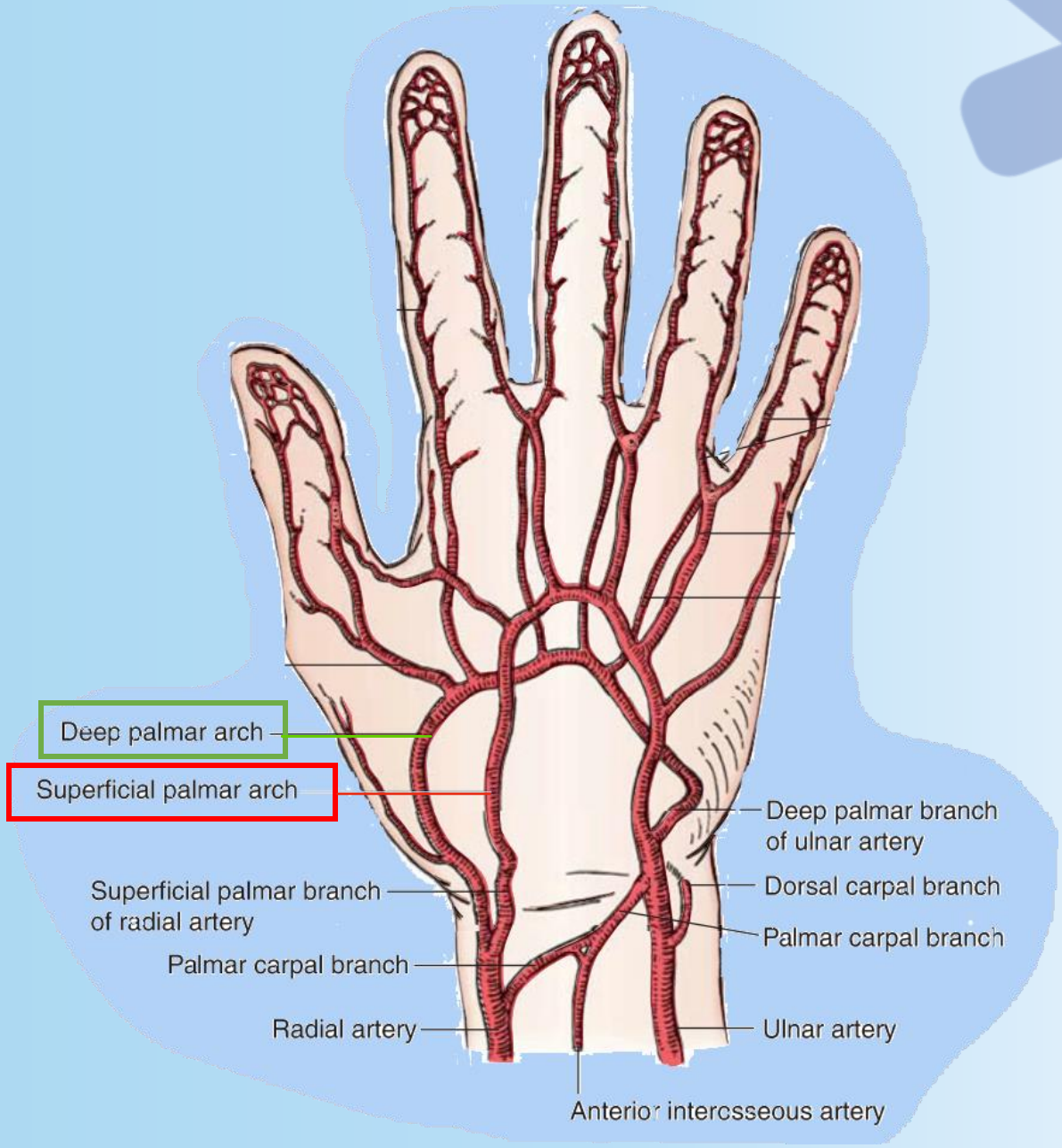

Anterior view
(flexor side)

studyaid

Arch 3 and 4:

Palmar carpal arch

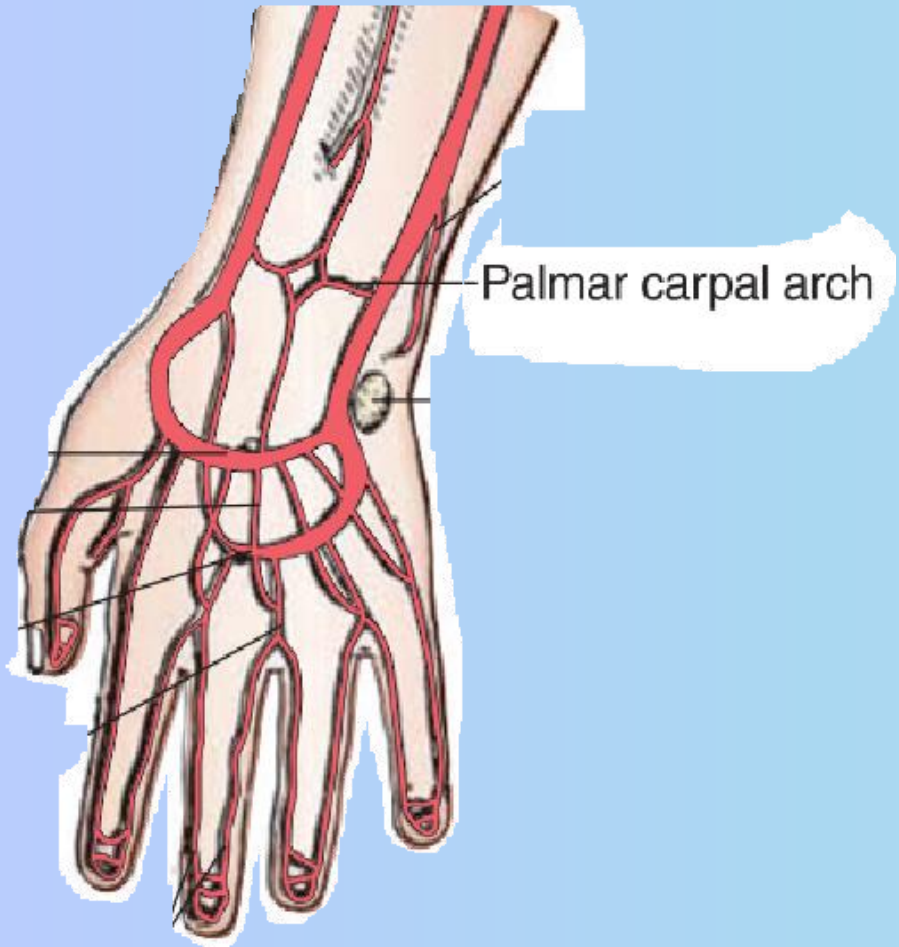

Anterior view
(flexor side)

Dorsal carpal arch
(or Dorsal carpal Rete)

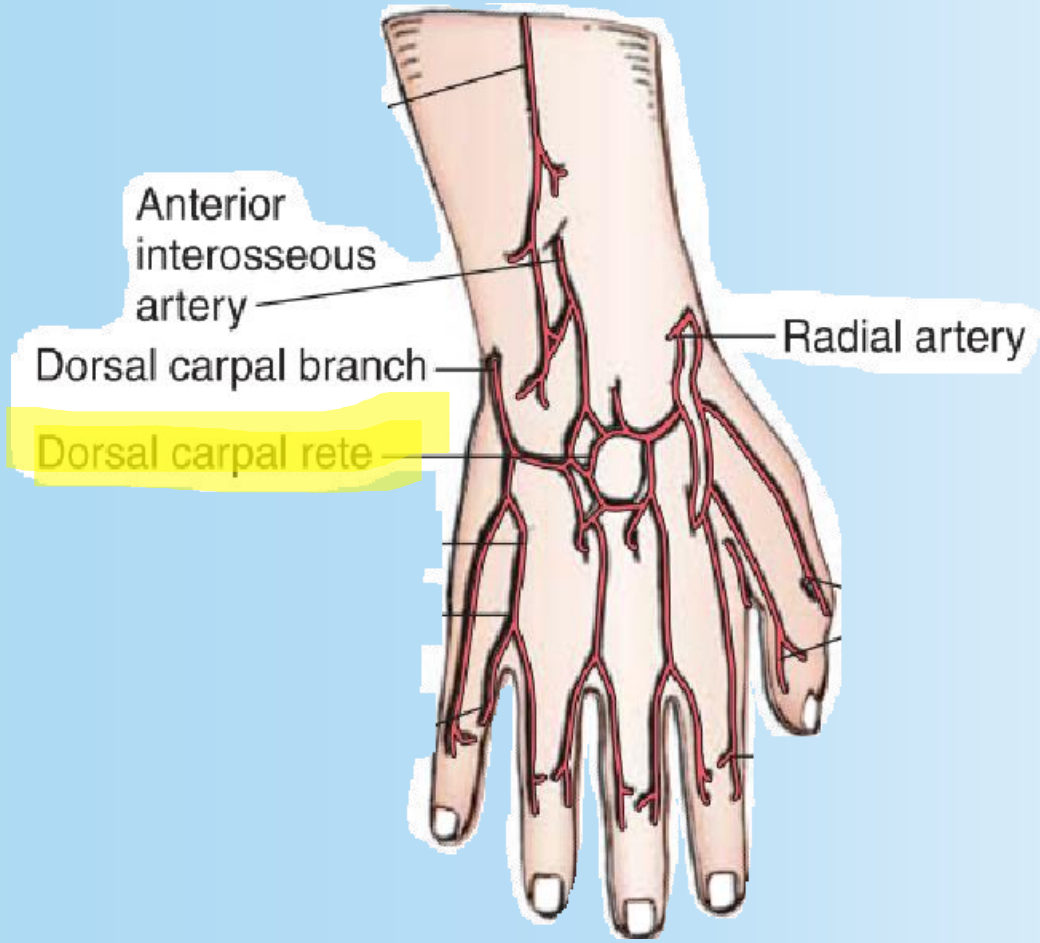

Posterior view
(extensor side/dorsal)

studyaid

Ulnar artery and its branches

- Provides branches to supply the forearm, flexors and extensors + **the elbow**

- **Courses on top of flexor retinaculum, into *Guyon canal* when entering the hand.**

Branches:

1. Common interosseous artery

- **Posterior interosseous artery**, which gives off a branch called the Interosseous recurrent artery).

- ***Anterior interosseous artery*** *that will merge with the Palmar carpal arch* in the wrist.

2. Branch for the Palmar Carpal Arch

3. Branch for deep palmar artery

Ulnar artery (main artery) terminates in the *superficial palmar arch* and gives off a branch to the deep palmar arch!

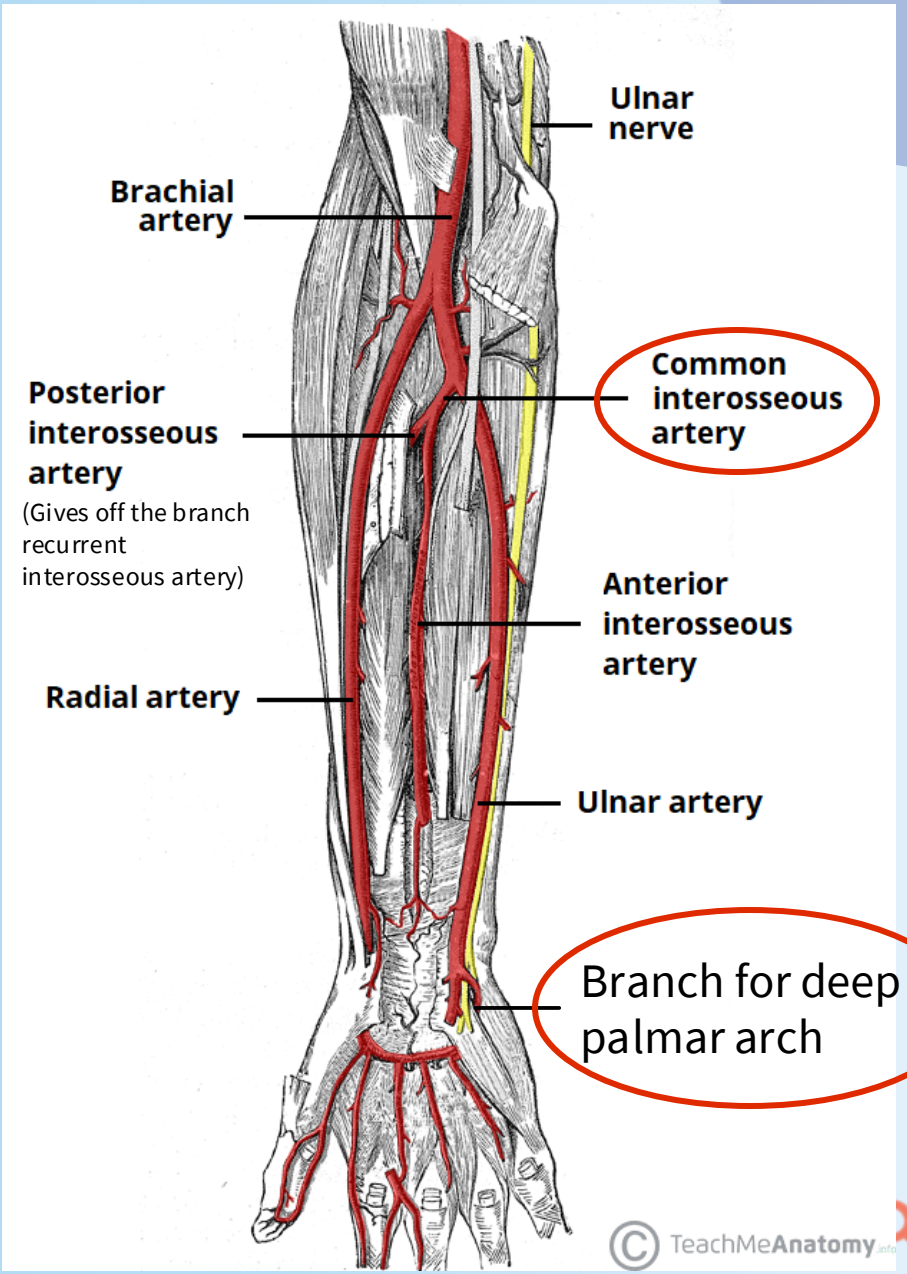

Radial artery

- Radial artery courses just behind brachioradialis muscle, then superficially towards the wrist.
- Radial artery provides with some small muscular branches before it bifurcates at the wrist - ***blood supply to extensor muscles***.
- «Radial muscles» = Radial recurrent artery and radial artery.
- *Splits at the wrist where it provides a* ***Superficial branch of radial artery***.
- Superficial radial branch creates the ***superficial palmar arch***.
- The radial artery courses around the thumb (through the *anatomical snuffbox*) to leave off a branch for the dorsal arterial plexus ***(dorsal carpal rete)***.
- The radial artery then goes back into the palm to create the deep palmar arch.

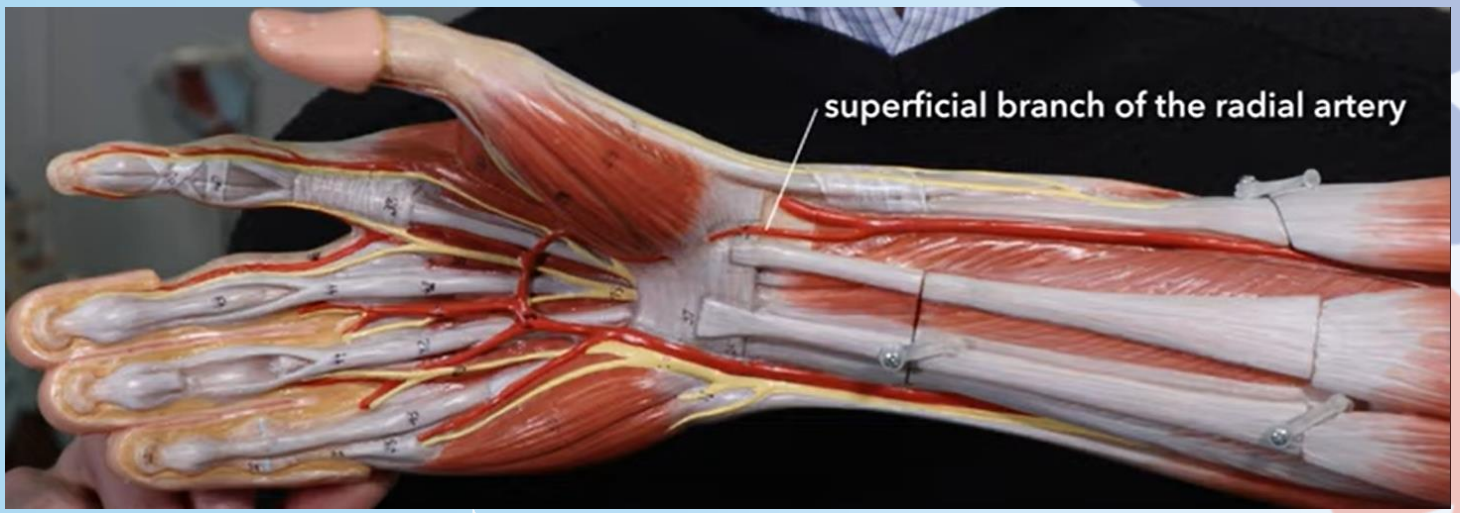

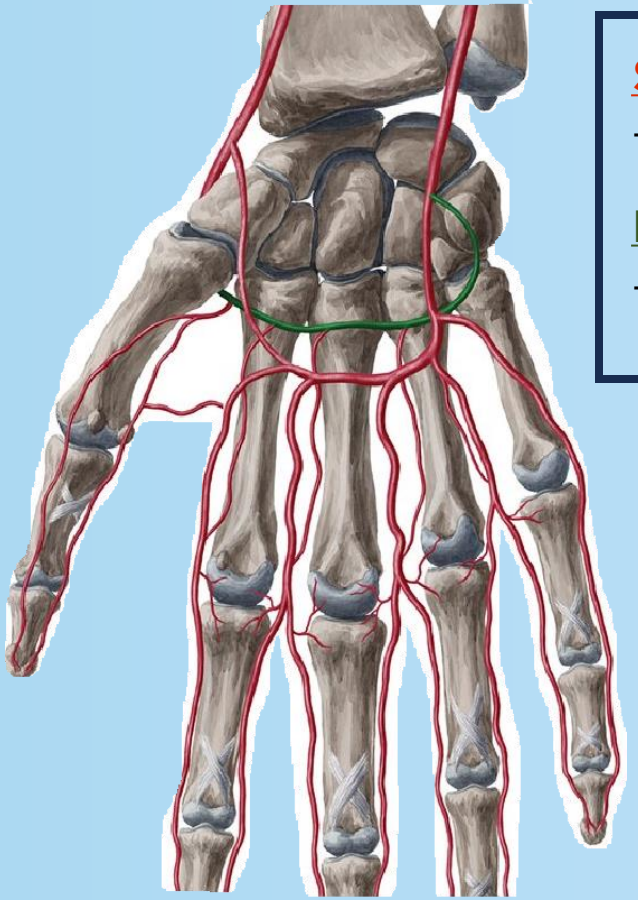

Superficial palmar arch:
- Superficial branch of radial artery

Deep palmar arch:
- Radial artery (main)

Superficial palmar arch:
- Digits, skin, lumbricals

Deep palmar arch:
-Bones, joints and interossei muscles **(only to metacarpals)**

studyaid

Rules:

SUPERFICIAL radial artery branch

SUPERFICIAL palmar arch

DEEP ulnar artery branch

DEEP palmar arch

Main radial artery goes to the **deep** palmar arch to meet **deep** ulnar branch

Main ulnar artery goes to superficial palmar arch to meet superficial radial branch.

studyaid

Venous drainage of the limb



Venous drainage of upper limb

- **There are two types of veins:**

  1. Deep veins
  2. Superficial veins

- The deep veins have the same name as the arteries, and they usually course with the arteries.

- The deep veins are PAIRED (2 with the same name).

Why do we have a pair of veins, but only one artery?

Hint:

Arterial pressure vs venous pressure.

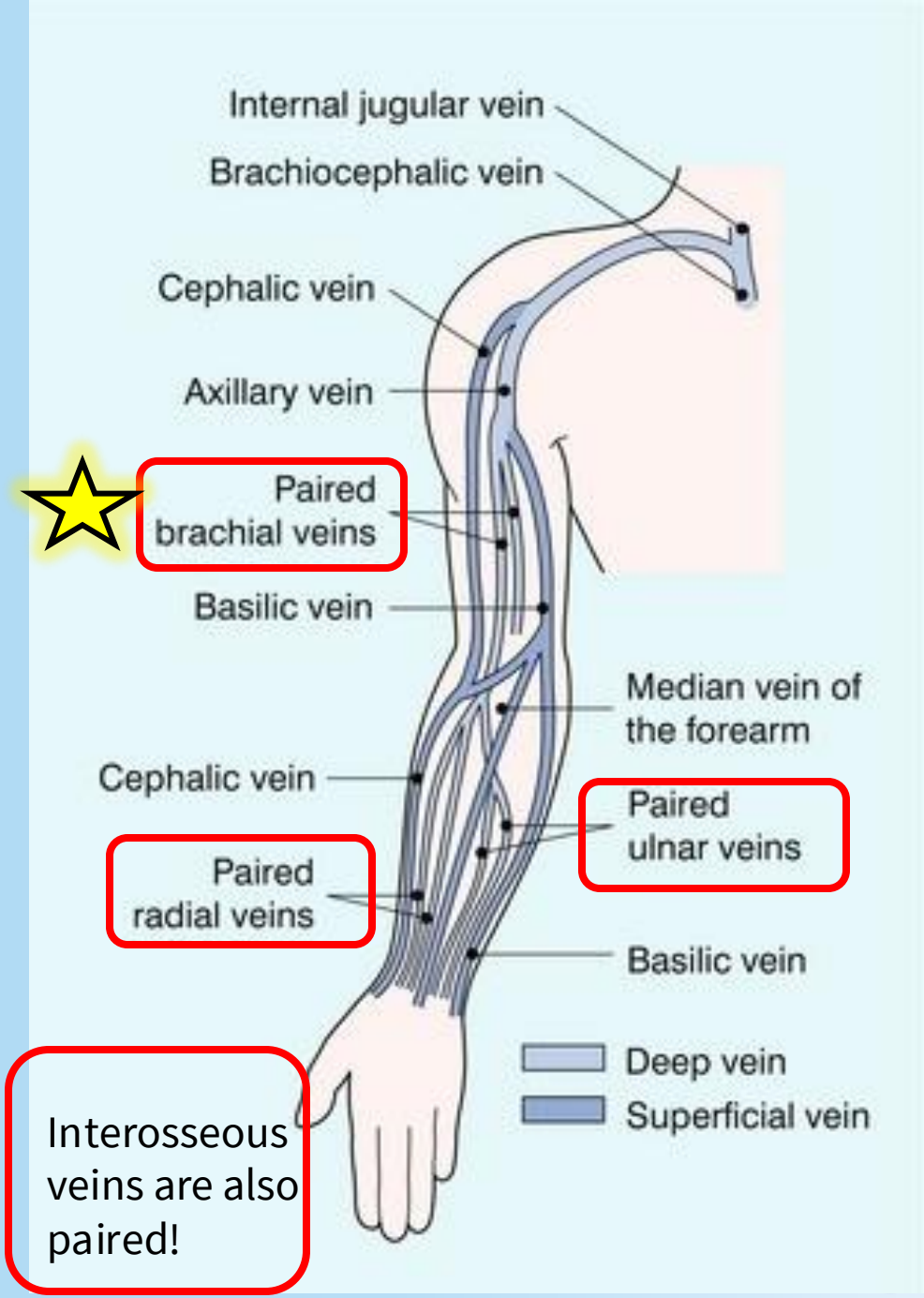

Superficial veins

4 main veins + arches and plexuses:

1. **Cephalic vein** (lateral side **(thumb)** – on top of or lateral to biceps brachii)
2. **Basilic vein** (medial side **(little finger)** – courses over the medial epicondyle and shortly, in the groove *between* the biceps and triceps brachii muscles before it merges with the axillary vein)
3. **Median vein of the forearm** (drains into the basilic vein or the median cubital vein)
4. **Median cubital vein** (connects Cephalic and Basilic vein in cubital fossa)
5. 1. Dorsal venous network (on top of hand)
   2. Palmar carpal venous arch
   3-4.Superficial and deep palmar venous arches

Some superficial veins are usually not named, so they get unified names:

- Perforating veins.
- Plexuses.

- Superficial veins will eventually drain into deep veins – same as lymph nodes

Coursing of the Cephalic and Basilic veins

Cephalic vein:

- Branches out from the *dorsal venous network* of the hand, **and crosses the anatomical snuffbox** to enter the wrist.
- Drains the lateral side (radial side) from the hand to the shoulder.
- The cephalic vein will then course up «on top of» the bicipital groove
- It drains into the *Axillary vein* **at the clavicle**

Basilic vein:

- Branches out from the *dorsal venous network* of the hand.
- Drains the medial side (ulnar side) from the hand to the shoulder
- It will course superficially, but then penetrate the *brachial fascia*, merge with the paired brachial veins and it will form an **extension of the axillary vein BEFORE the Teres Major muscle.**

Remember the **limb bud** from embryology to separate these two!

studyaid

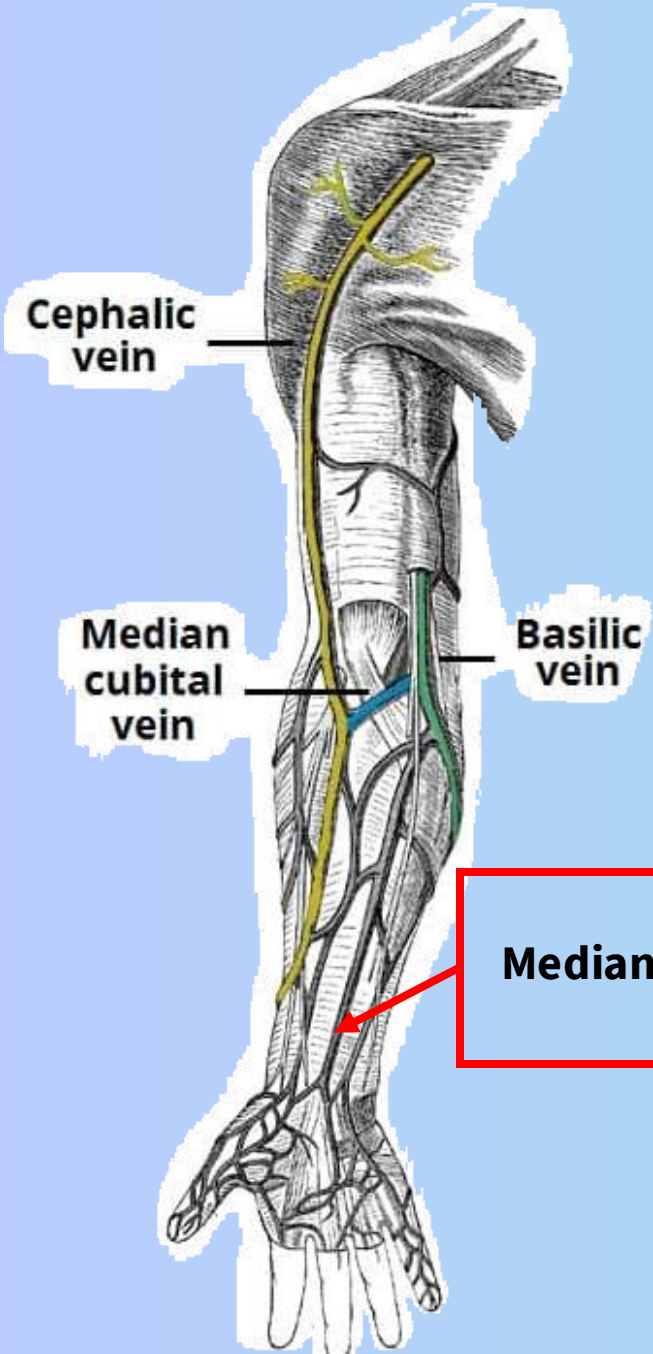

Median vein of the forearm

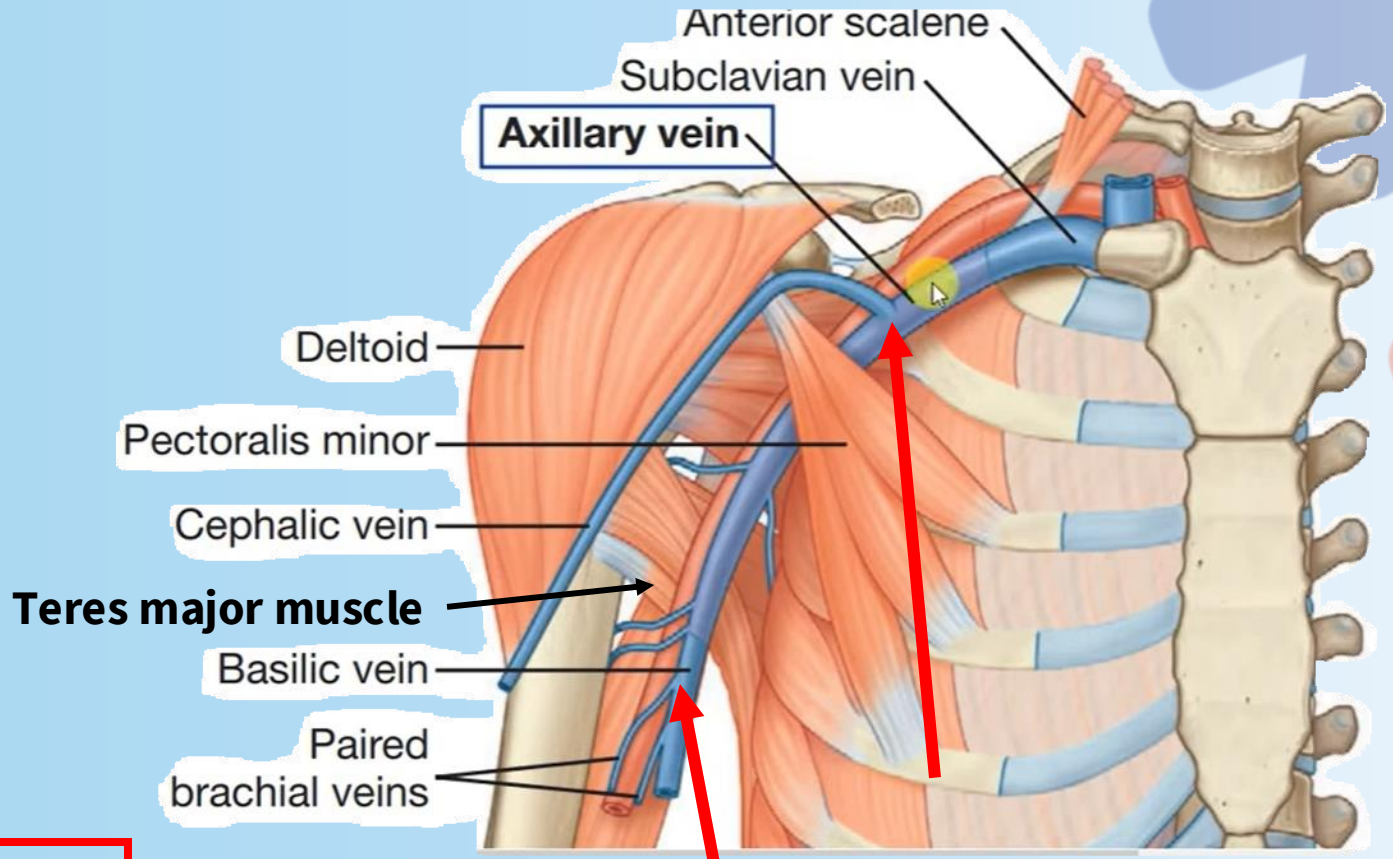

Paired brachial veins forms an extension of the axillary vein together with the basilic vein – which then merges with the original axillary vein (before Teres major muscle)

studyaid

Venous system of upper limb - finish

- Axillary vein becomes subclavian vein (first rib).
- Subclavian vein merges with *internal jugular vein* to become the *brachiocephalic vein*
- The two brachiocephalic veins (right and left) merge to form the superior vena cava, which drains into the heart's right atrium.

The right and left side are **SYMMETRICAL** when it comes to the veins

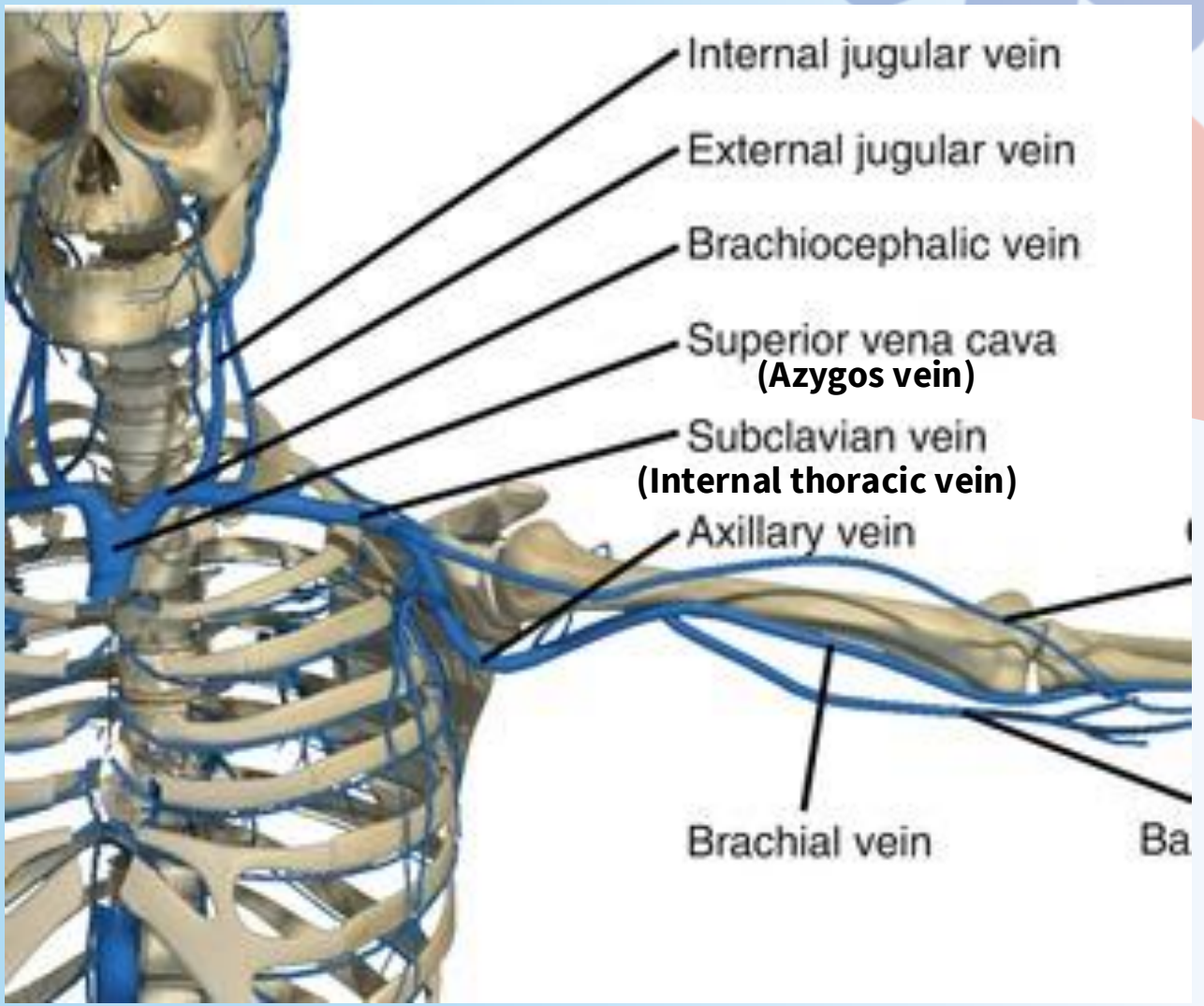

studyaid

Lymphatic system



Venous angle

Venous angle on both sides are formed by the merging of:

- Subclavian vein

- Internal jugular veins

Thoracic duct collects lymph from lower limb and abdomen.

Right lymphatic duct collects lymph from right side of head and neck and thorax.

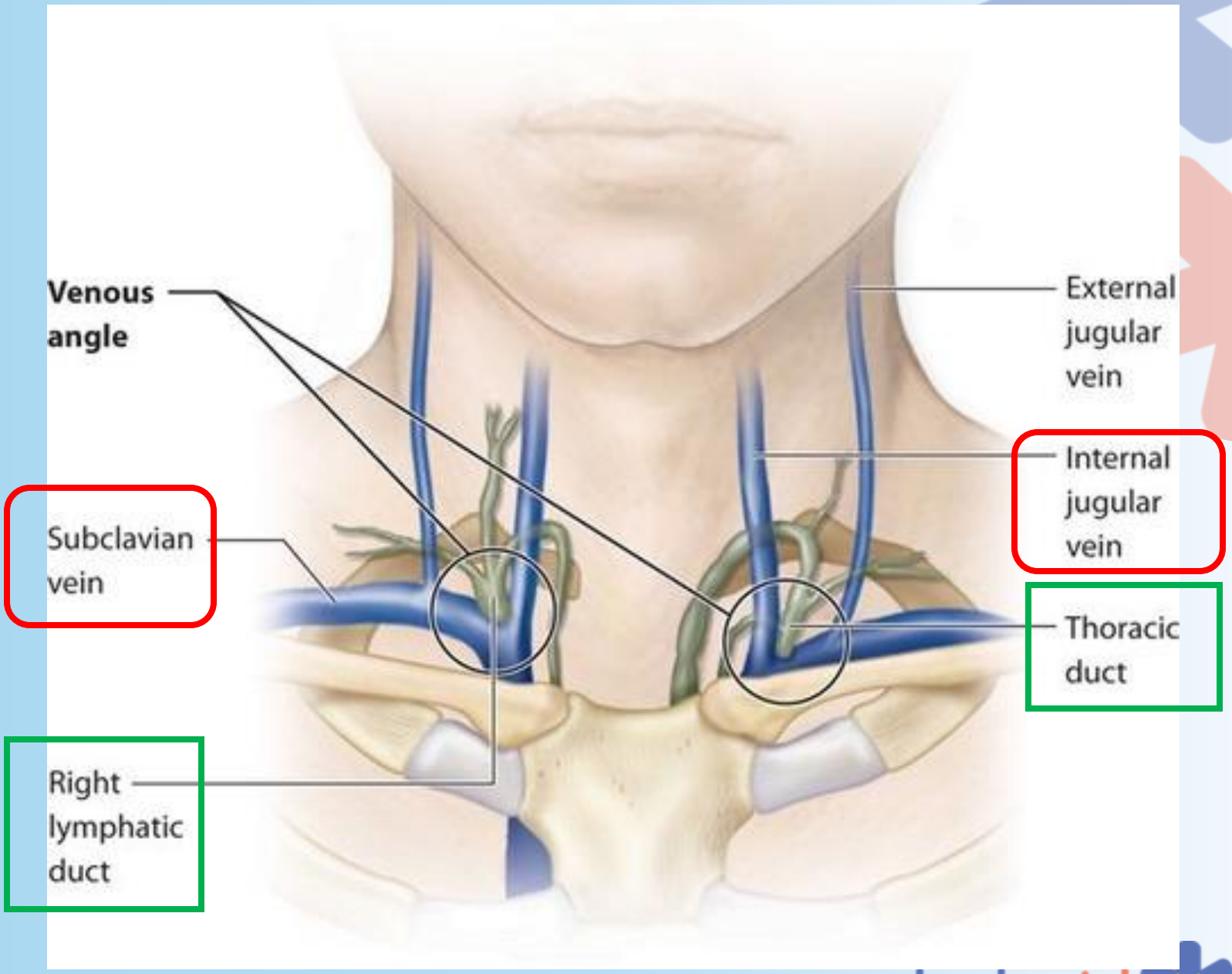

studyaid

Lymphatic system of upper limb

Generally about lymph nodes:

- Lymph nodes usually follow the veins
- Lymph nodes group up together in joints
- They drain the excess fluid in tissue
- They drain from one group to another group (like checkpoints), and often from a superficial group to a deep group.
- Are always clinically relevant in terms of cancer metastasis and when the lymphatic system is not working properly.

studyaid

Rule:

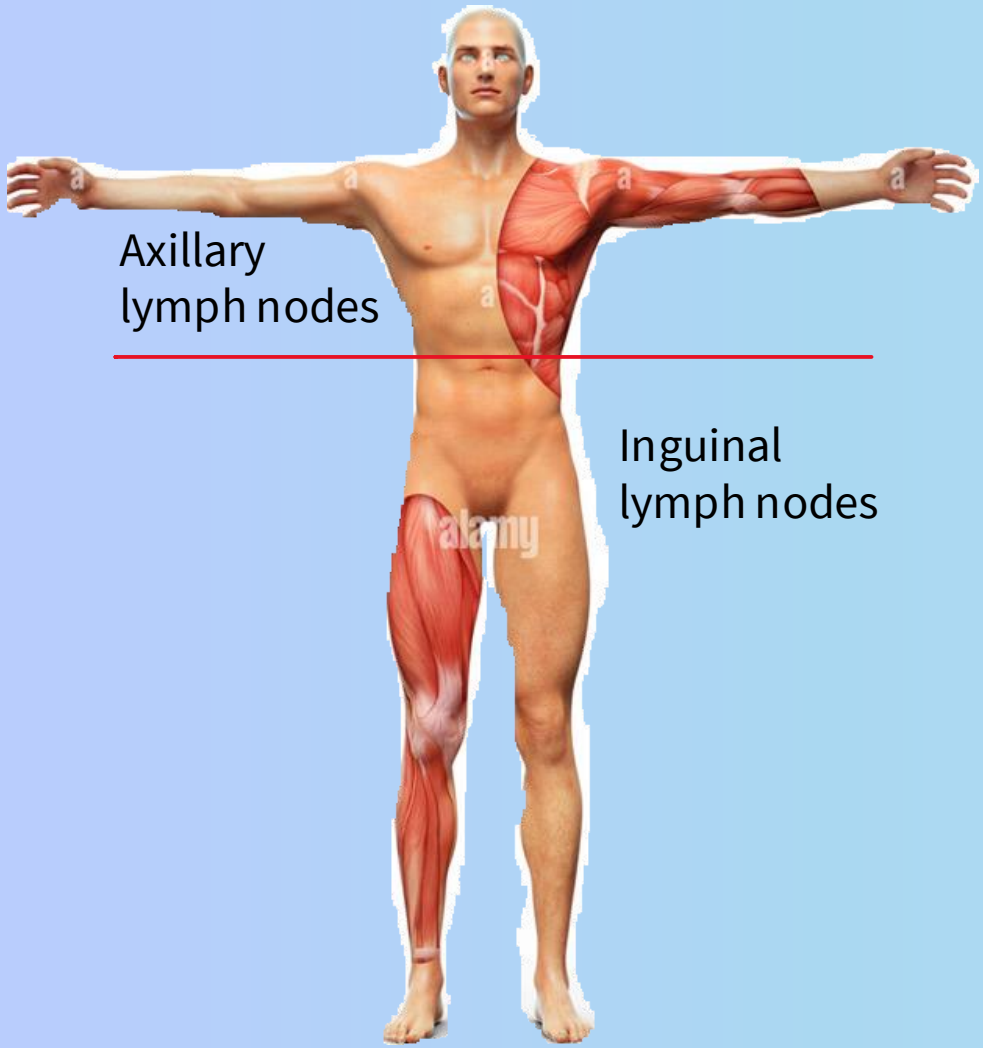

- **<u>Skin above umbilicus (bellybutton):</u>**

Drains into axillary lymph nodes

- **<u>Skin below umbilicus (bellybutton):</u>**

Drains into superficial inguinal lymph nodes (in the hip)

Cubital lymph nodes

(Epitrohchlear lymph nodes)

- Drains the skin of the forearm (superficial group of lymph nodes).
- Few (1-4), but enough to call a “group”.
- Not a very “efficient” group of lymph nodes. They get “overwhelmed” and “need help”.
- Drains into the brachial lymph nodes, and then the anterior axillary lymph nodes.

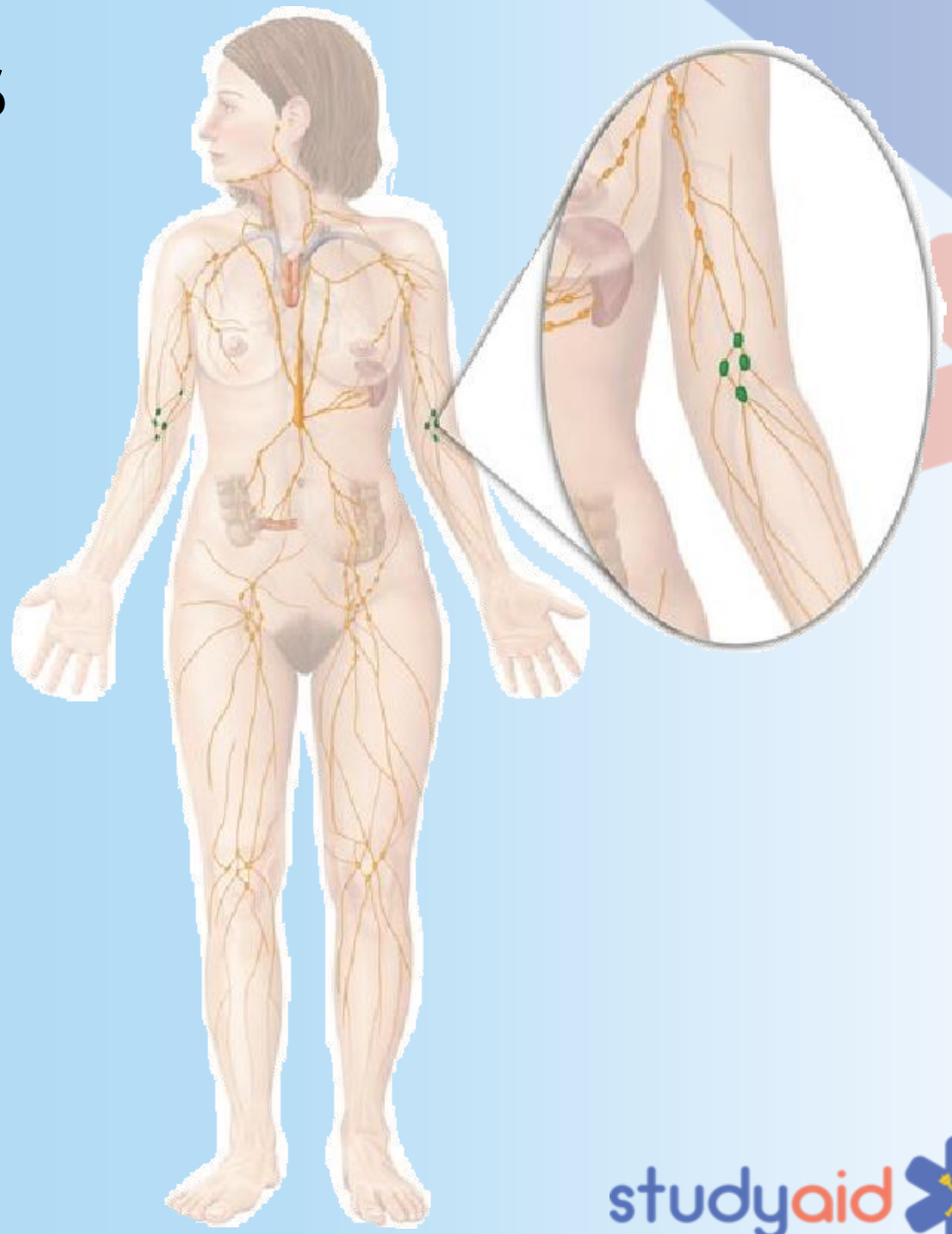

studyaid

Axillary lymph nodes

- **There are 5 groups of axillary lymph nodes**

1. **Laterally** axillary lymph nodes *(Humeral lymph nodes)*
2. **Anterior** axillary lymph nodes *(Infrapectoral minor lymph nodes)*
3. **Posterior** axillary lymph nodes *(Subscapular lymph nodes)*
4. **Central** axillary lymph nodes *(Subpectoralis minor lymph nodes)*
5. **Apical** axillary lymph nodes *(infraclavicular lymph nodes)*

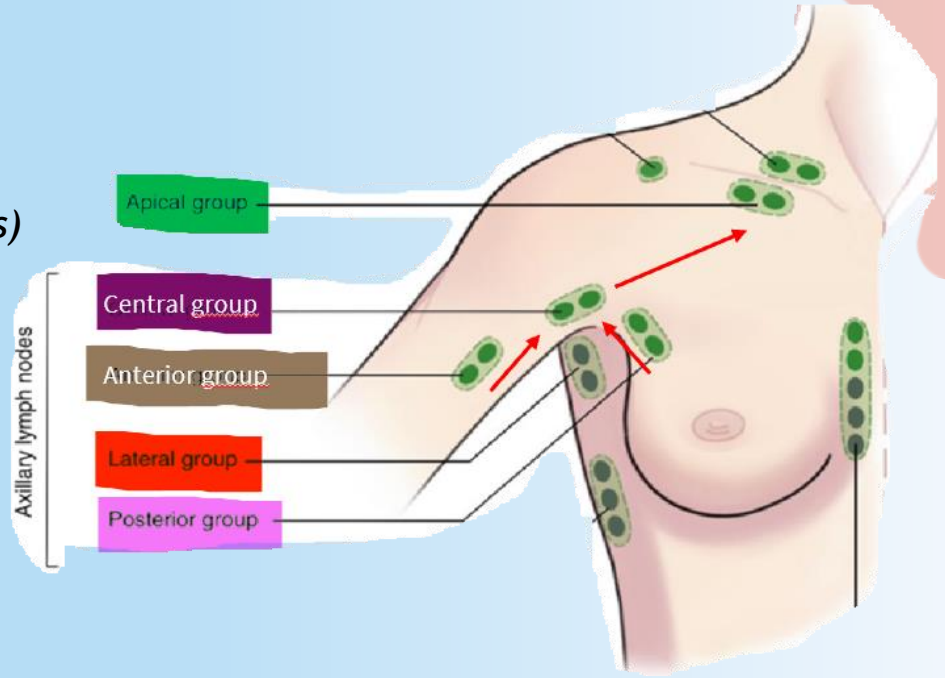

Drainage is from distal groups to proximal groups

Example:
The central group of lymph nodes will receive lymph from the anterior, lateral, and posterior groups, then drain into the apical group. The central group is more proximal than anterior, lateral and posterior (which then become distal groups).

studyaid

Lymph node drainage of hand

- **Laterally** group
- **Anterior** group
- **Central** group
- **Apical** group

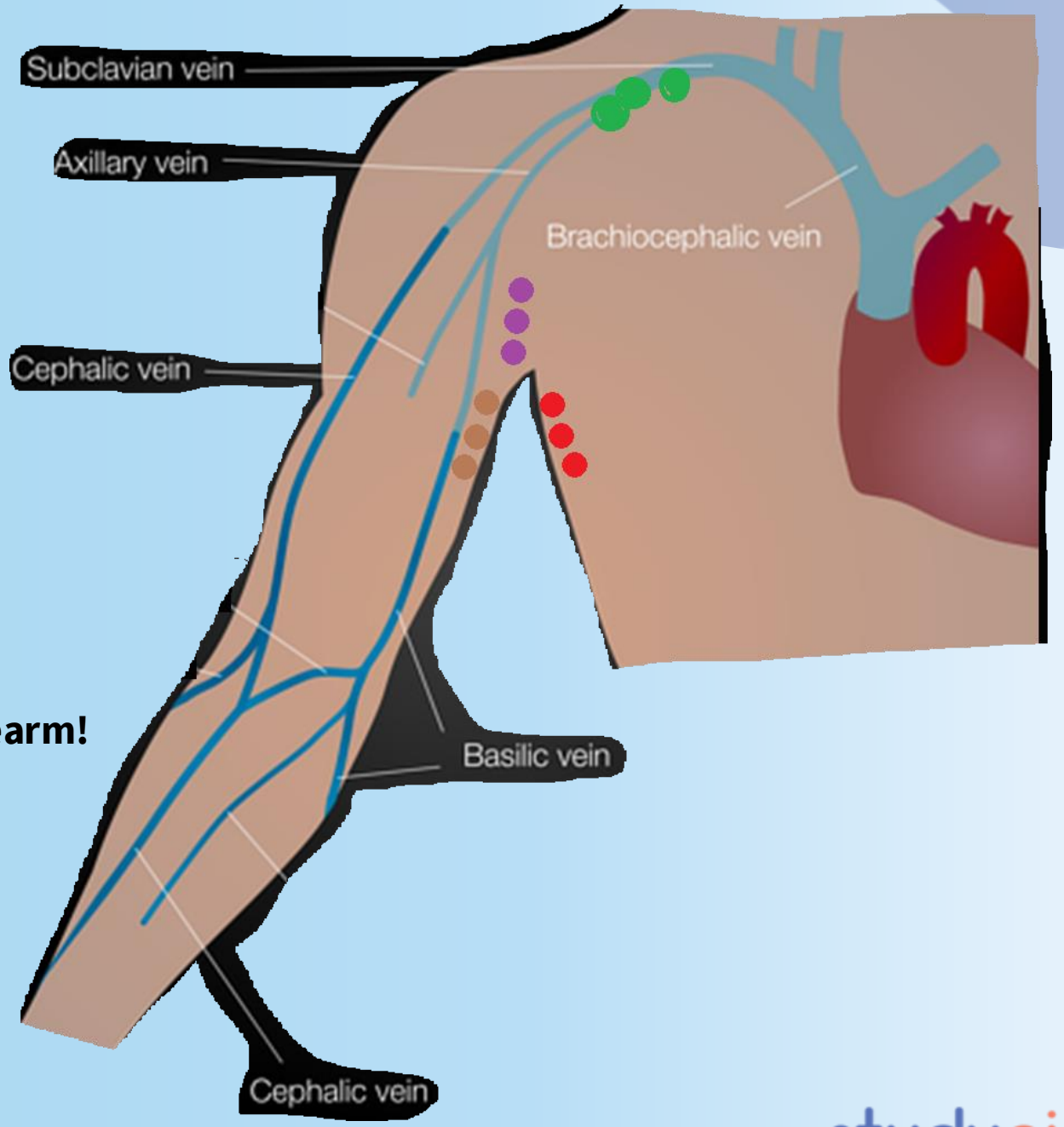

Remember that cubital lymph nodes drains the forearm!

Cephalic vein = **Apical** group

Basilic vein = **Anterior** + group

studyaid