Heart Embryology and Anatomy

By Thomas Dlugosz

studyaid

Brief Recall of Gastrulation

The process of gastrulation establishes 3 germ layers of the embryo: **ectoderm, mesoderm and endoderm.**

It forms a trilaminar embryonic disk by day 21 of development.

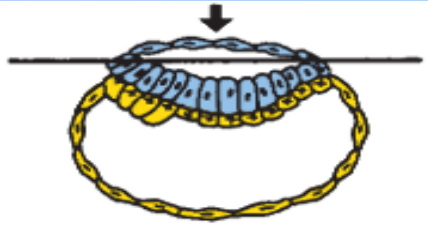

Blastula at Day 14

Gastrula at Day 21

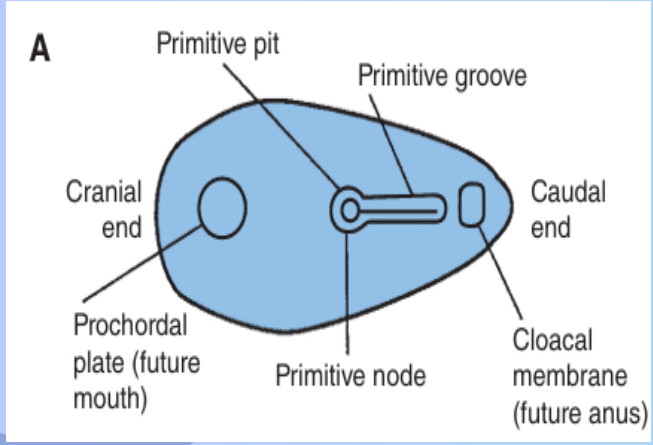

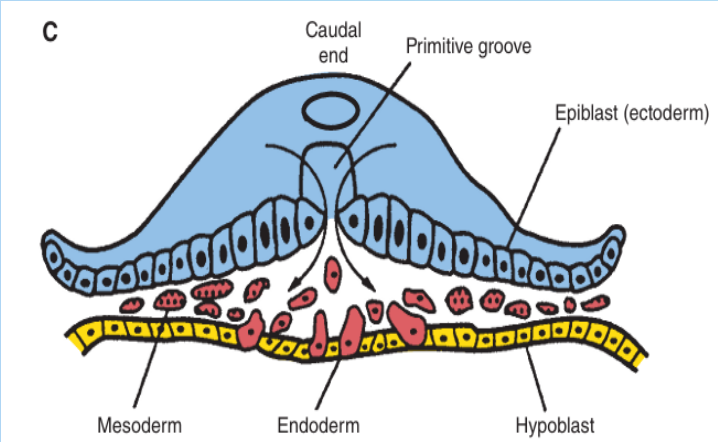

Once through the primitive groove, epiblasts migrate out of the page towards cardiogenic area and become mesoderm

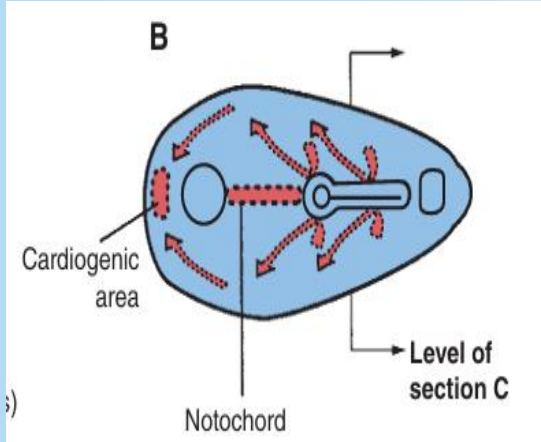

Cardiogenic area contains mesoderm that will be the future heart!

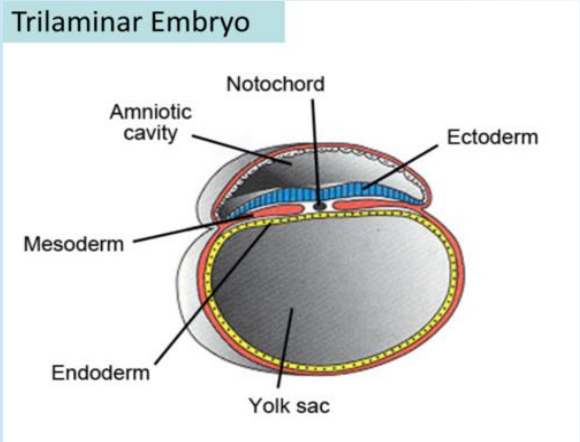

studyaid

Heart Embryology

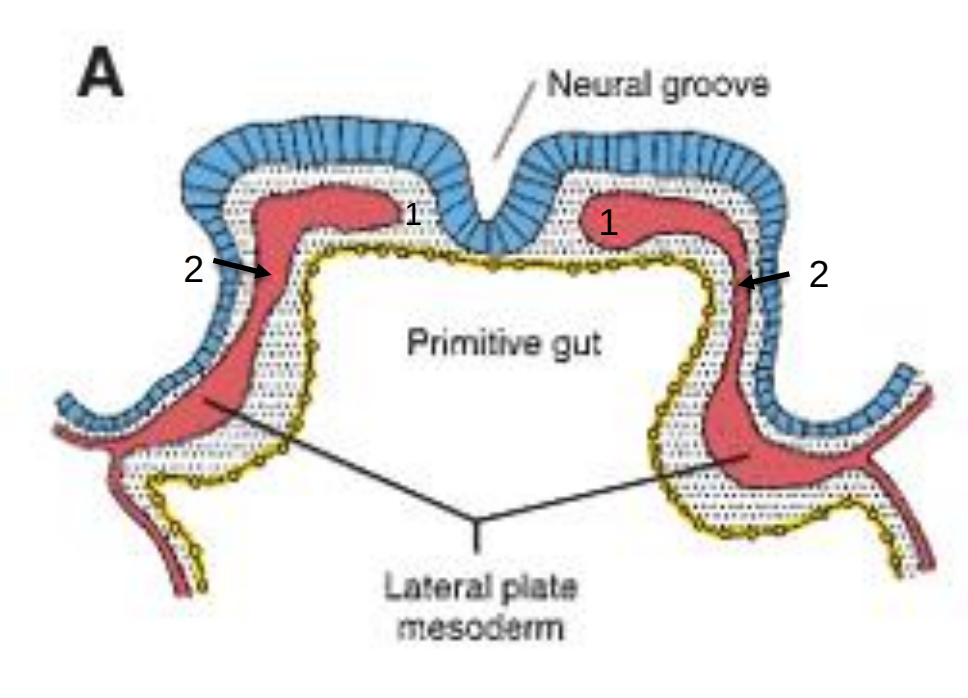

Cross section of gastrula in 3rd week at cardiogenic region. (1) Paraxial mesoderm. (2) intermediate mesoderm. Yellow cells are endoderm. Blue cells are ectoderm.

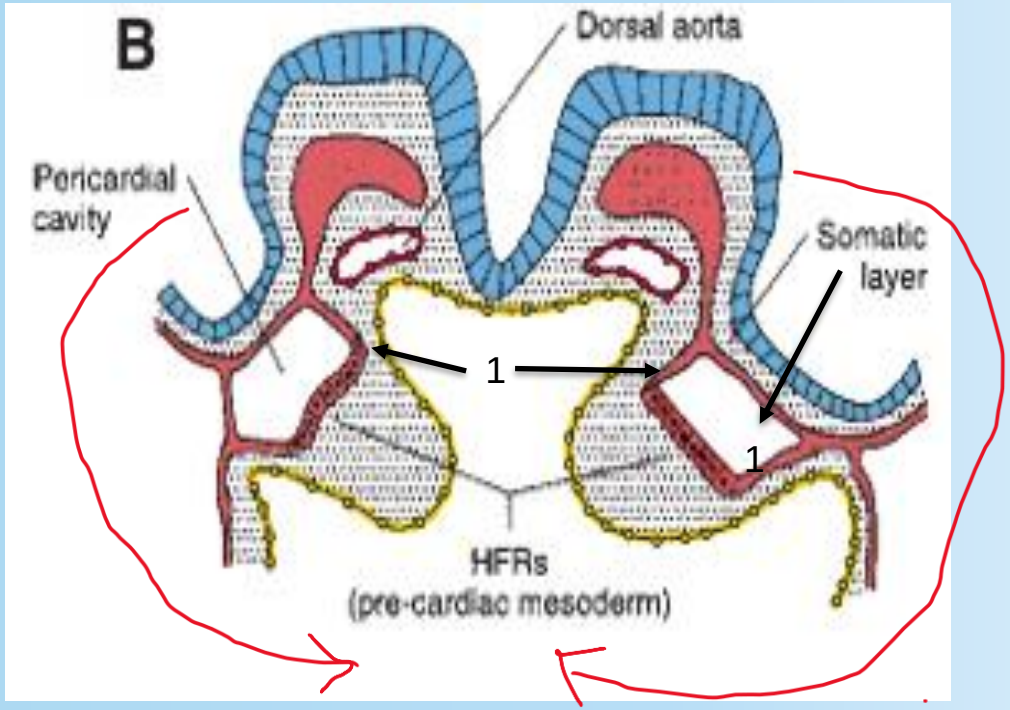

Lateral plate mesoderm then splits into somatic and splanchnic layers (1). Precardiac mesoderm moves into the splanchnic layer and differentiates into heart forming regions (HFRs). Lateral folding occurs as shown.

studyaid

Heart Embryology

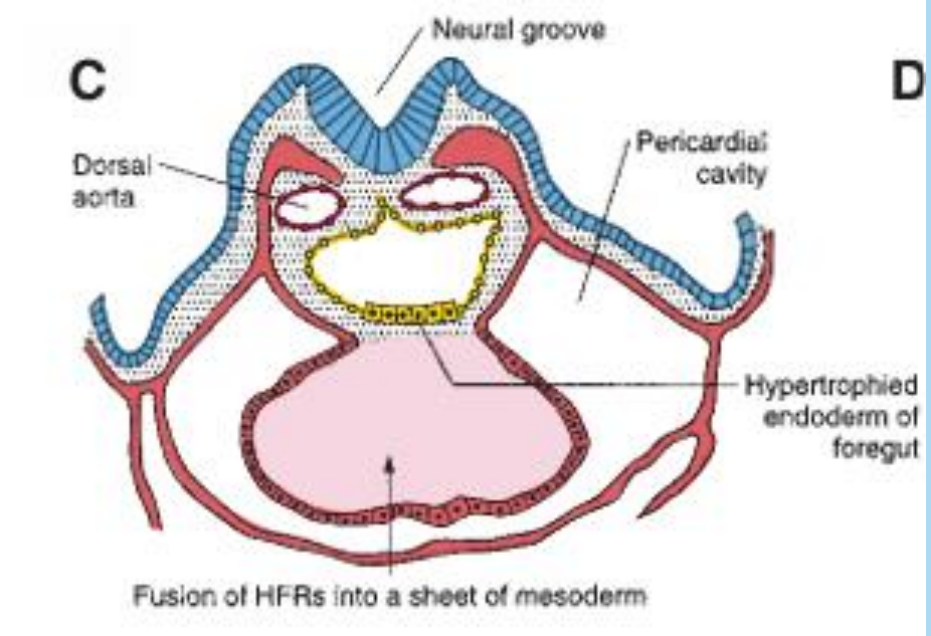

After lateral folding, HFRs fuse to form a mesoderm sheet. Endoderm is sealed off by lateral folding and is contained within the precardiac mesoderm

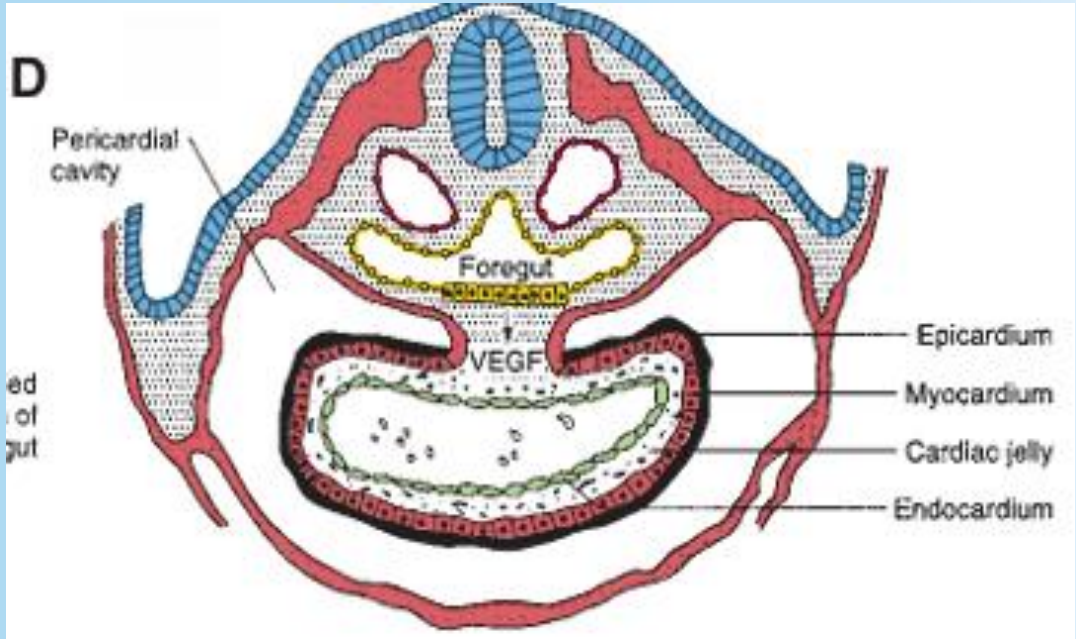

VEGF from hypertrophied endoderm causes the sheet of mesoderm to form discontinuous vascular channels that remodel into an **endocardial tube (endocardium).** Mesoderm overlying the endocardium forms **myocardium.** This secretes matrix proteins called **cardiac jelly.** Lastly more mesoderm then forms the **epicardium.** The **primitive heart tube** is now formed

studyaid

Cardiac Tube

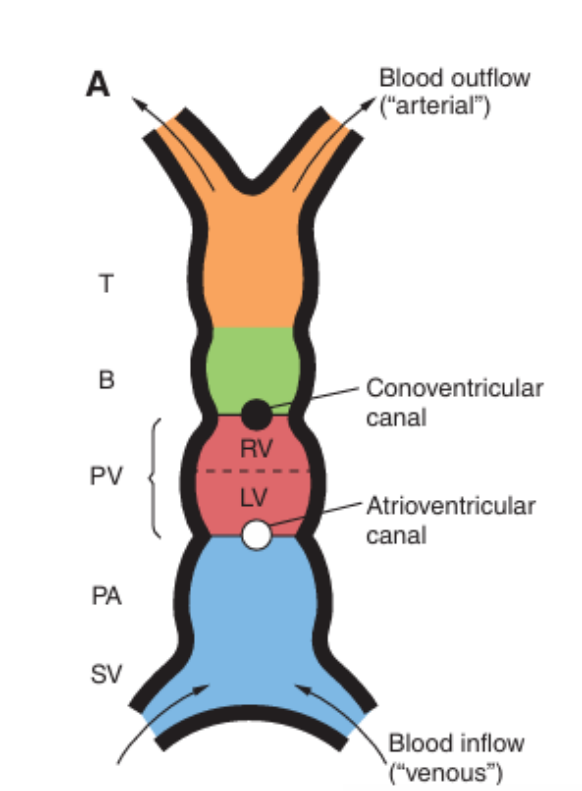

Embryonic Dilation	Adult Structure
Truncus asteriosus (T)	Aorta Pulmonary trunk
Bulbus cordis (B)	Smooth part of right ventricle **(conus arteriosus)** Smooth part of left ventricle **(aortic vestibule)**
Primitive ventricle (PV)	Trabeculated part of right ventricle (RV) Trabeculated part of left ventricle (LV)
Primitive atrium (PA)	Trabeculated part of right atrium Trabeculated part of left atrium
Sinus venosus (SV)	Smooth part of right atrium **(sinus venarum)**[a] Coronary sinus Oblique vein of left atrium

Cardiac Looping

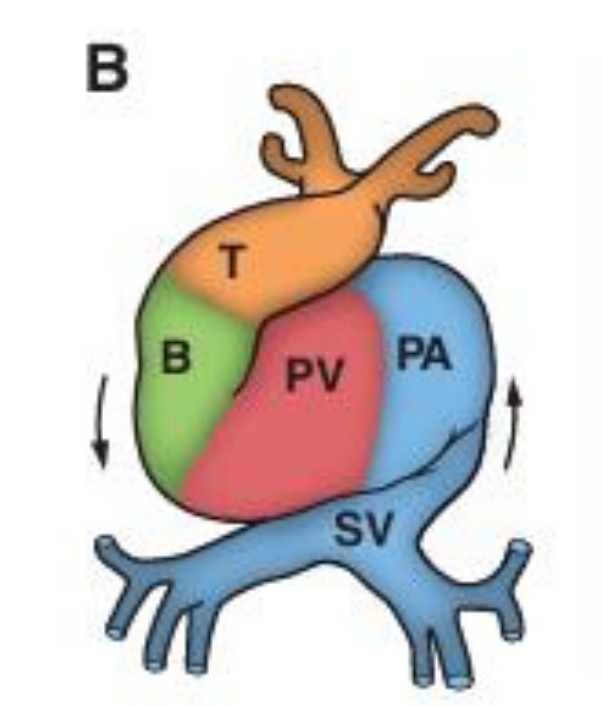

Truncus Arteriosus and Bulbis cordis moves down and to the right. Primitive ventricle moves ventrally (out of page). Primitive atria and Sinus venosus move dorsally (into page) and upwards

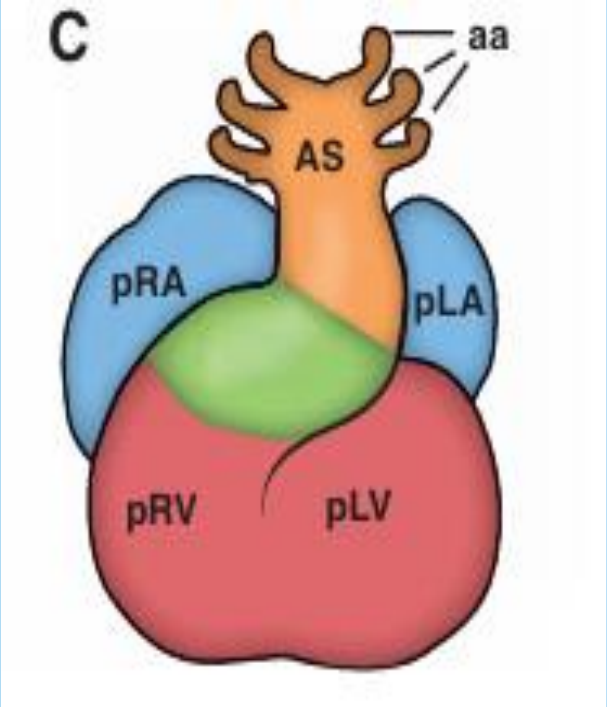

Basic heart shape is established. Aortic Sac of the Truncus Arteriosus is also established

Legend:
T-Truncus Arteriosus
B- Bulbus cordis
PV- Primitive Ventricle
PA-Primitive Atria
SV- Sinus Venosus

AS- Aortic Sac
pRA- Primitive Right Atrium
pLA- Primitive Left Atrium
pRV-Primitive Right Ventricle
pLV-primitive Left Ventricle
aa- Aortic Arches

studyaid

Development of Cardiac Septa

We have general heart shape. Now we must make walls to separate the atria and ventricles!

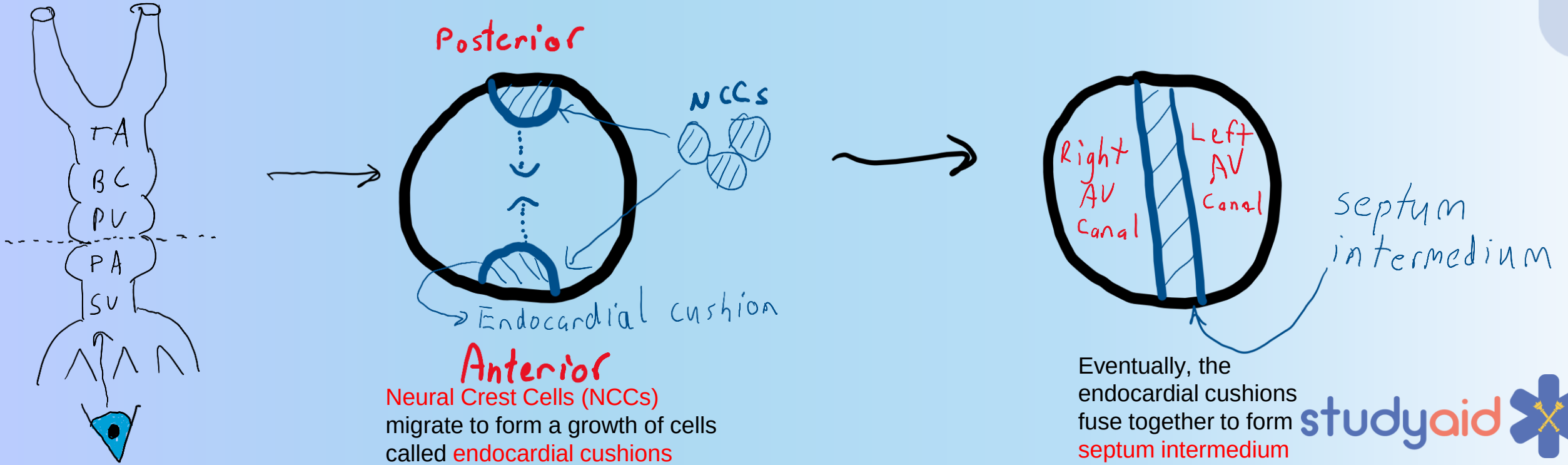

Neural Crest Cells (NCCs) migrate to form a growth of cells called endocardial cushions

Eventually, the endocardial cushions fuse together to form septum intermedium

studyaid

Development of Heart Septa

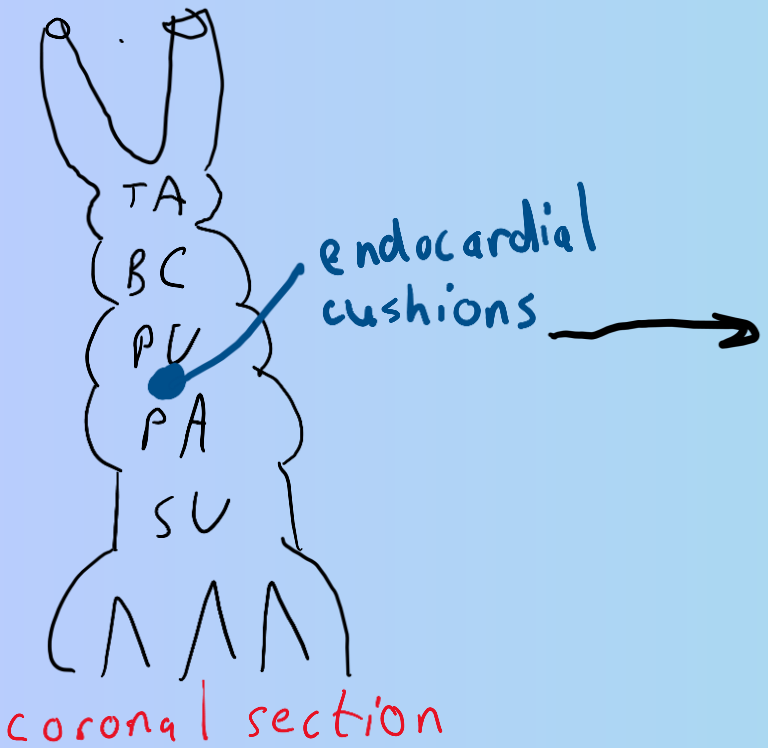

coronal section

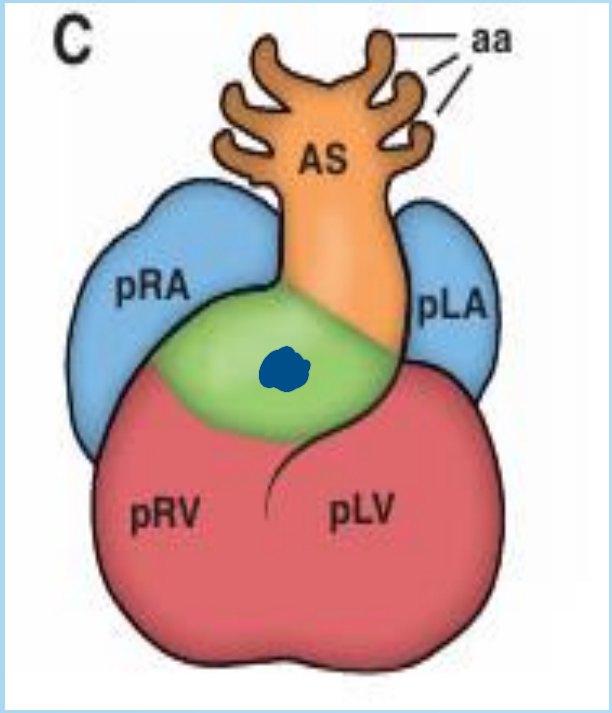

Endocardial cushion location after cardiac looping. **It is behind bulbis cordis**

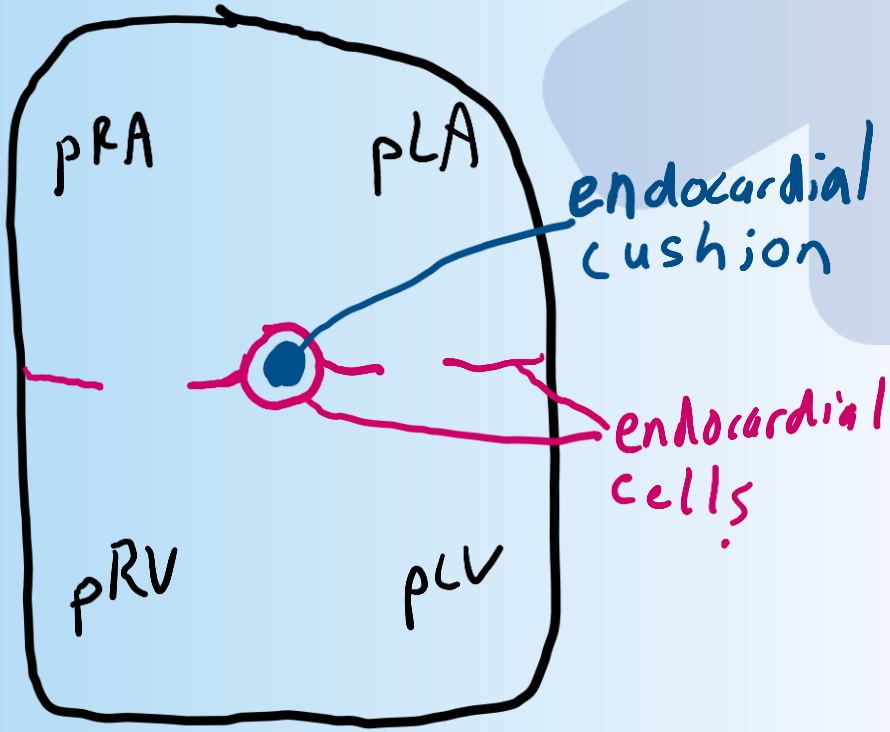

coronal section after looping and growth

studyaid

Development of Heart Septa

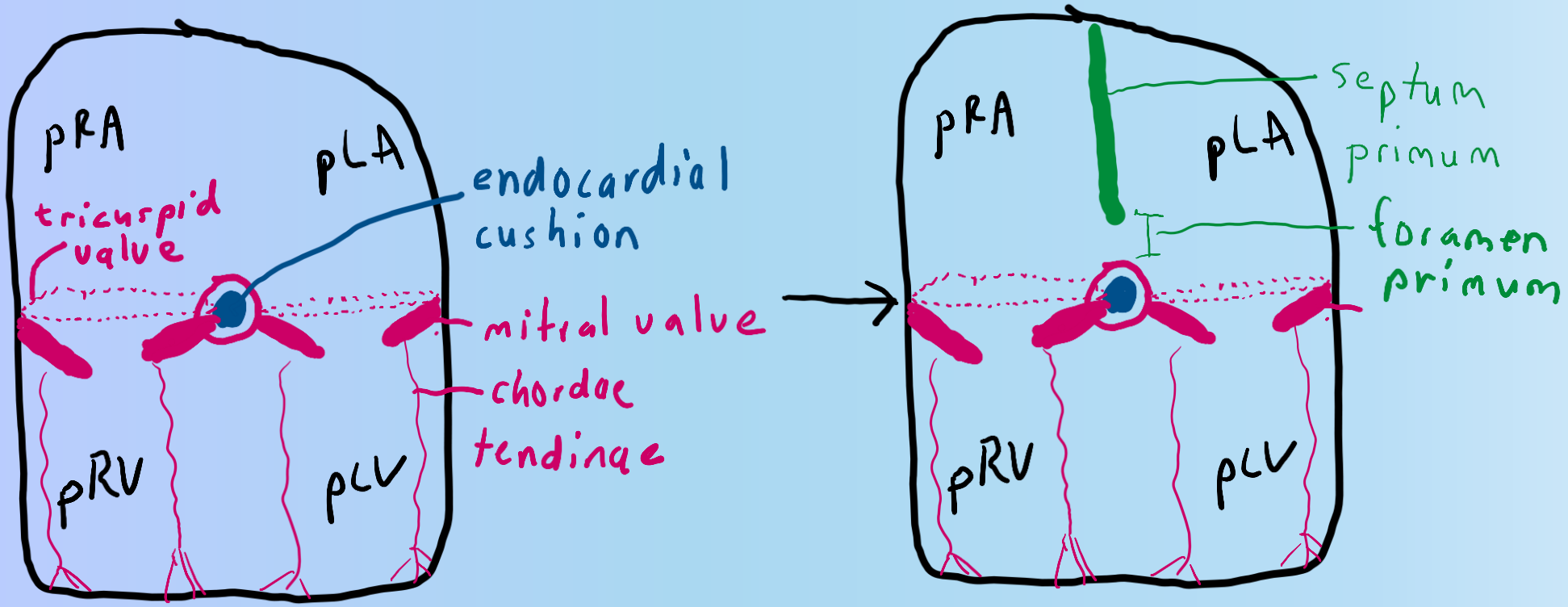

Cells move off the endocardial cushions and heart wall to form a slitted annulus. These are the **leaflets of the mitral and tricuspid valve.** Endocardial cells then move downward and attach to the heart wall, forming **chordae tendinae**

A growth of tissue from the superior roof of the heart moves downwards, called septum primum, but does not fully connect to endocardial cushions. This gap is called foramen primum. This structure is present around day 27-34

studyaid

Development of Heart Septa

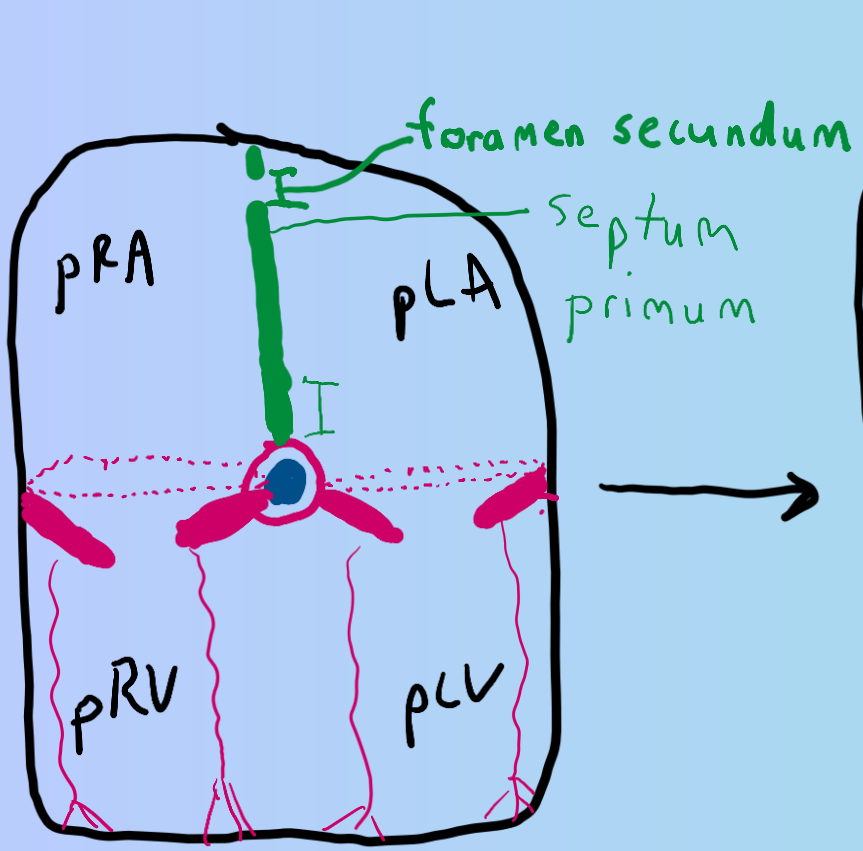

Septum primum eventually reaches the endocardial cushions and foramen primum is sealed off at day 34. However, apoptosis occurs in a superior segment of septum primum, forming **foramen secundum.**

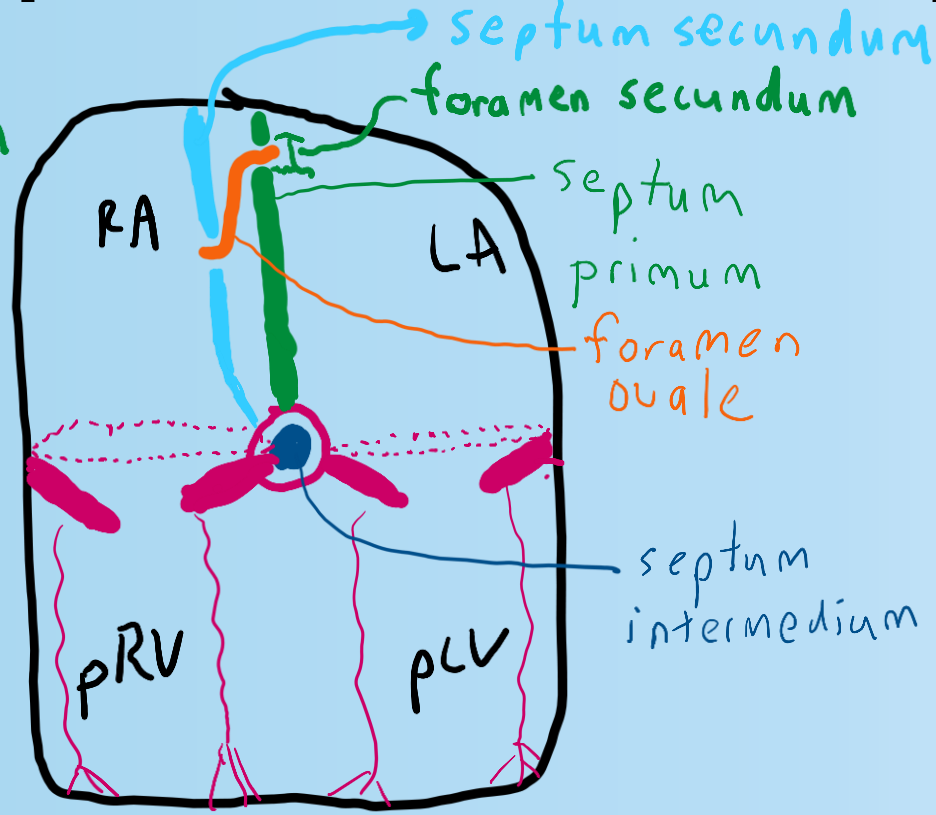

A second growth of tissue called **septum secundum** occurs to the right of septum primum. A gap remains between septum secundum and primum however, forming **foramen ovale.** We now have right and left atria

- Why do we have some kind of foramen between the atria in the heart during fetal development?
- It's to bypass pulmonary circulation because the placenta is oxygenating blood!

- How does foramen ovale seal?
- When we are born, blood is shunted to the lungs which returns to the left atrium. This increases left atrial pressure and slams the bendy septum primum on to the stiffer septum secundum, causing a seal → fossa ovalis
- If it does not seal, we have an ASD called **patent foramen ovale**
- **PFO** is usually harmless

studyaid

Development of Heart Septa

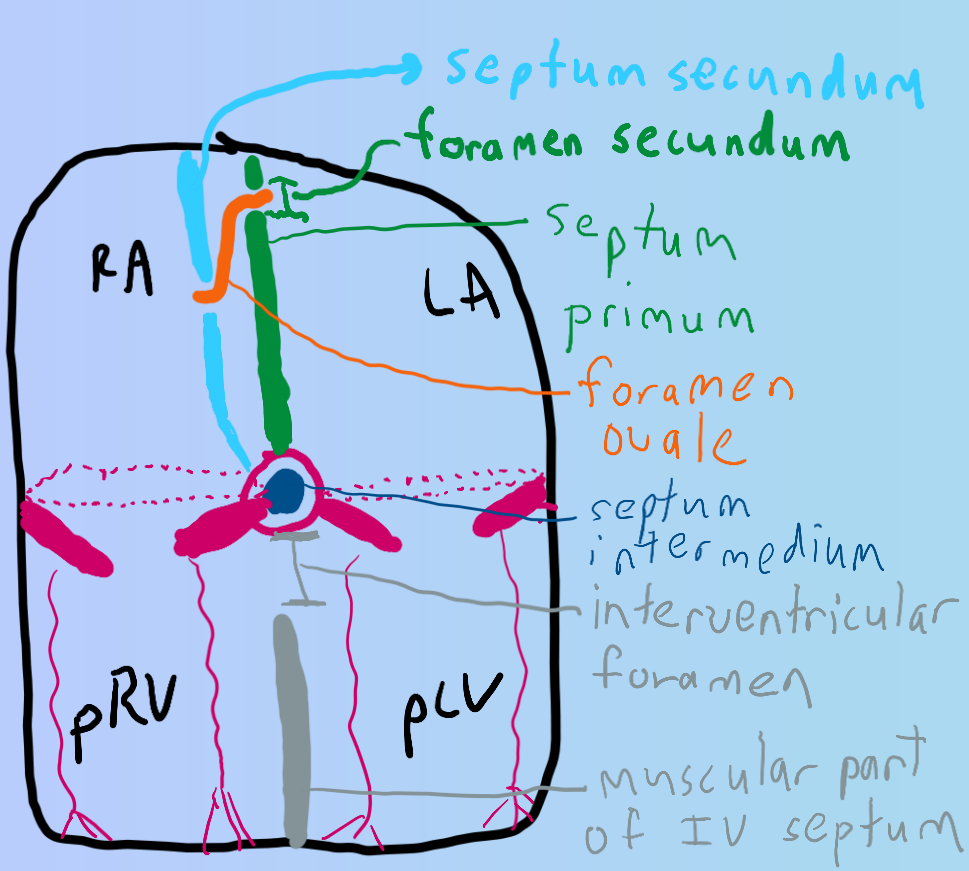

Mesoderm migrates from the floor of the primitive ventricles and moves outwards on the midline forming the **muscular part of the interventricular septum.** However, it does not connect to septum intermedium forming **interventricular foramen of the heart**

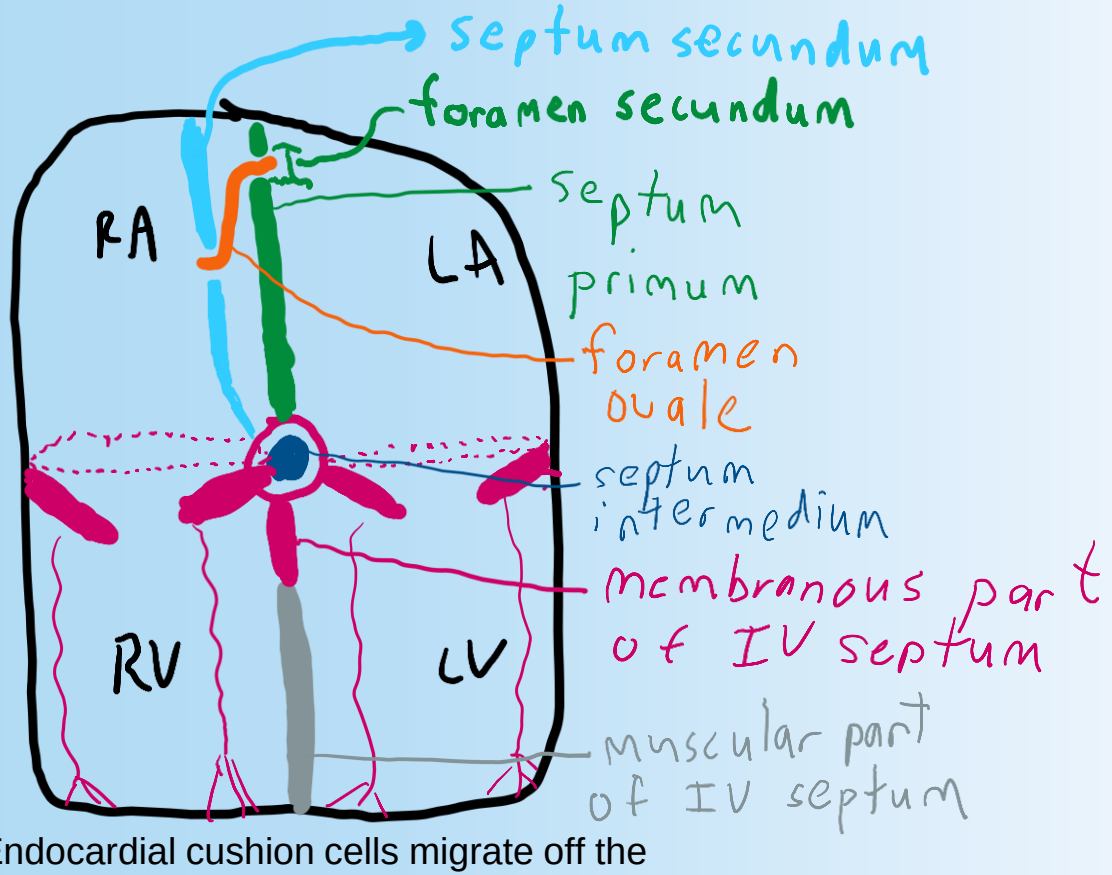

Endocardial cushion cells migrate off the septum intermedium forming the **membranous part of the interventricular septum.** It moves downwards until it fuses with the **muscular part of the IV septum,** sealing off the interventricular foramen of the heart. We now have right and left ventricles

studyaid

Development of Aorticopulmonary Septum

The pulmonary trunk and aorta are separate from each other when we are born

After cardiac looping we have the following heart shape:

Truncus Arteriosus is getting blood from both ventricles.

We have to form another septum!

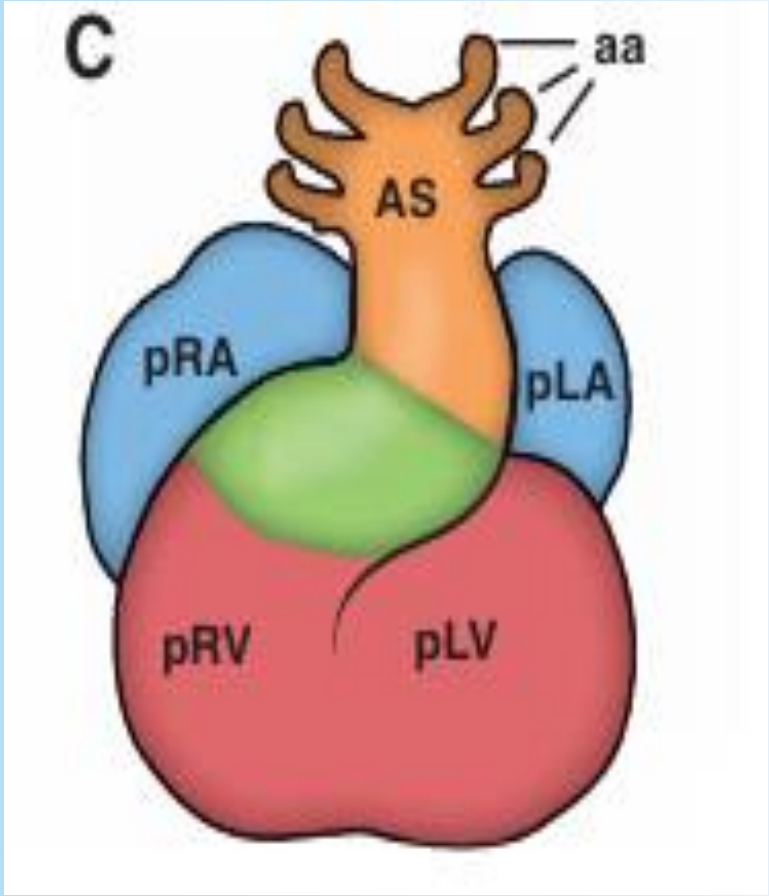

Development of the Aorticopulmonary Septum

- Neural crest cells migrate from the hindbrain down into the truncus arteriosus and bulbis cordis to form ridges: **truncal ridges and bulbar ridges**
- These ridges grow toward each other in a spiral fashion and fuse to form the **aorticopulmonary septum**

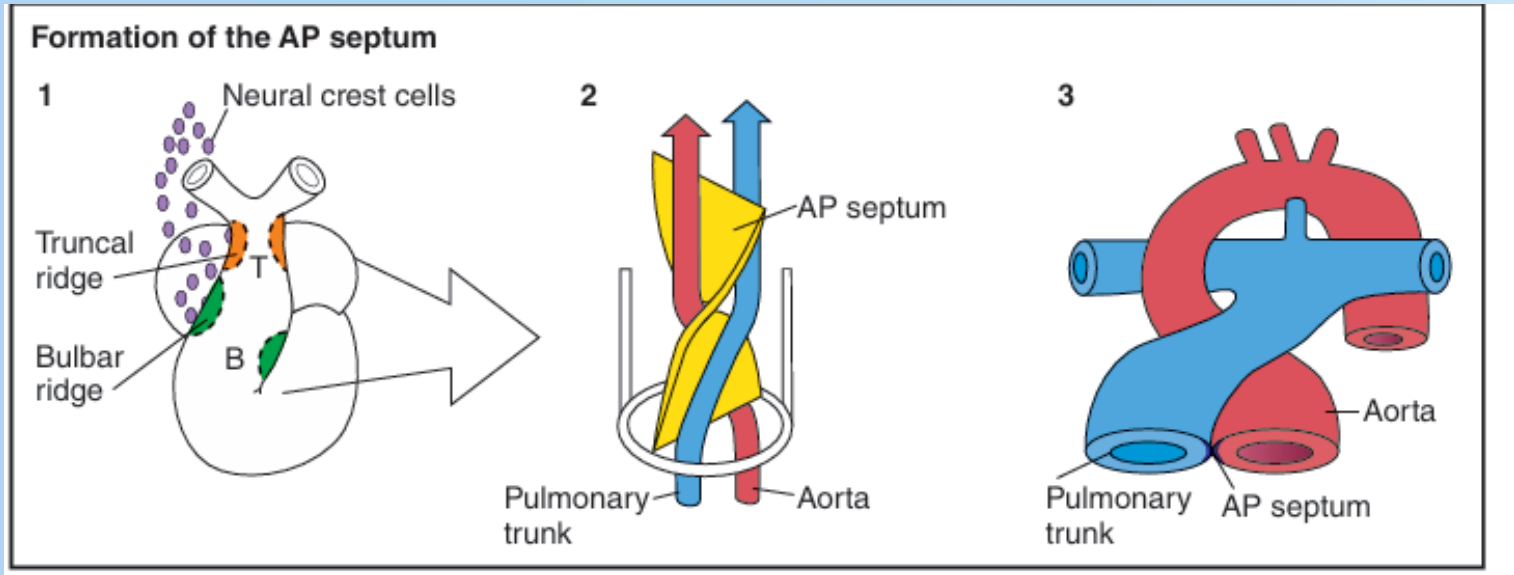

FIGURE 5.3. Formation of the aorticopulmonary (AP) septum. T = truncal ridges (*orange*), B = bulbar ridges (*green*).

Defects of the Aorticopulmonary Septum

Tetralogy of Fallot

Occurs if we have an asymmetric, unequal migration of neural crest cells causing a large diameter aorta and small diameter pulmonary trunk

Tetralogy: (**PROVE**)

1. **P**ulmonary Stenosis
2. **R**ight Ventricular Hypertrophy
3. **O**verriding Aorta (Collecting blood from both ventricles)
4. **VE**ntricular Septal Defect

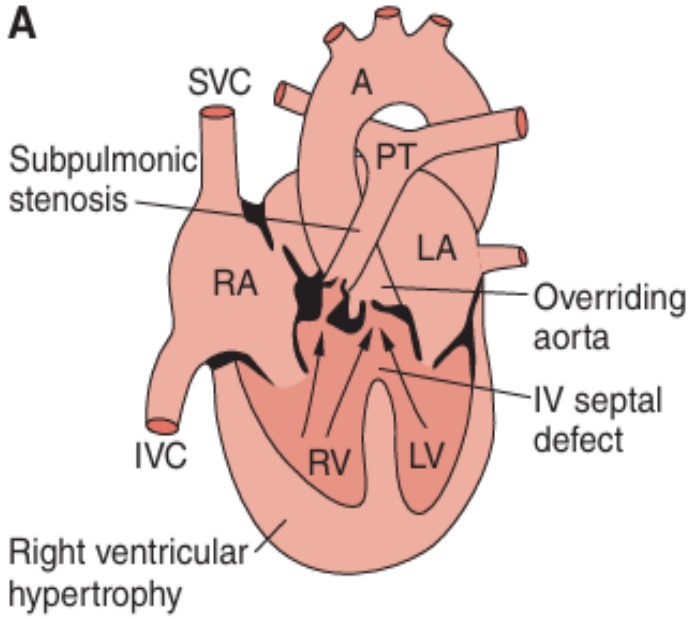

FIGURE 5.7. Tetralogy of Fallot. **A.** *Arrows* indicate the direction of blood flow. SVC = superior vena cava; RA = right atrium; IVC = inferior vena cava; RV = right ventricle; LV = left ventricle; A = aorta; PT = pulmonary trunk; LA = left atrium; IV = interventricular.



FIGURE 5.7. B. MRI. R = right pulmonary artery; L = left pulmonary artery; A = aortic arch; a = descending aorta.

studyaid

Thank You for Listening. Let’s Try a Wooclap

1 Go to wooclap.com

2 Enter the event code in the top banner

Event code
ETASNN

studyaid