Anatomy of the Shoulder/Axilla and Elbow Joint

By James Melvin B.Sc. (MD2)
and
Sai Voleti

studyaid

Anatomy of the Shoulder Girdle – Articulations

- **Glenohumeral (GH)/Shoulder joint** - ball-and-socket joint
- **Acromioclavicular (AC) joint** - synovial plane/gliding joint
- **Sternoclavicular (SC) joint** – synovial saddle joint
- **Scapulothoracic joint** – (not a true joint)

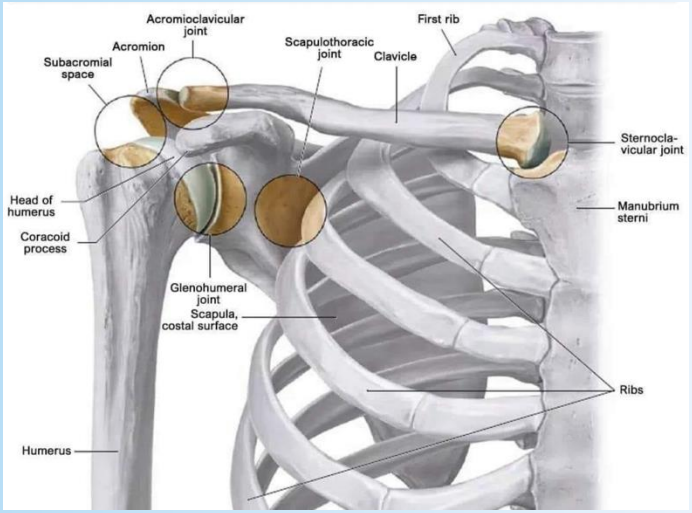

- **Key Structures**:
- **Humerus**
- **Scapula** (shoulder blade)
- **Clavicle** (collarbone)
- **Glenoid cavity** (cavity in the scapula, where head of humerus sits)

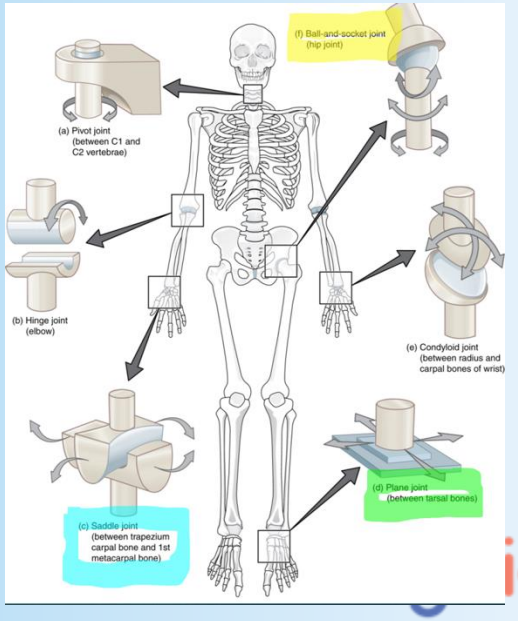

Movements of the shoulder joint
- a ball and socket joint that allows for movemet in ALL six planes of movement

1. **Flexion**
2. **Extension**
3. **Abduction**
4. **Adduction**
5. **Internal Rotation**
6. **External Rotation**

- **Circumduction**: combines flexion, extension, abduction and adduction

studyaid

Shoulder and Axilla
(other key anatomical structures)

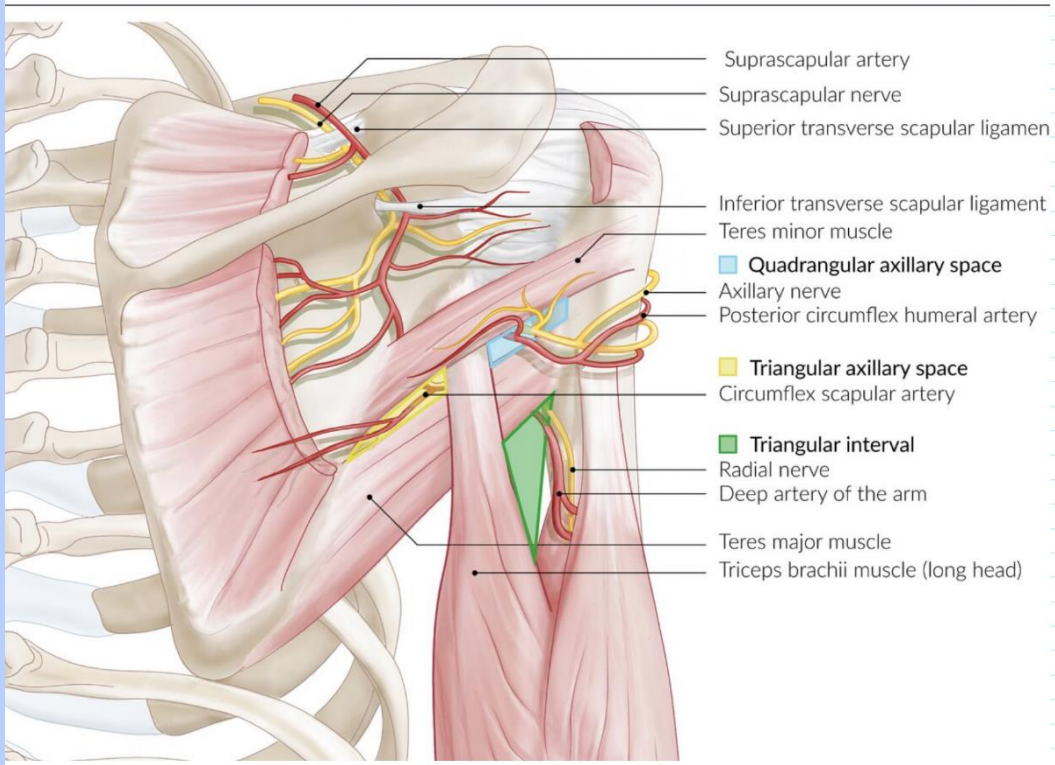

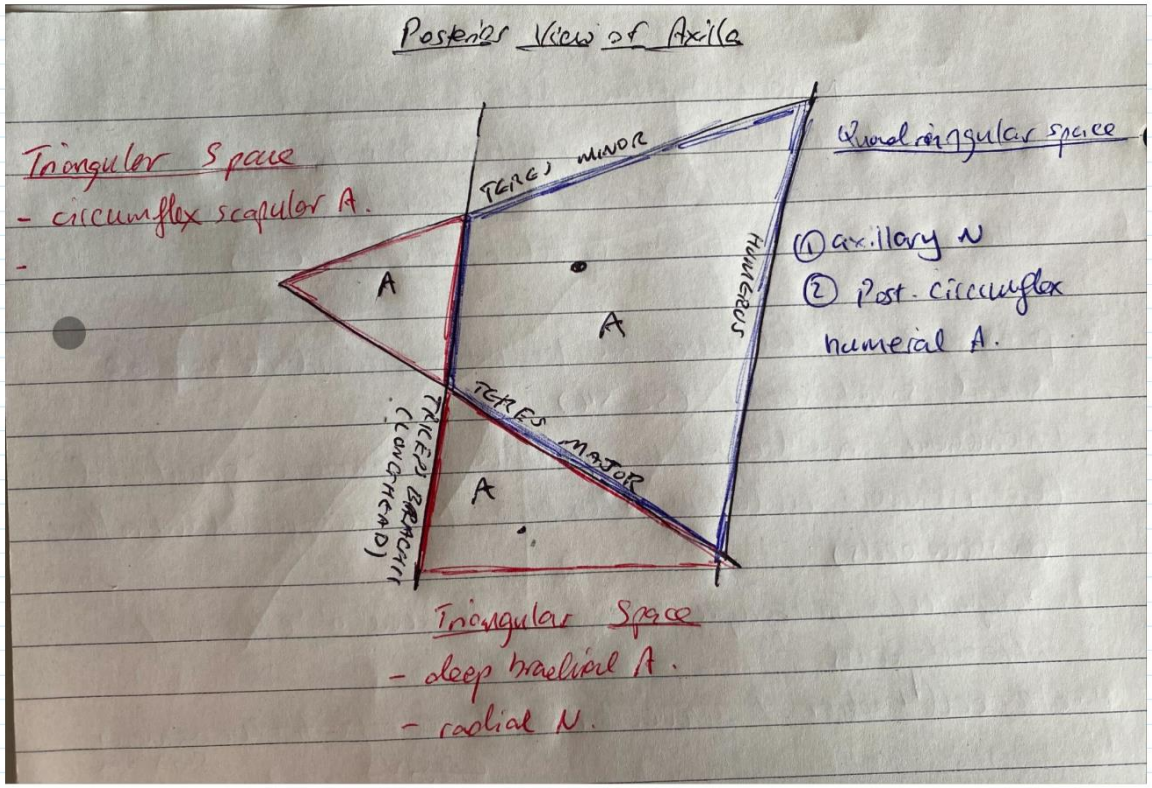

Blood supply to the shoulder and axilla

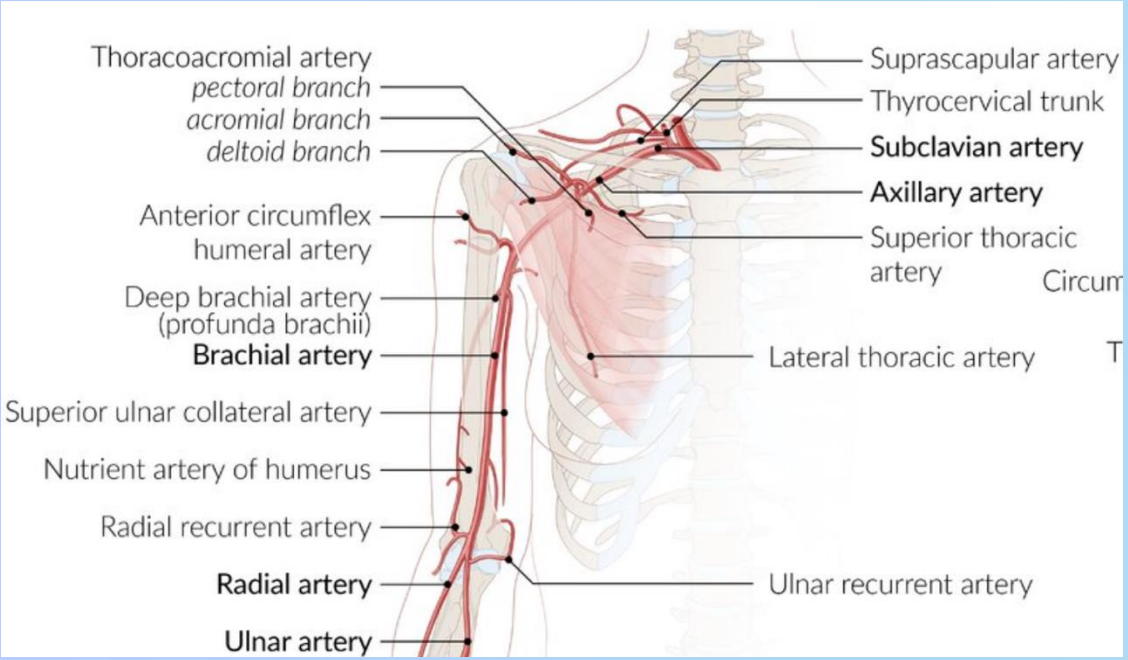

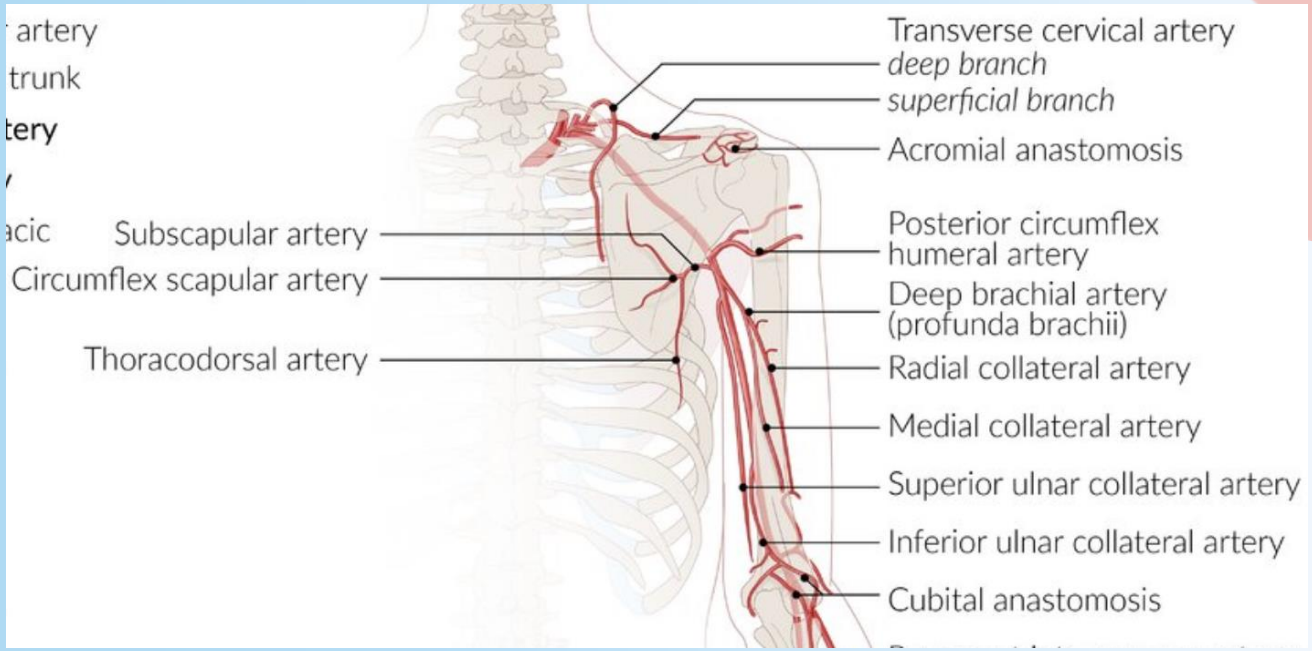

Anastamosis of Posterior Scapula

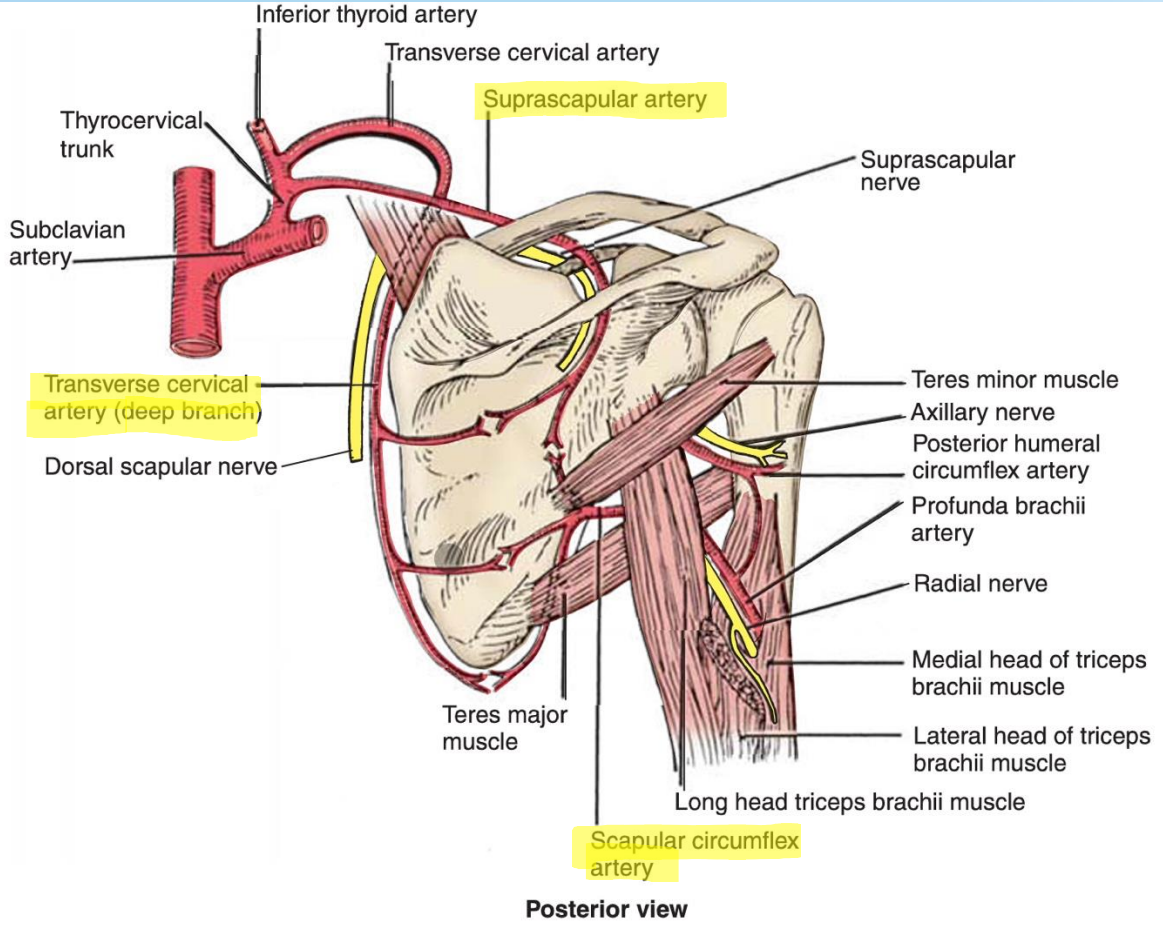

FIGURE 7.12. Structures of the shoulder region (posterior view).

studyaid

Superficial and deep venous supply to the axilla

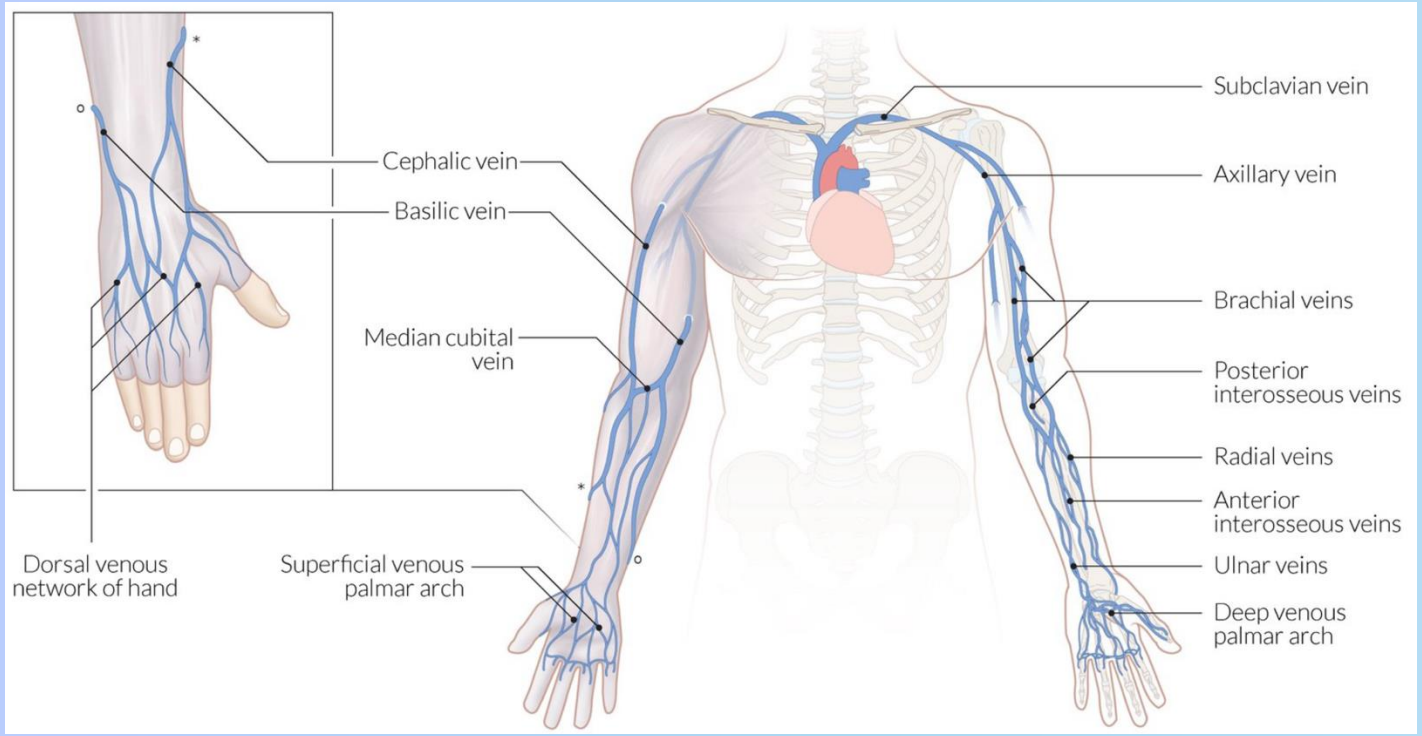

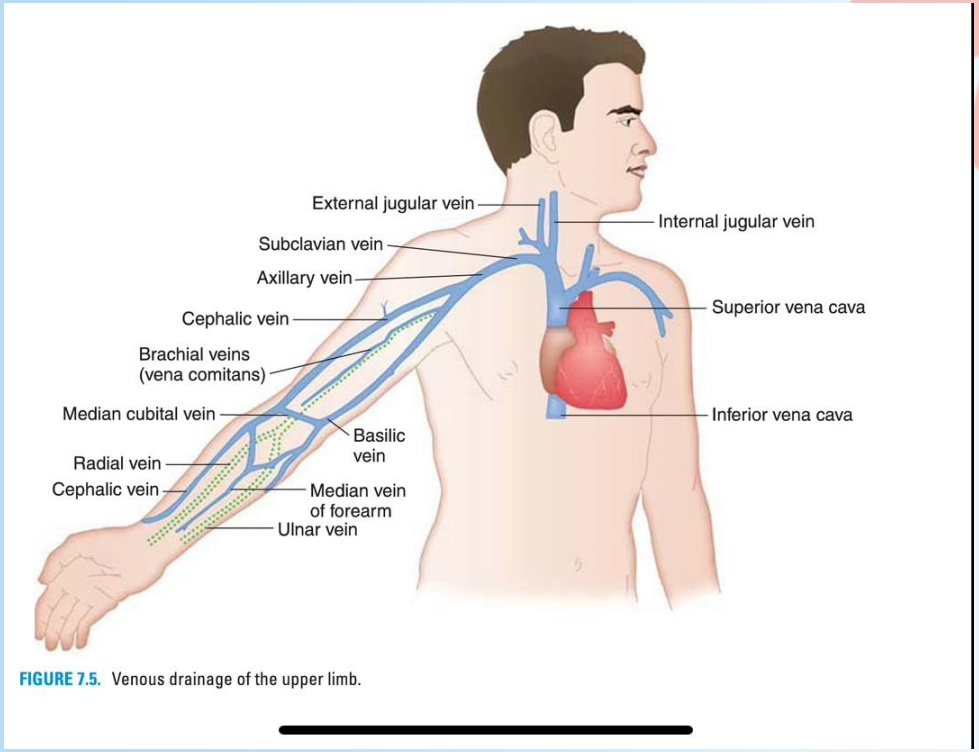

FIGURE 7.5. Venous drainage of the upper limb.

Innervation of the shoulder region and axilla

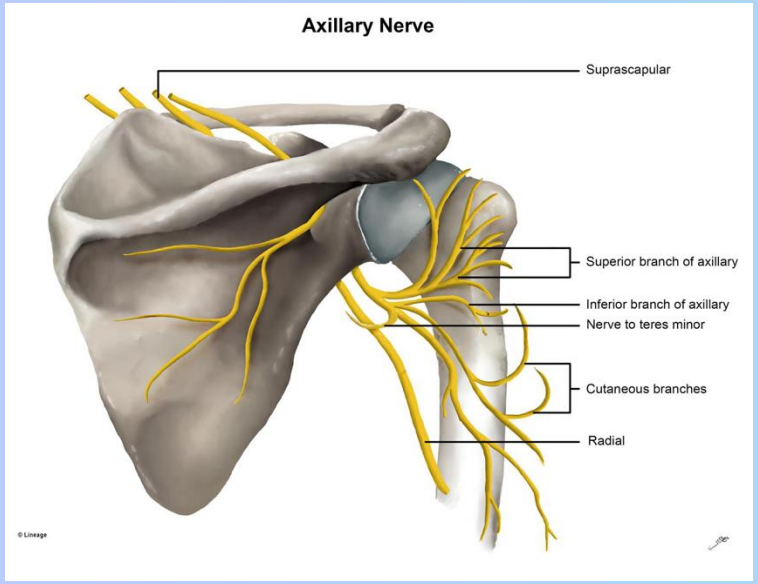

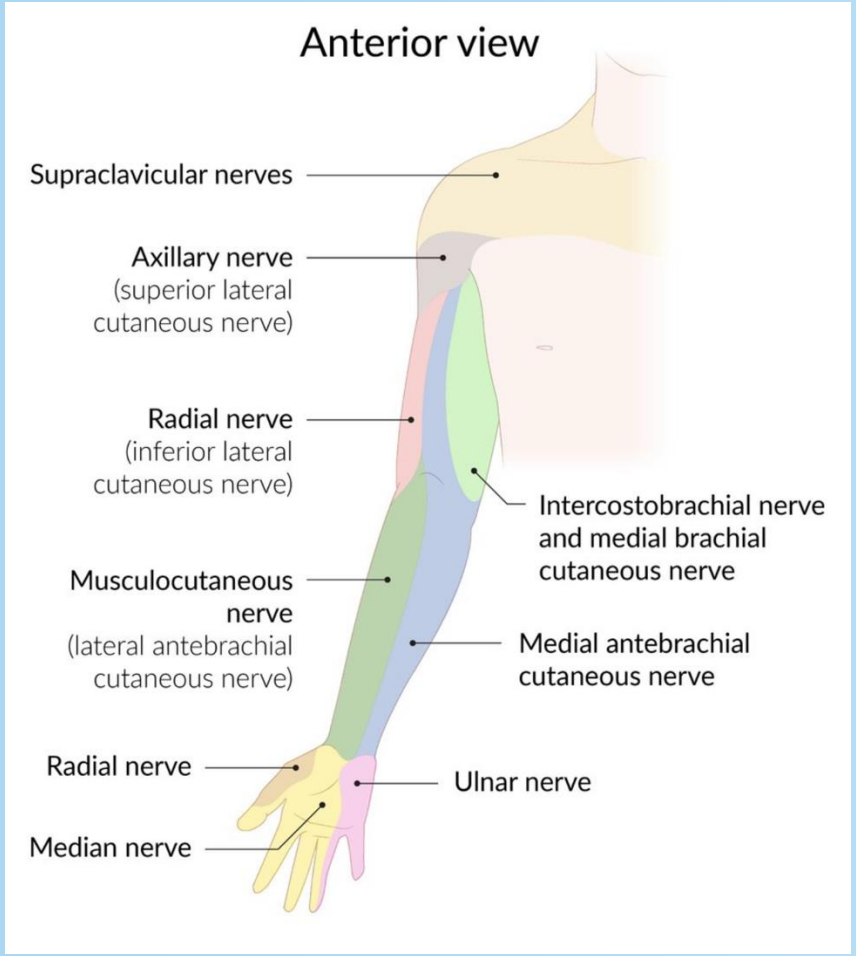

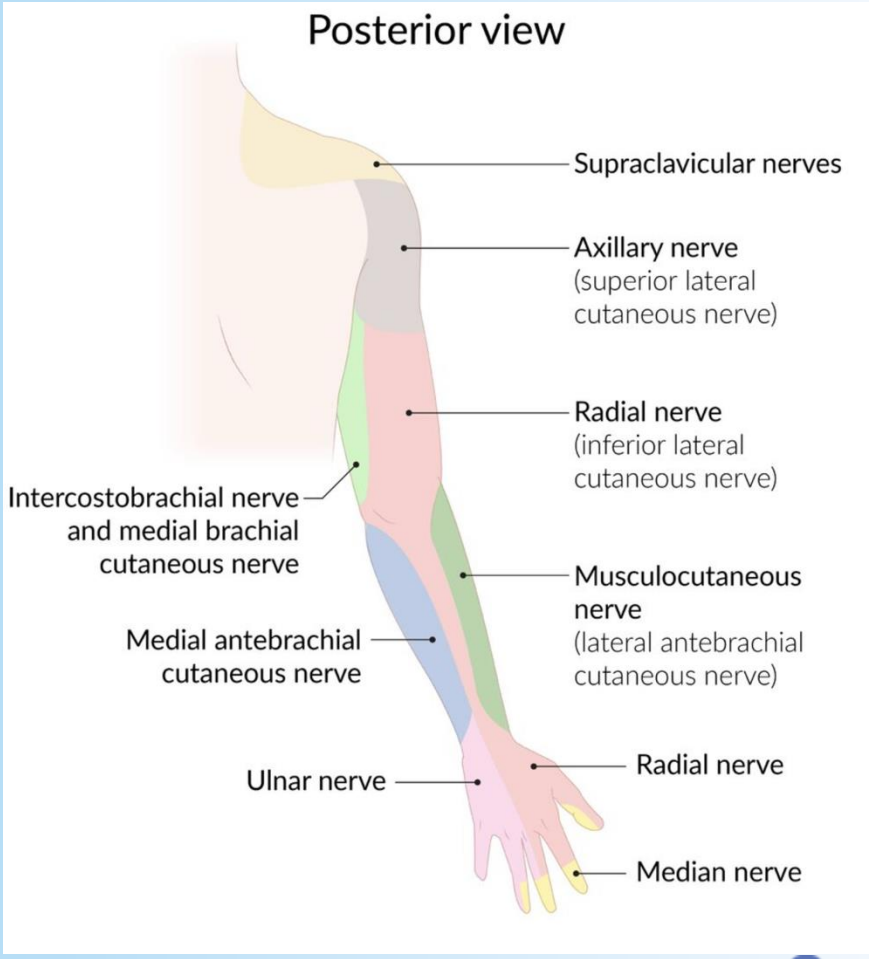

studyaid

Static vs. Dynamic Stability of the GH joint

Static Stability	Dynamic Stability
Glenoid Labrum: Deepens the glenoid cavity. **Ligaments**: Glenohumeral, Coracohumeral ligaments, Coracoacromial ligaments **Joint capsule**: Surrounds the shoulder joint.	Rotator Cuff Muscles

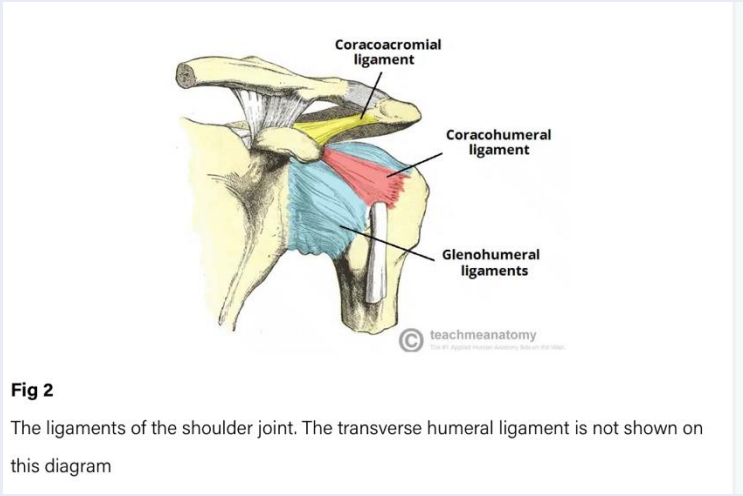

Fig 2

The ligaments of the shoulder joint. The transverse humeral ligament is not shown on this diagram

Key facts — Table quiz

Supraspinatus muscle	**Origin**: supraspinatous fossa of scapula **Insertion**: greater tubercle of humerus **Innervation**: suprascapular nerve (C4, C6) **Function**: initiation of abduction of arm to 15° at glenohumeral joint; stabilization of humeral head in glenoid cavity.
Infraspinatus muscle	**Origin**: infraspinatous fossa of scapula **Insertion**: greater tubercle of humerus **Innervation**: suprascapular nerve (C5, C6) **Function**: external rotation of arm at glenohumeral joint; stabilization of the humeral head in glenoid cavity.
Teres minor muscle	**Origin**: lateral border of scapula **Insertion**: greater tubercle of humerus **Innervation**: axillary nerve (C5, C6) **Function**: external rotation and adduction of arm at glenohumeral joint; stabilization of the humeral head in glenoid cavity.
Subscapularis muscle	**Origin**: medial two-third of the subscapular fossa **Insertion**: lesser tubercle of the humerus **Innervation**: upper and lower subscapular nerves (C5, C7) **Function**: internal rotation of arm, stabilization of humeral head in glenoid cavity.
Mnemonic	Rotator cuff **SITS** on the shoulder (**S**upraspinatus, **I**nfraspinatus, **T**eres minor, **S**ubscapularis)

studyaid

Shoulder Subluxation/Shoulder Dislocation

- **Anterior dislocation** (95% of dislocations)
  - Humerus moves forward out of the socket. May injure axillary N./posterior circumflex humeral A.
- **Posterior dislocation**: Humerus moves backward. (4% of dislocations)
  - Due to fracture of lesser tuberosity/injures subscapularis tendon
- **Inferior dislocation** (1% of dislocations). Hyperabudction/axillary N. + A. damage
- **Superior dislocation:** Not possible due to limitation of the coracoacromial arch

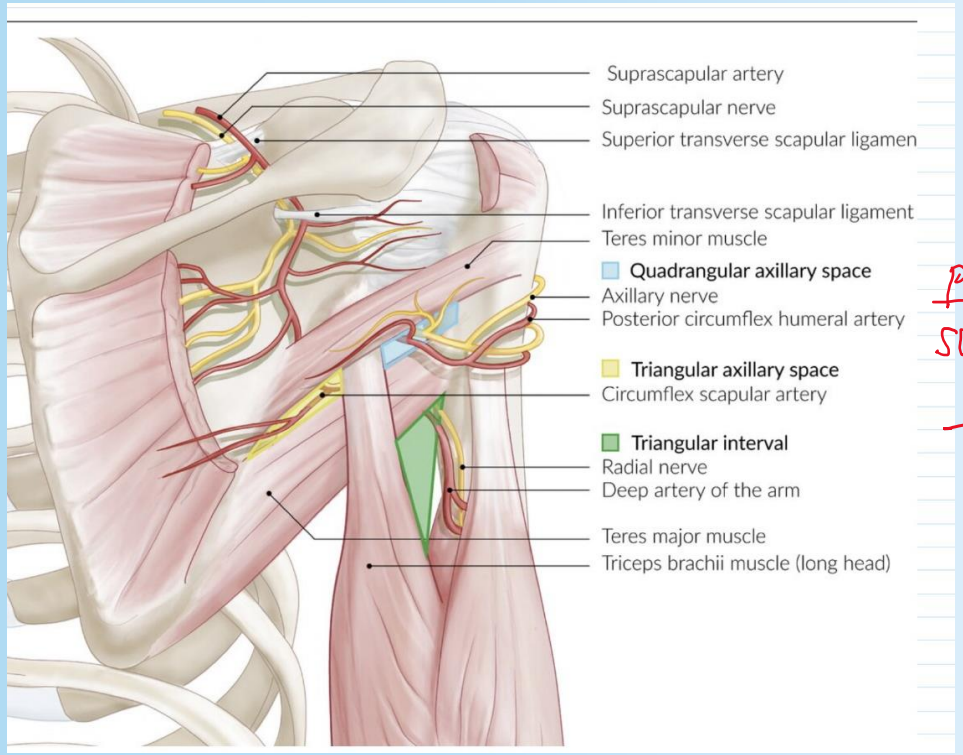

post. view of shoulder joint

rotation by 180°

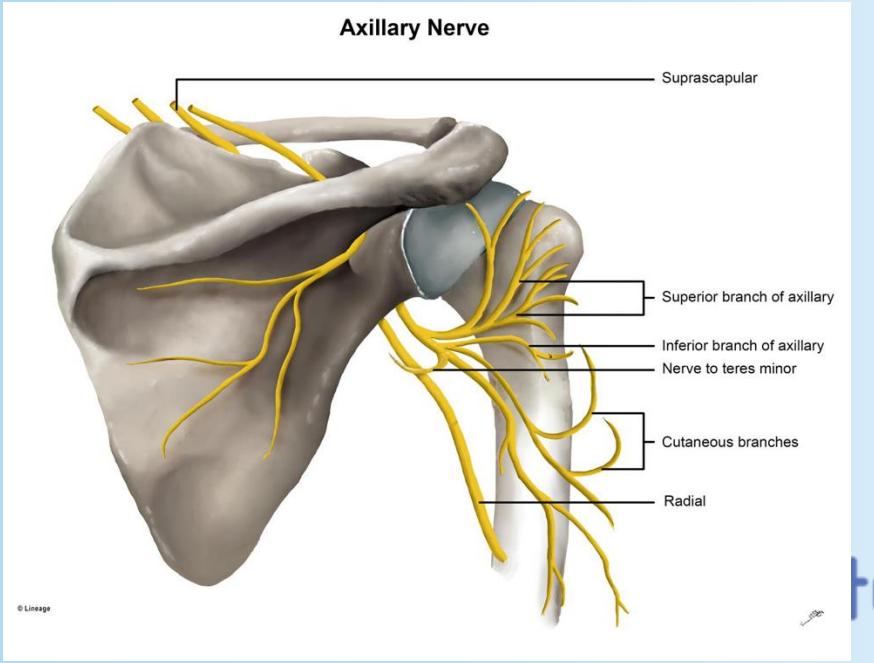

ant. view of shoulder joint

tudyaid

Other common shoulder pathologies

- **Rotator cuff Tear**:
- **Cause**: Overuse or acute injury.
- **Symptoms**: Pain, weakness, decreased range of motion.

- **Impingement Syndrome**: (subacromial bursa)
- **Cause**: Compression of the rotator cuff tendons under the acromion.
- **Symptoms**: Pain, especially with overhead movement.

- **Labral Tears (SLAP tear)**:
- **Cause**: Injury or overuse, especially in throwing sports.
- **Symptoms**: Pain, instability, clicking sounds in the shoulder (crepitus)

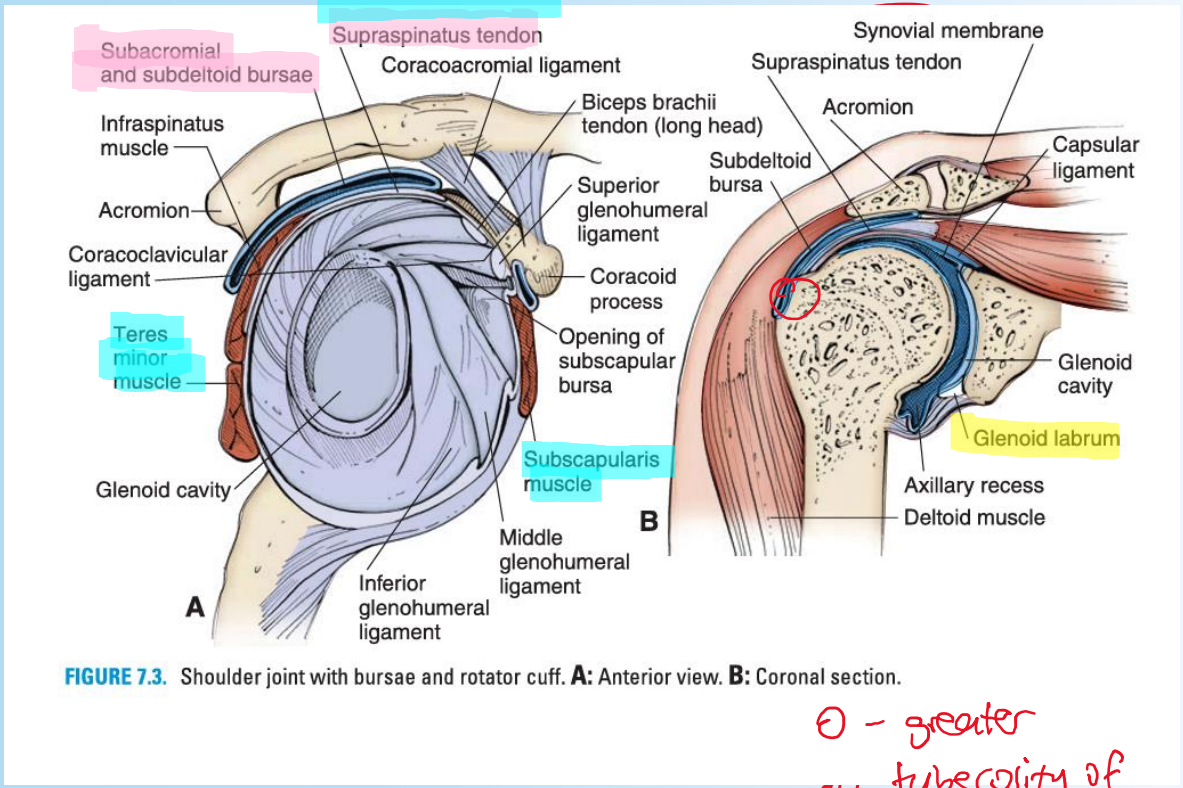

FIGURE 7.3. Shoulder joint with bursae and rotator cuff. **A:** Anterior view. **B:** Coronal section.

Take home messages

- Shoulder joint is composed of Glenohumeral, Acromioclavicular and Sternoclavicular joint.
- Glenohumeral, Coracohumeral ligaments, Coracoacromial ligaments provide static support, whereas the rotator cuff (mnemonic: SITS) provides dynamic stability
- The glenohumoral joint allows a wide range of motion but is most prone to instability.
- Common pathologies include subluxations, dislocations, and rotator cuff injuries.
- By understanding the anatomy of the shoulder joint, we can predict most vulnerable structures to injury (e.g. Anterior dislocation couples to axillary nerve injury, edema in the subacromial bursa/tendinitus of the supraspinatus muscle)

studyaid

Elbow joint: Basics

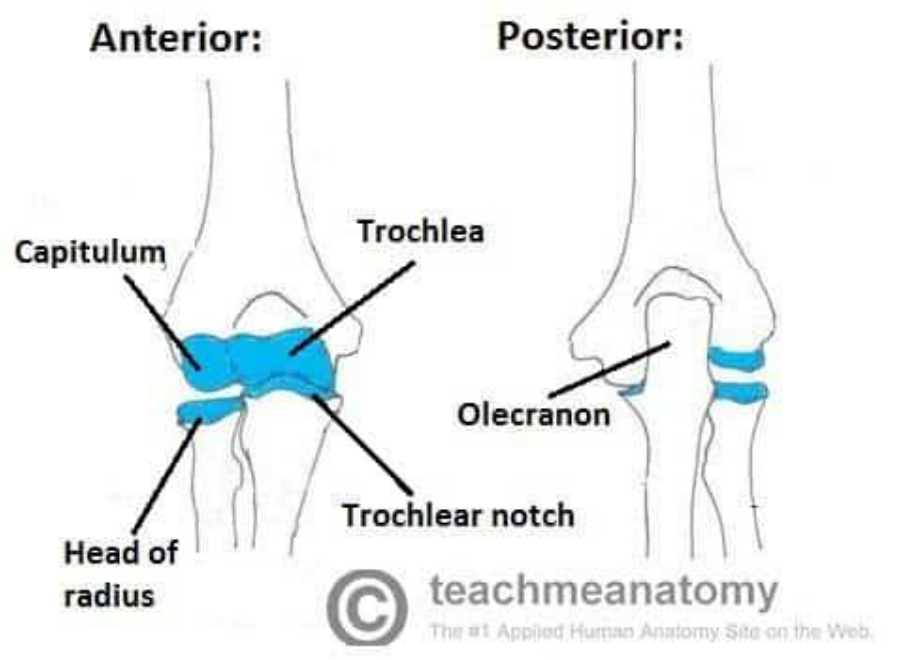

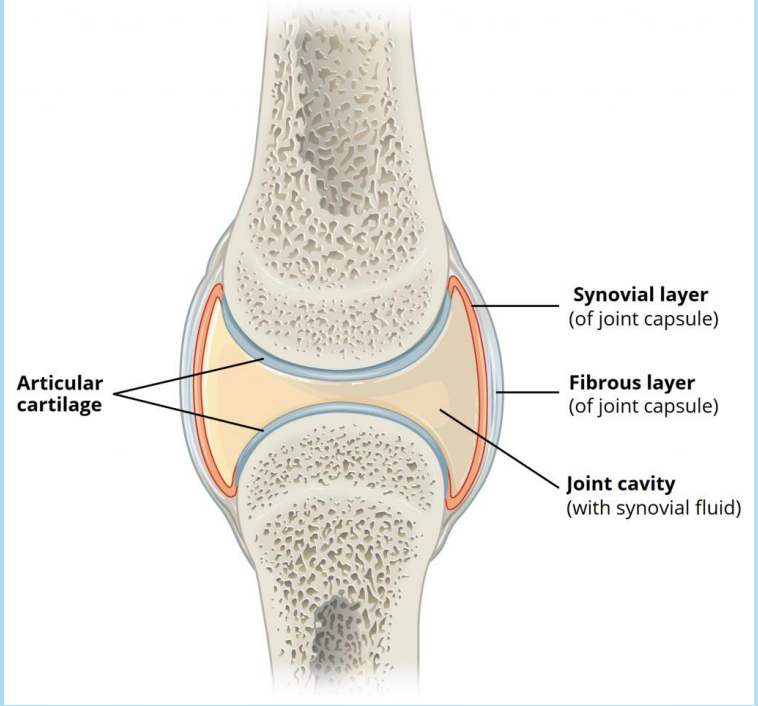

- Joint capsule encloses the elbow joint, full of synovial fluid
- Proximal vs distal

- Synovial hinge joint; Movement in only plane, as opposed to the shoulder joint.
- Covered by articular cartilage: prevents grinding and rubbing of the bones = smooth motion. No cartilage = lots of pain, inflammation etc.
- Elbow joint involves two bones, radius and ulna
- Radius = bone on thumb side
  - Rotate your thumb in a circle, circle has radius therefore radius is present on the thumb side
- Ulna = bone on pinky side
- Radius has weak attachment to humerus, articulates with the capitulum of humerus
- Ulna has strong attachment, literally claws onto the humerus. This part is called the olecranon.

studyaid

The Elbow joint: Ligaments & osteology

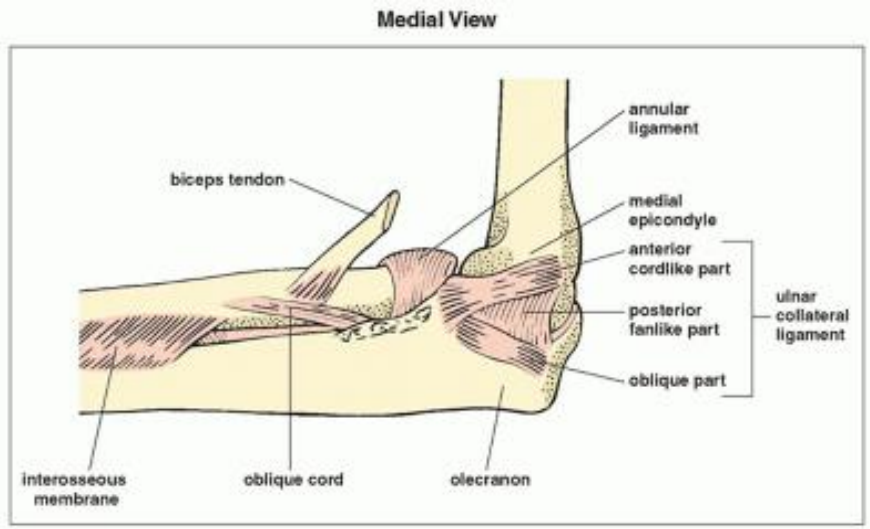

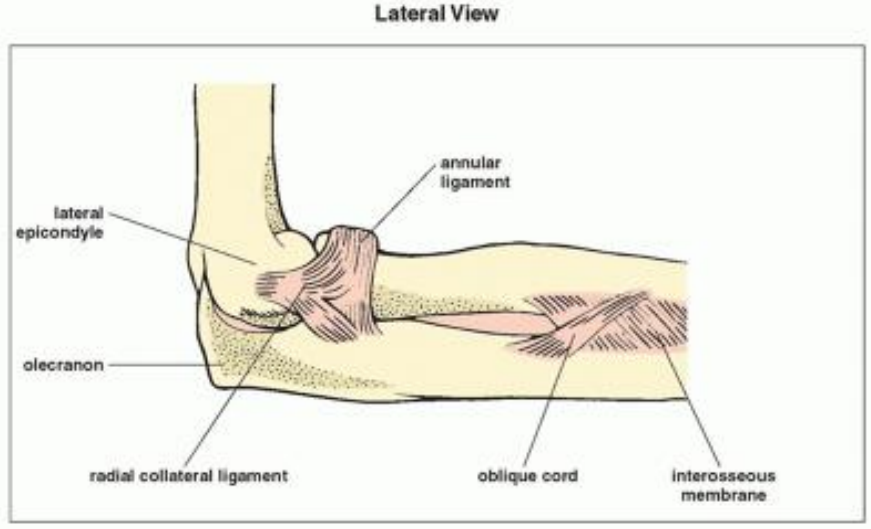

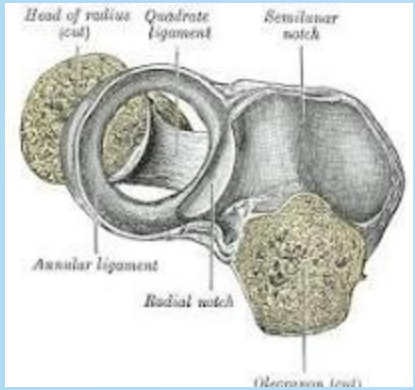



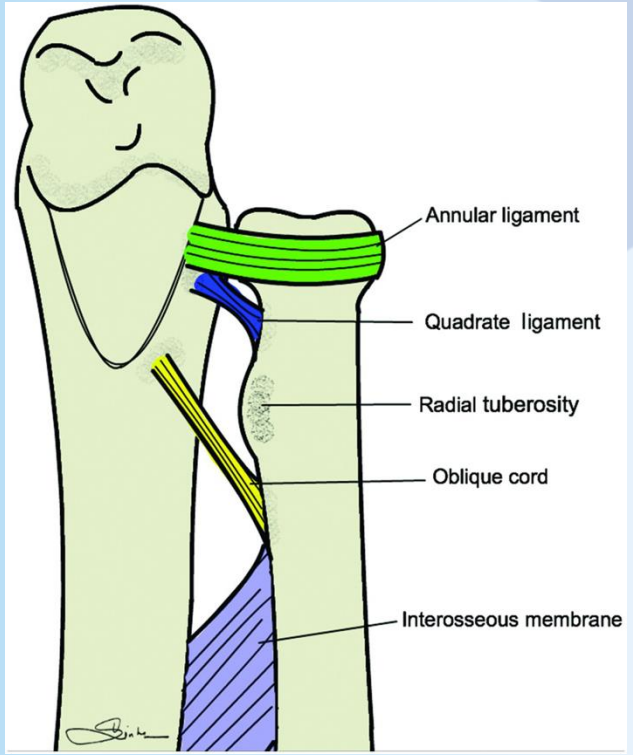

The Elbow joint: Ligaments & osteology Pt.2

- Lateral collateral ligament: annular ligament, ulnar collateral ligament (humerus to ulna), radial collateral ligament (humerus to radius)
- Medial collateral ligament: three bands, posterior oblique and anterior. It is fan shaped. Starts at the level of the lateral epicondyle of the humerus and the coronoid process of the ulna.
- Notable osteology: (Radius) head, neck, radial tuberosity, styloid process, interosseous border, anterior surface, anterior margin. (Ulna) olecranon, trochlear notch, coronoid process, radial notch, supinator crest, supinator fossa, interosseous border, styloid process

Elbow Joint - YouTube
https://www.youtube.com/shorts/nsptRdbY1qk?feature=share



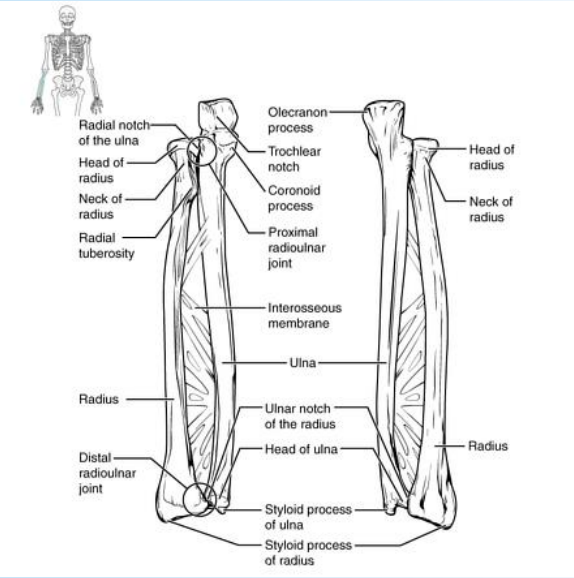

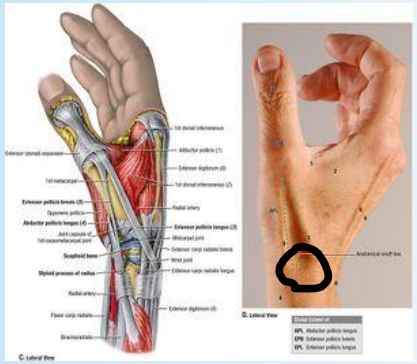

Muscles involved in elbow joint & pronator and supinator muscle(s)

- Pronator teres
- Pronator quadratus
- Biceps brachii
- Triceps

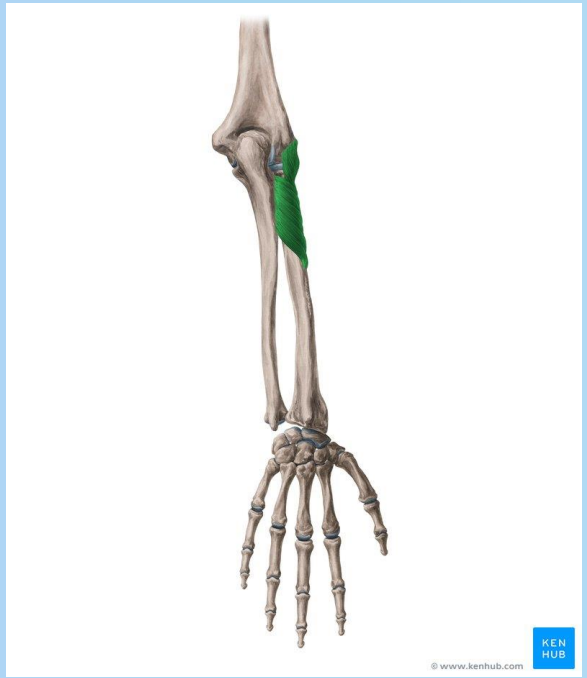

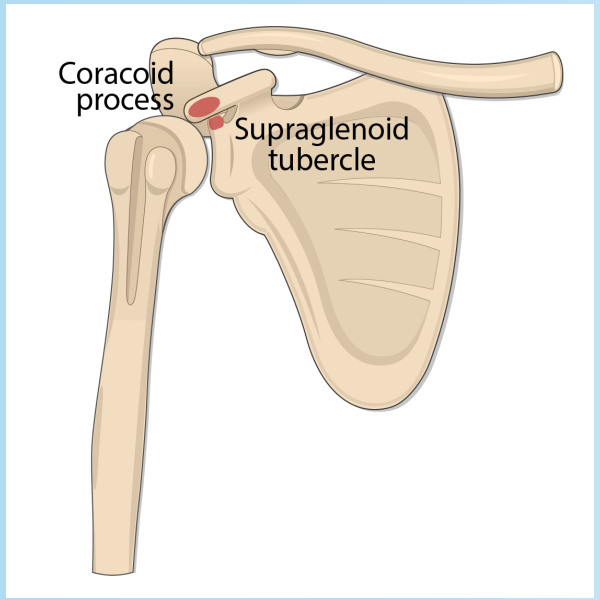

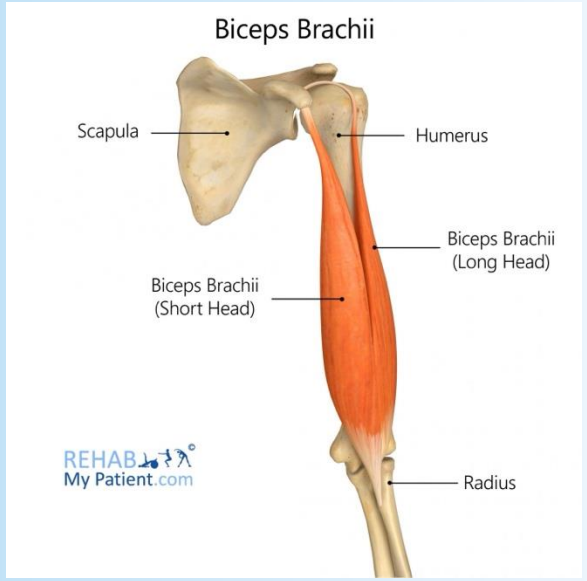

Pronation = palms point down
Supination = make palms point up

sUPination because your palms are pointing UP

studyaid

Muscles involved in elbow joint & pronator and supinator muscle(s) pt.2





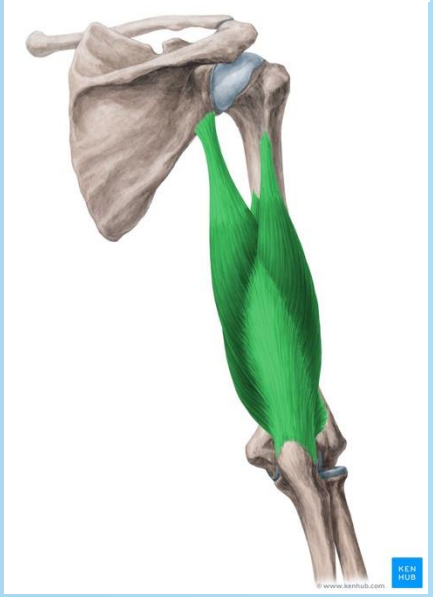

Muscle	Origin	Insertion	Nerve	Action
Coracobrachialis	Coracoid process	Middle third of medial surface of humerus	Musculocutaneous	Flexes and adducts arm
Biceps brachii	Long head, supraglenoid tubercle; short head, coracoid process	Radial tuberosity of radius	Musculocutaneous	Flexes arm and forearm, supinates forearm
Brachialis	Lower anterior surface of humerus	Coronoid process of ulna and ulnar tuberosity	Musculocutaneous	Flexes forearm
Triceps	Long head, infraglenoid tubercle; lateral head, superior to radial groove of humerus; medial head, inferior to radial groove	Posterior surface of olecranon process of ulna	Radial	Extends forearm
Anconeus	Lateral epicondyle of humerus	Olecranon and upper posterior surface of ulna	Radial	Extends forearm
Supinator	Lateral epicondyle, radial collateral and annular ligaments, supinator fossa and crest of ulna	Lateral side of upper part of radius	Radial	Supinates forearm

Muscle	Origin	Insertion	Nerve	Action
Pronator teres	Medial epicondyle and coronoid process of ulna	Middle of lateral side of radius	Median	Pronates and flexes forearm
Flexor carpi radialis	Medial epicondyle of humerus	Bases of second and third metacarpals	Median	Flexes forearm, flexes and abducts hand
Palmaris longus	Medial epicondyle of humerus	Flexor retinaculum, palmar aponeurosis	Median	Flexes forearm and hand
Flexor carpi ulnaris	Medial epicondyle (humeral head), medial olecranon, and posterior border of ulna (ulnar head)	Pisiform, hook of hamate, and base of fifth metacarpal	Ulnar	Flexes forearm, flexes and adducts hand
Flexor digitorum superficialis	Medial epicondyle, coronoid process, oblique line of radius	Middle phalanges of finger	Median	Flexes proximal interphalangeal joints, flexes hand and forearm
Flexor digitorum profundus	Anteromedial surface of ulna, interosseous membrane	Bases of distal phalanges of fingers	Ulnar and median	Flexes distal interphalangeal joints and hand
Flexor pollicis longus	Anterior surface of radius, interosseous membrane, and coronoid process	Base of distal phalanx of thumb	Median	Flexes thumb
Pronator quadratus	Anterior surface of distal ulna	Anterior surface of distal radius	Median	Pronates forearm

studyaid

Q1. What is the origin and insertion of the medial collateral ligament

A. Coronoid process of the ulna & Radial tuberosity of the radius
B. Medial epicondyle of the humerus & Coronoid process of the ulna
C. Olecranon of the ulna & lateral border of the trochlea

studyaid

Q1. What is the origin and insertion of the medial collateral ligament

A. Coronoid process of the ulna & Radial tuberosity of the radius
B. Medial epicondyle of the humerus & Coronoid process of the ulna
C. Olecranon of the ulna & lateral border of the trochlea

studyaid

The annular ligament:

A. Is the ligament sheath in between the radius and ulna
B. Lies at a bit of an angle going from the radius to the ulna and providing extra support
C. The ligament encircles around the radius starting on the ulna

studyaid

The annular ligament:

A. Is the ligament sheath in between the radius and ulna
B. Lies at a bit of an angle going from the radius to the ulna and providing extra support
C. The ligament encircles around the radius starting on the ulna

studyaid

Now we go to.....

The wrist joint!!



Wrist bones: learn them like the back of your HAND

- Some Lovers Try Positions That They Can't Handle
- Scaphoid Lunate Triquetrum Pisiform Trapezoid Trapezium Capitate Hamate
- Divided into two rows, proximal and distal rows. Proximal row consists of scaphoid, lunate, triquetrum and/or pisiform. All except the pisiform make contact with the proximal row.

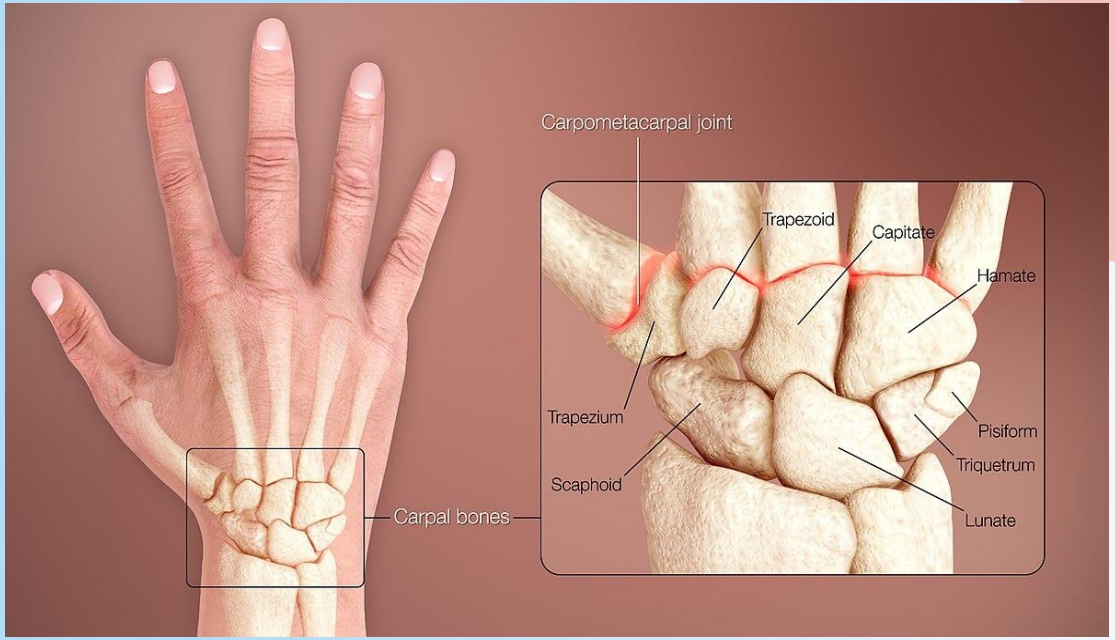

- Scaphoid, bone most often dislocated in case of falling on an outstretched hand. You fall = get a scab on your hand. Scab sounds like scaphoid. Tenderness of your anatomical snuffbox.

studyaid

Wrist bones: the Sequel

- Pisiform- an outlier? Sesamoid rounded bone embedded in a muscle called the flexor carpi ulnaris. Provides extra stability and less wear + tear. You can feel it on your pinky side. Best buds with triquetrum
- Lunate: bone looks like a half moon?
- Capitate, someone who wears a cap wears it on their head which is at the center of their body, capitate is at the center of all the wrist bones
- Last two, trapezoiD & trapeziuM. D comes before M in the alphabet, trapezoid comes before trapezium in relation to the wrist bones

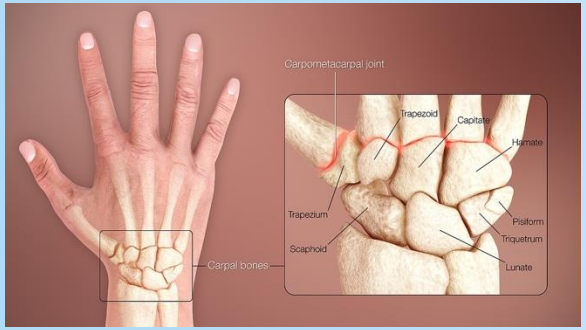

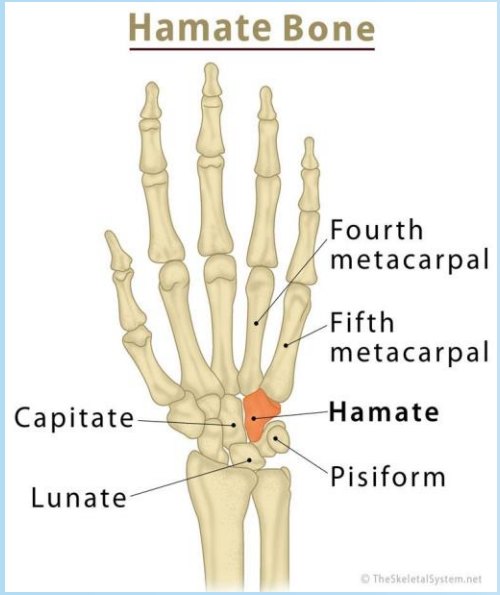



Joints of the wrist and hand

- All joints
  - Radiocarpal: between radius & proximal row of carpal bones. Does flexion, extension & adduction + adduction. Synovial joint (remember what we said about synovial joints – they have cartilage)
  - Carpometacarpal joint – between carpal bones and metacarpals, five joints, for every metacarpal. The firsth carpometacarpal joint has the most movement.
  - Metacarpophalangeal joints: between metacarpals and phalanges, allow for extension, flexion as well as slight adduction + abduction
  - Interphalangeal joints: proximal and distal. You can feel where these joints are from the lines on your skin. Proximal only has slight flexion and extension and distal has even less



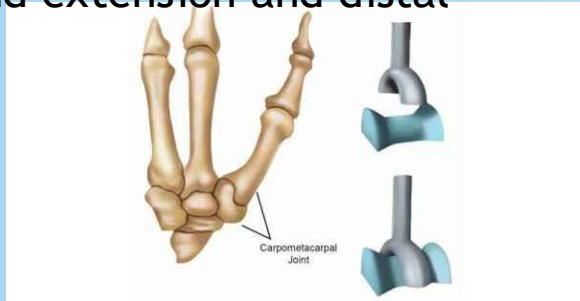

Notable nerves: Medial, radial ulnar

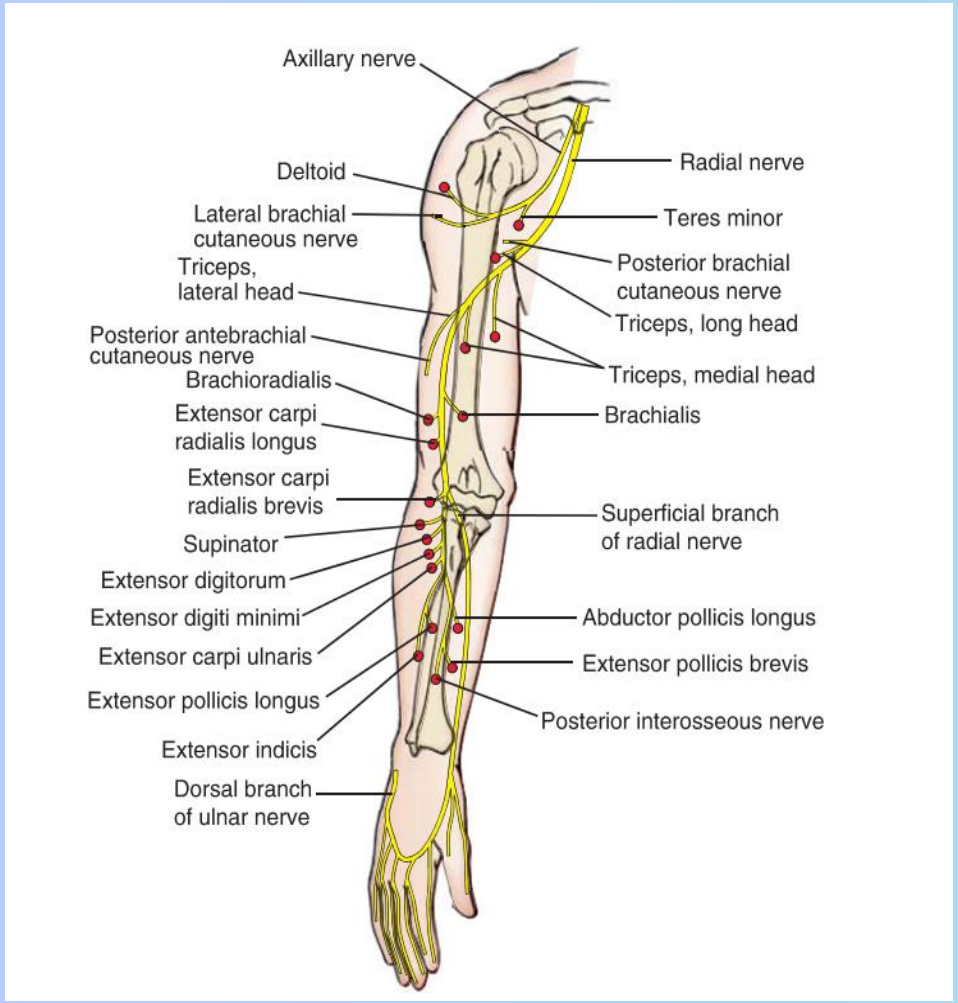

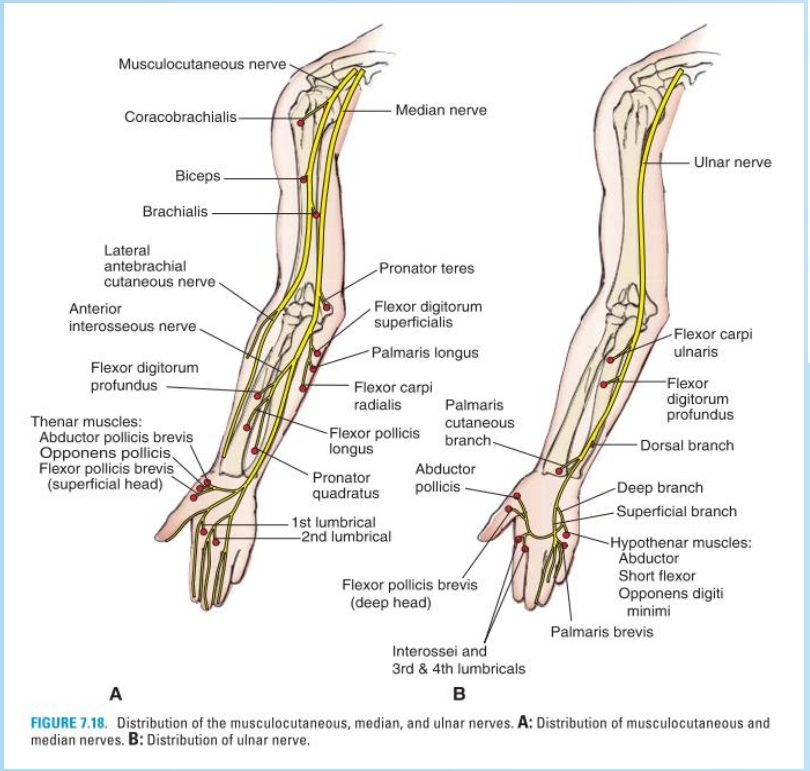

FIGURE 7.18. Distribution of the musculocutaneous, median, and ulnar nerves. **A:** Distribution of musculocutaneous and median nerves. **B:** Distribution of ulnar nerve.

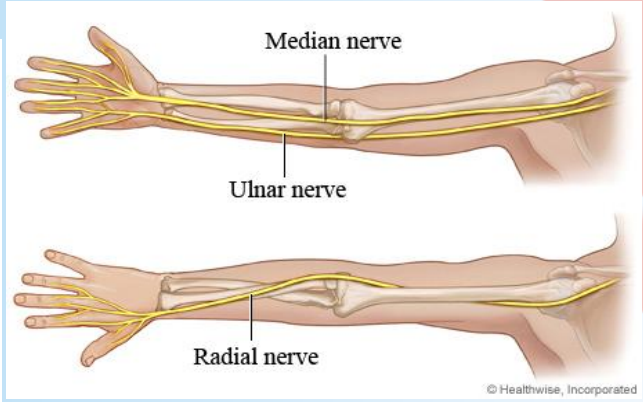

Carpal tunnel, lets talk about it

- Compression of the median nerve. Theres a lot of different bones, ligaments, muscles at the level of your wrist. Therefore its really easy for your nerve to get pinched.
- Tingling, numbness, burning of your thumb, half of the ring, middle index finger which are all supplied by the median nerve
- Floor is made of the carpal arch, all the bones that were mentioned, there are nine flexor tendons, the roof is made up of the flexor retinaculum and lastly theres the median nerve.
- Caused by inflammation of nearby tendons and tissues --> edema --> less space for the median nerve
- In severe cases the thenar muscles can atrophy

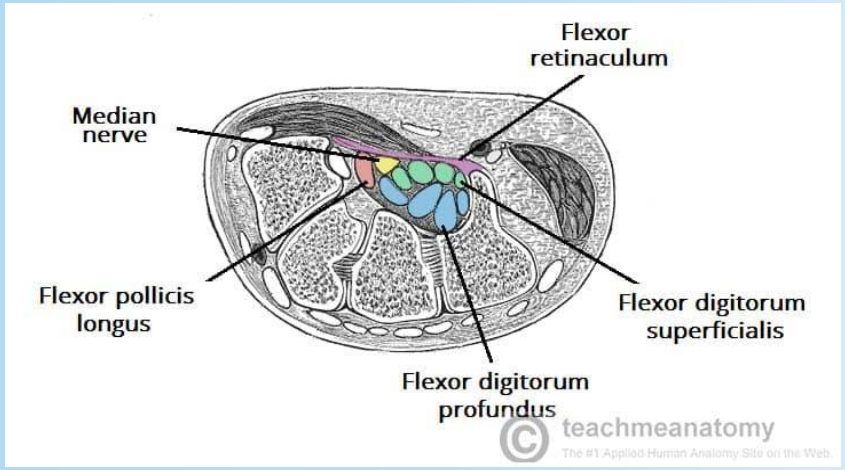

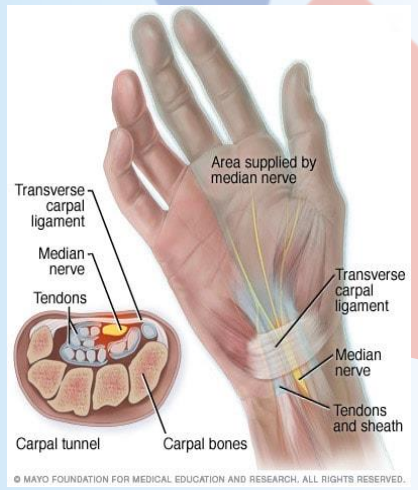

Muscle	Origin	Insertion	Nerve	Action
Abductor pollicis brevis	Flexor retinaculum, scaphoid, trapezium	Lateral side of base of proximal phalanx of thumb	Median	Abducts thumb
Flexor pollicis brevis	Flexor retinaculum and trapezium	Base of proximal phalanx of thumb	Median	Flexes thumb
Opponens pollicis	Flexor retinaculum and trapezium	Lateral side of first metacarpal	Median	Opposes thumb to other digits
Adductor pollicis	Capitate and bases of second and third metacarpals (oblique head), palmar surface of third metacarpal (transverse head)	Medial side of base of proximal phalanx of the thumb	Ulnar	Adducts thumb
Palmaris brevis	Medial side of flexor retinaculum, palmar aponeurosis	Skin of medial side of palm	Ulnar	Wrinkles skin on medial side of palm
Abductor digiti minimi	Pisiform and tendon of flexor carpi ulnaris	Medial side of base of proximal phalanx of little finger	Ulnar	Abducts little finger
Flexor digiti minimi brevis	Flexor retinaculum and hook of hamate	Medial side of base of proximal phalanx of little finger	Ulnar	Flexes proximal phalanx of little finger

studyaid

Wrist joint: ligaments take it or leave it

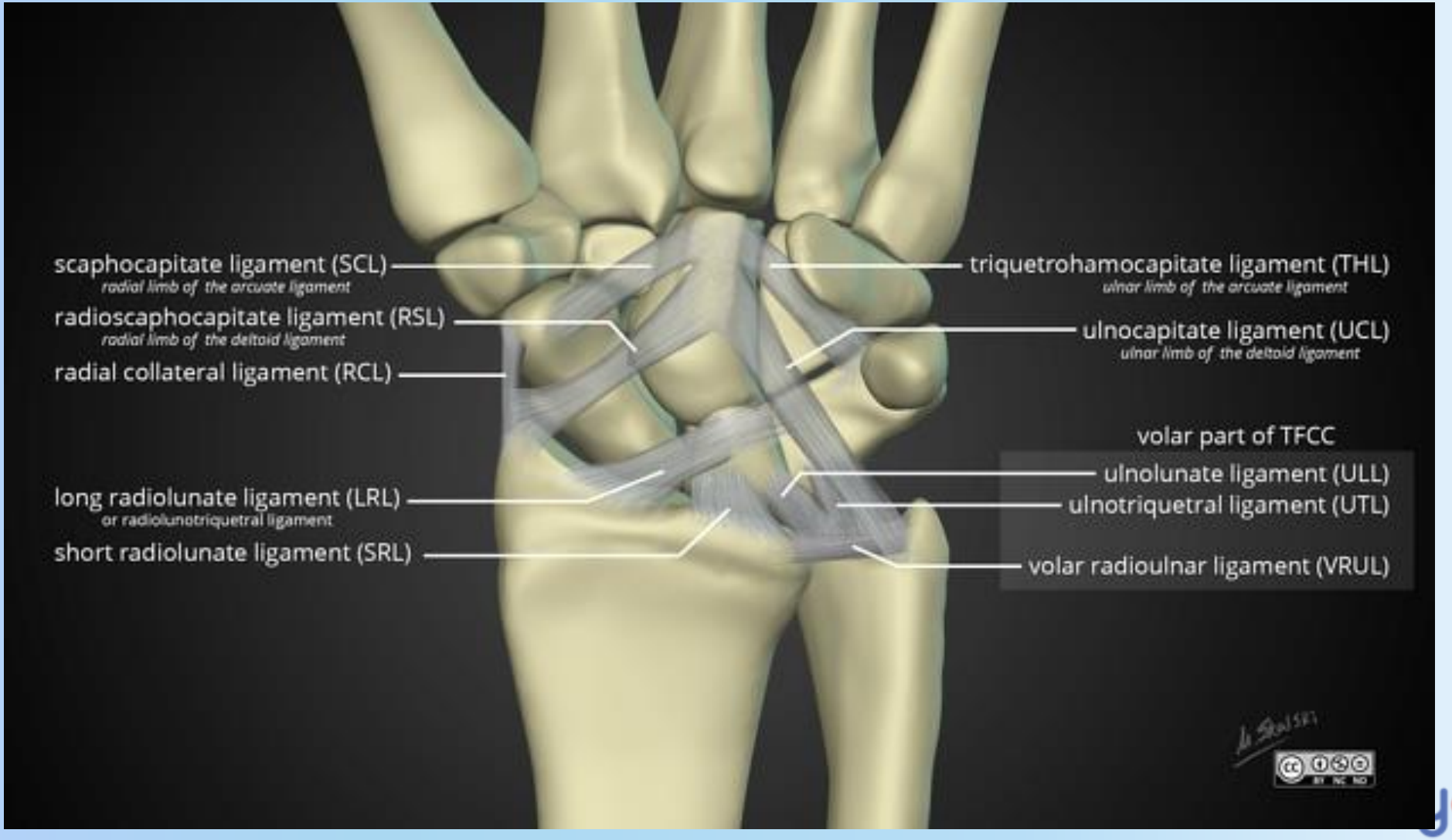

Wrist joint: muscles & extensor compartment - HIGH YIELD

- Extensor tendon compartments - 6 tunnels which transmit the long extensor tendons from the forearm into the hand. Located in the posterior aspect
- Compartment 1: lateral aspect, transmits two tendons: extensor policis brevis and abductor policis longus. Thumb muscles, pollex - thumb
- Compartment 2: Extensor carpi radialis longus and brevis
- Compartment 3: Extensor pollicis longus
- Compartment 4: Extensor digitorum & extensor indicis
- Compartment 5: Extensor digiti minimi
- Compartment 6: Extensor carpi ulnaris

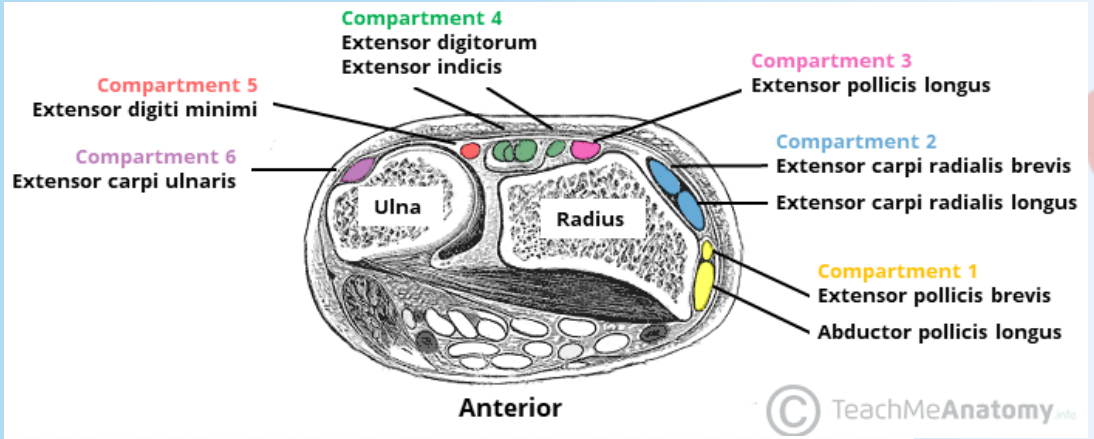

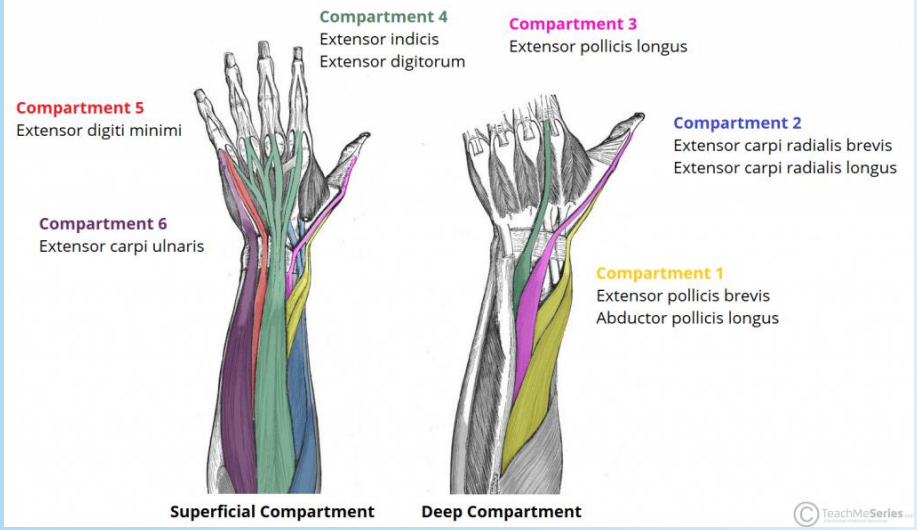

studyaid

Which major nerve of the upper limb passes through the carpal tunnel

A. Radial nerve
B. Median nerve
C. Musculocutaneous nerve

studyaid

Which major nerve of the upper limb passes through the carpal tunnel

A. Radial nerve
B. Median nerve
C. Musculocutaneous nerve

studyaid

A 12 year old boy falls on his hands while skating. Which bone in the proximal row is most likely injured?

A. Scaphoid

B. Triquetrum

C. Pisiform

studyaid

A 12 year old boy falls on his hands while skating. Which bone in the proximal row is most likely injured?

A. Scaphoid

B. Triquetrum

C. Pisiform

studyaid

THANK YOU!!

studyaid