

Cranial Nerves

By: Sayeh Mirshojae

Today's Agenda

- Quick overview of all cranial nerves
- Functional components of cranial nerves
- CN I, V, VII-XII
- Reflexes

CRANIAL NERVES OVERVIEW

	Nerve	Function	Type
I	Olfactory	Smell	Sensory
II	Optic	Vision	Sensory
III	Oculomotor	Eye movement, pupil reflex	Motor, parasympathetic
IV	Trochlear	Eye movement	Motor
V	Trigeminal	Face sensation, mastication	Both
VI	Abducens	Eye movement	Motor
VII	Facial	Facial movement, hearing, taste	Both, parasympathetic
VIII	Vestibulocochlear	Hearing, balance	Sensory
IX	Glossopharyngeal	Taste, sensation, swallowing	Both, parasympathetic
X	Vagus	Movement sensation, abdominal organs	Both, parasympathetic
XI	Accessory	Trapezius, SCM	Motor
XII	Hypoglossal	Tongue movement	Motor

CRANIAL NERVES OVERVIEW

	Nerve	Function	Type
I	Olfactory	Smell	Sensory
II	Optic	Vision	Sensory
III	Oculomotor	Eye movement, pupil reflex	Motor
IV	Trochlear	Eye movement	Motor
V	Trigeminal	Face sensation, mastication	Both
VI	Abducens	Eye movement	Motor
VII	Facial	Facial movement, hearing, taste	Both
VIII	Vestibulocochlear	Hearing, balance	Sensory
IX	Glossopharyngeal	Taste, sensation, swallowing	Both
X	Vagus	Movement sensation, abdominal organs	Both
XI	Accessory	Trapezius, SCM	Motor
XII	Hypoglossal	Tongue movement	Motor

Today's Agenda

- ~~Quick overview of all cranial nerves~~
- Functional components of cranial nerves
- CN I, V, VII-XII
- Reflexes

Functional Components of CN

Functional Component	Type of Information Carried	Cranial Nerves
GSA	Pain, temperature, touch proprioception	V, VII, IX, X
GSE	Motor to skeletal muscle of the eye and tongue	III, IV, VI, XII
GVA	Sensory from visceral organs	VII, IX, X
GVE	Autonomic motor fibers to smooth muscle, cardiac muscle, glands	III, VII, IX, X
SSA	Vision, hearing, equilibrium	II, VIII
SVA	Smell and taste	I, VII, IX, X
SVE or branchial efferent	Motor to skeletal muscles for mastication, facial expression, movement of the pharynx and larynx	V, VII, IX, X, XI

Today's Agenda

- ~~Quick overview of all cranial nerves~~
- ~~Functional components of cranial nerves~~
- CN I, V, VII-XII
- Reflexes

CN I: Olfactory Nerve

Function: Smell

Cranial exit: Cribriform plate of ethmoid bone

Brainstem exit: Telencephalon/cerebrum (olfactory bulb)

Functional Component: SVA



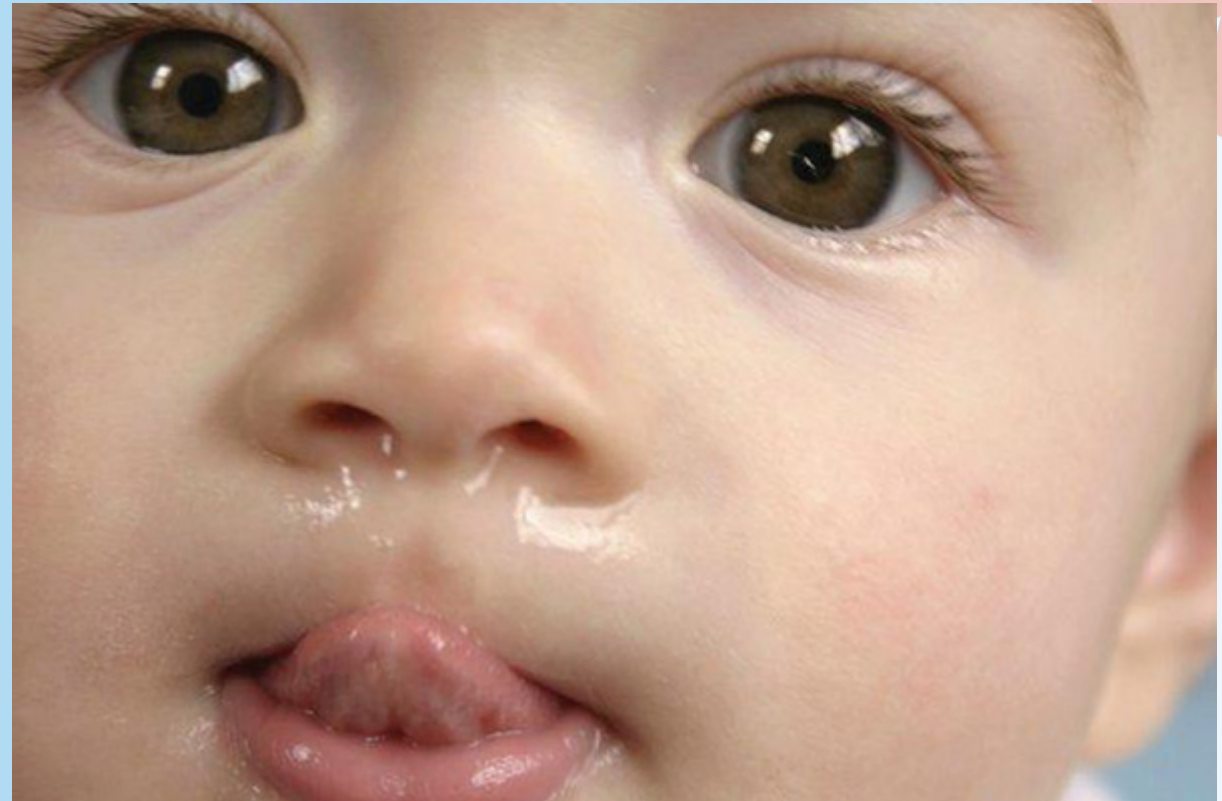CN I: Olfactory Nerve

Effect of nerve injury:

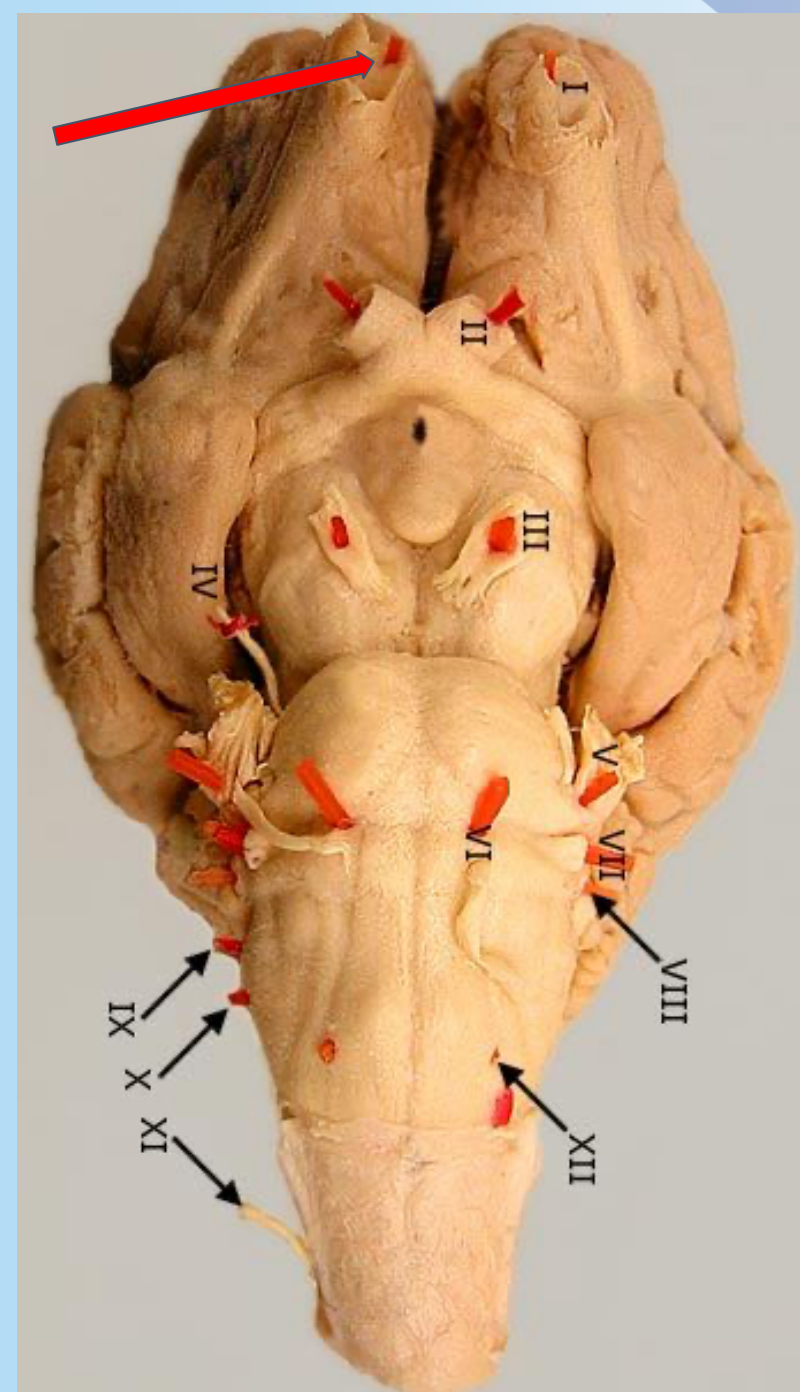
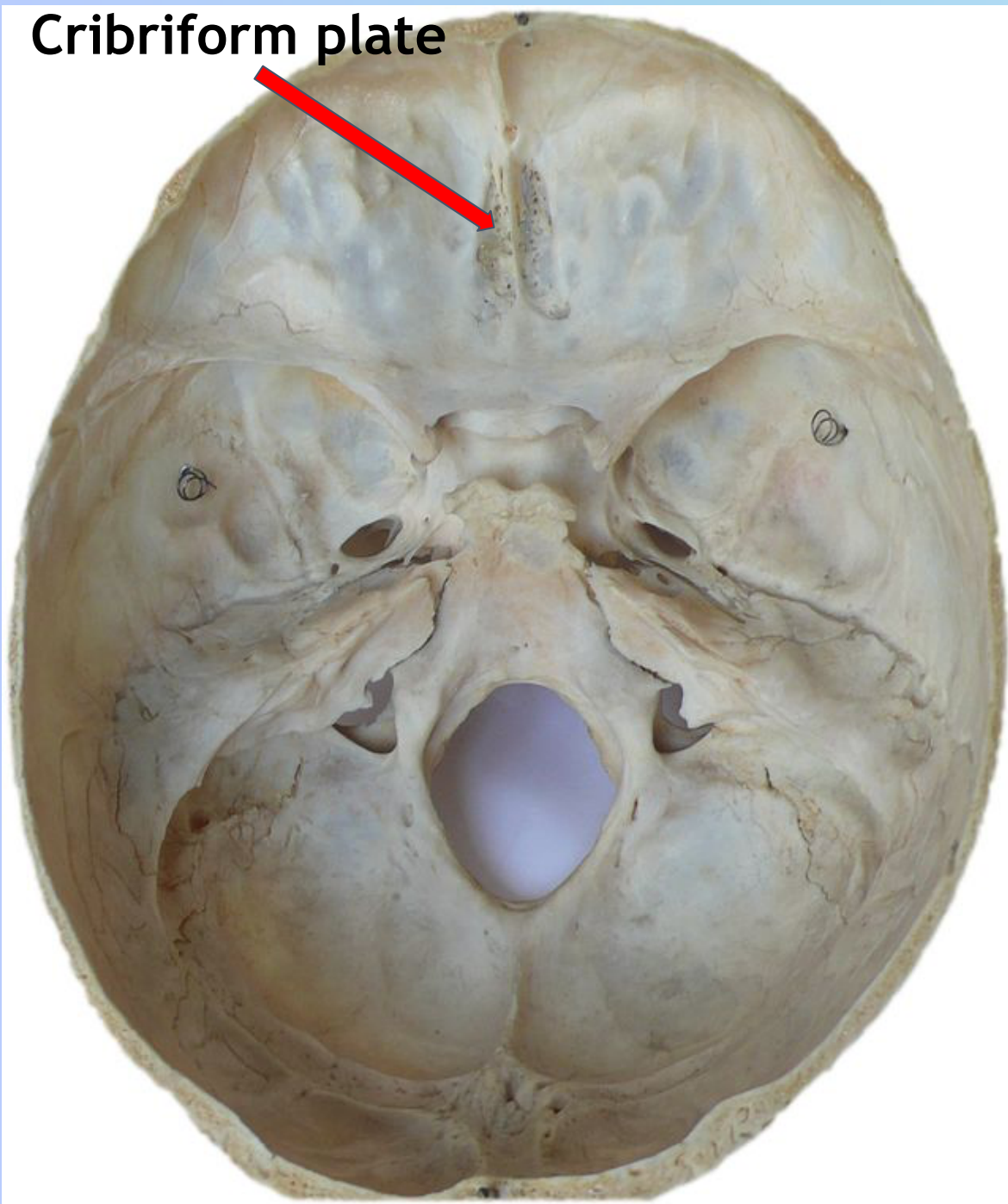
- Loss of smell (anosmia)
- Rhinorrhea (CSF flow through the nose)

Lesion site:

- Fracture of cribriform plate



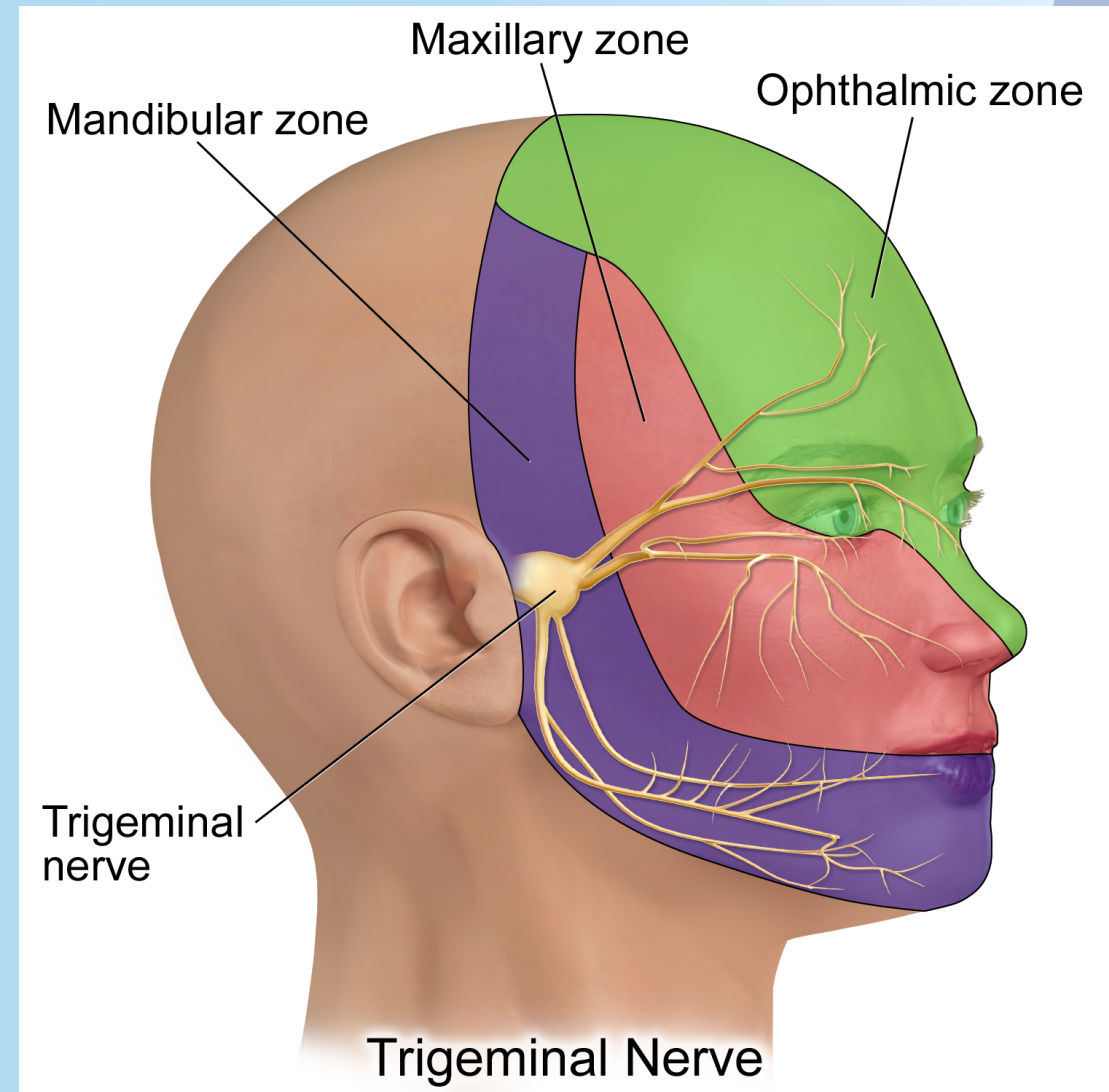
Cribriform plate



CN V: Trigeminal Nerve

Divided into 3 branches:

- V1 ophthalmic (S)
- V2 maxillary (S)
- V3 mandibular (M)



CN V: Trigeminal Nerve

Function:

- V1: Sensory innervation eyeball, tip of nose, skin of face above the eyes
- V2: Sensory innervation palate, paranasal sinuses, maxillary teeth, skin of face between eye and upper lip
- V3: Motor innervation muscles of mastication, mylohyoid, anterior belly of digastric, tensor veli palatini, and tensor tympani muscles

Cranial exit:

- Superior orbital fissure (V1)
- Foramen rotundum (V2)
- Foramen ovale (V3)

Masseter Medial Pterygoid TeMporalis	Moves the mandible UP (closes the mouth)
Lateral Pterygoid	Lowers the mandible (open mouth)

Brainstem exit: Pons anteriorly to the pyramidal eminence

Functional Component: GSA(V1, V2, V3), SVE (V3)

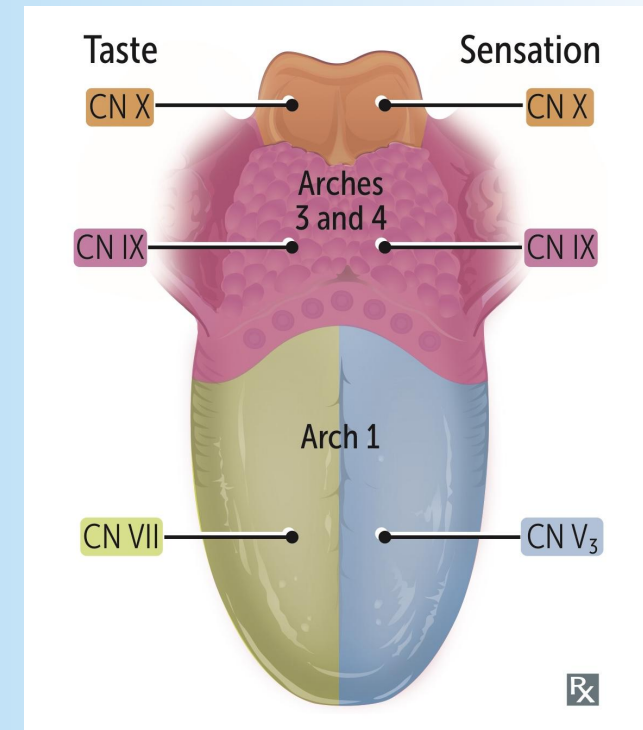
CN V: Trigeminal Nerve

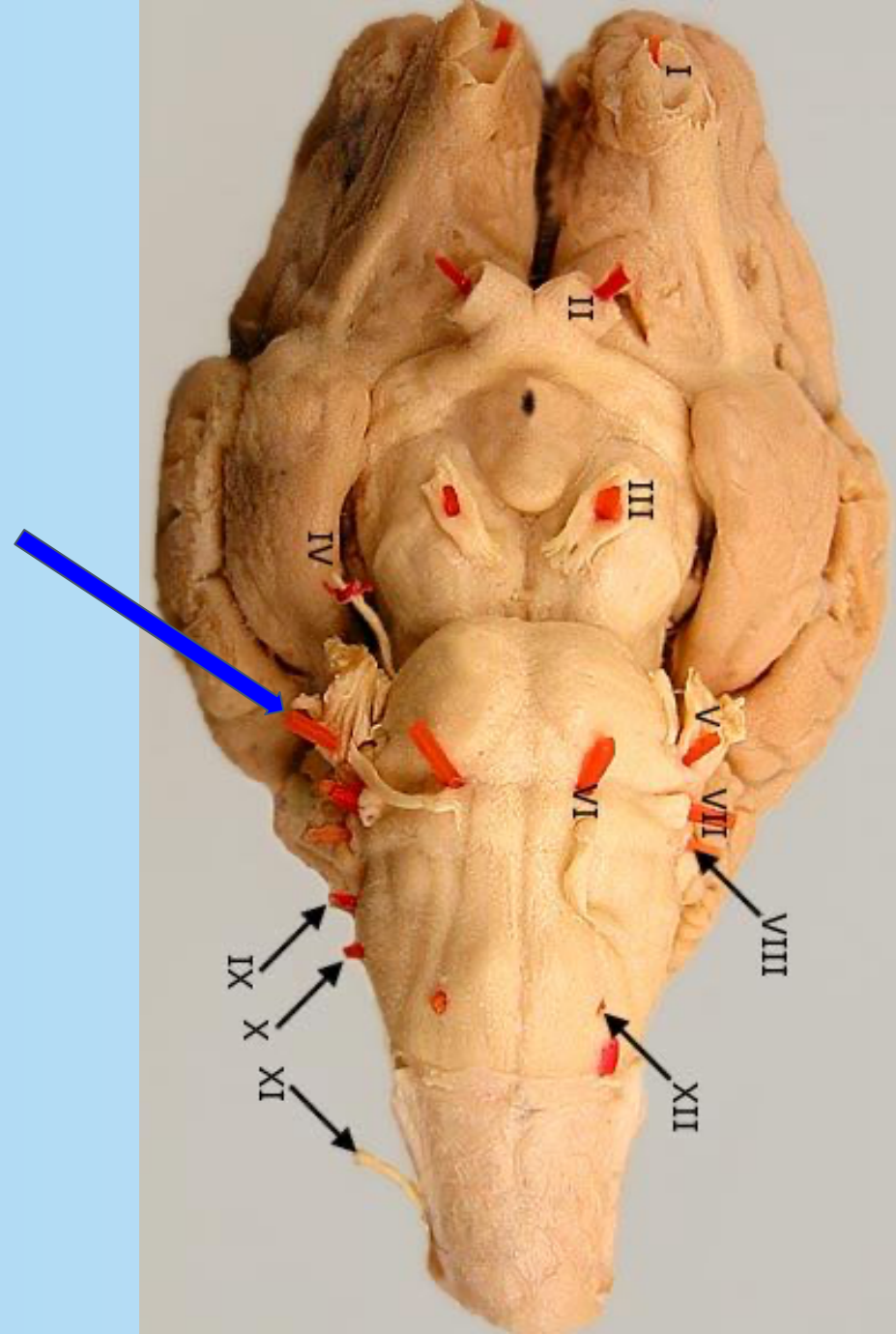
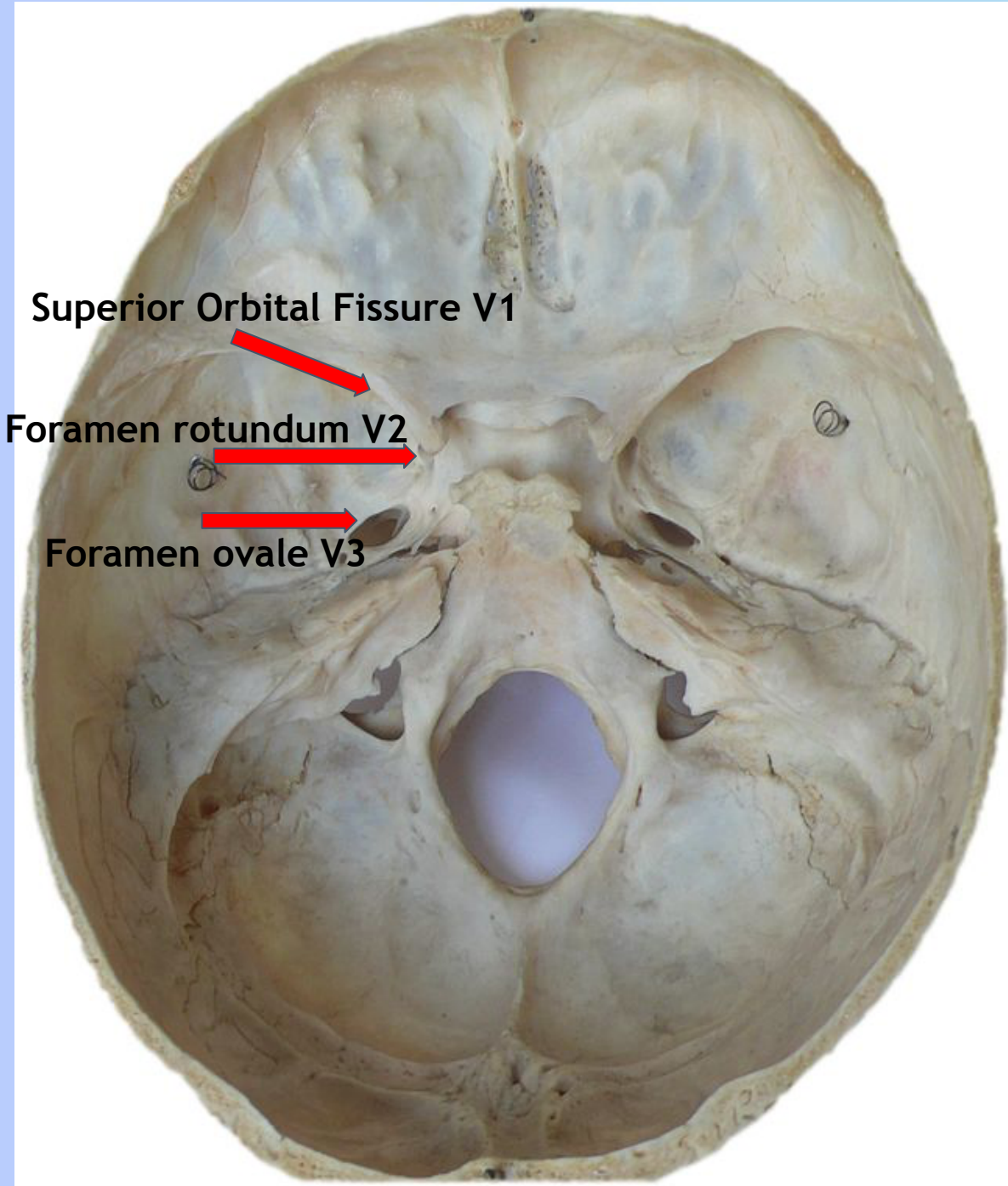
Effect of nerve injury:

- Sensory loss on face
- Loss of mastication
- Jaw deviation toward side of lesion
- Loss of afferent limb of corneal and sneeze reflexes
- Paralysis of tensor tympani leading to hypacusis = partial deafness to low-pitched sounds
- Trigeminal neuralgia

Lesion site:

- Lesion of pons
- Fracture or tumor in region of trigeminal ganglion





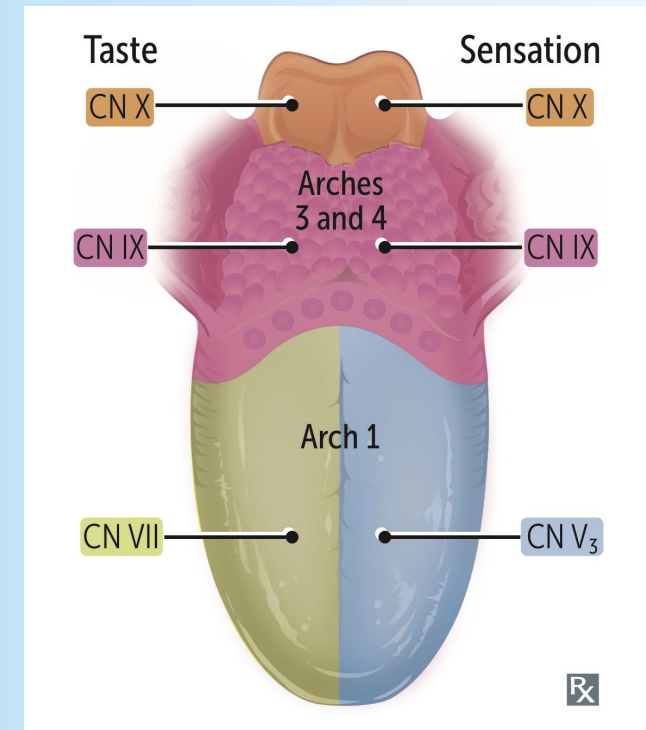
CN VII: Facial Nerve

Function: Muscle of facial expression, posterior belly of digastric, stylohyoid, and stapedius muscle; Lacrimal and salivary secretion; Taste from anterior $\frac{2}{3}$ of tongue and palate; Sensation from palate; Auricle and external acoustic meatus

Cranial exit: Stylomastoid foramen, internal auditory meatus

Brainstem exit: Cerebellopontine angle

Functional Component: GSA, GVA, GVE, SVA, SVE



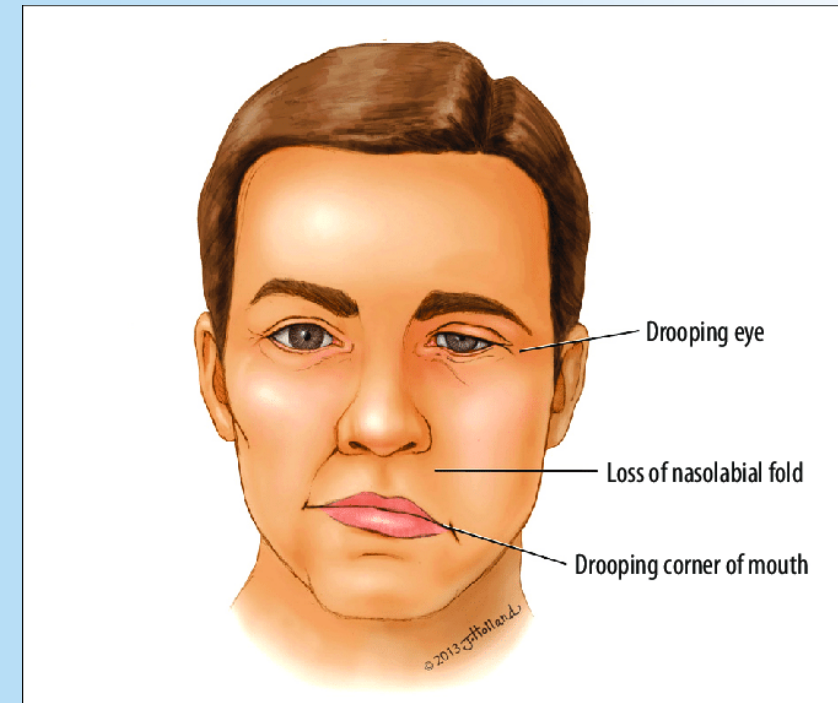
CN VII: Facial Nerve

Effect of nerve injury:

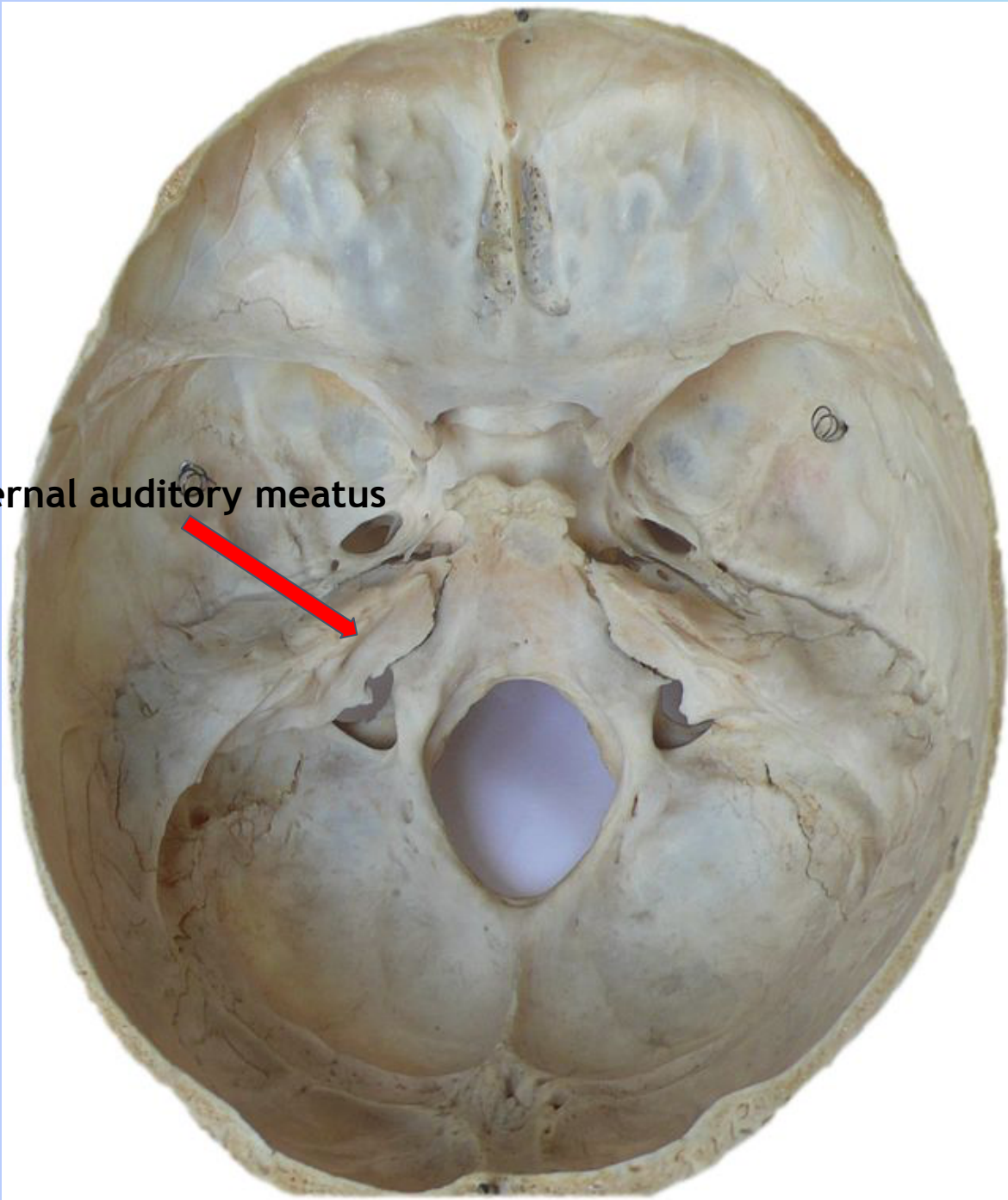
- Facial paralysis (Bell palsy) (upper and lower face)
- Loss of efferent limb of corneal reflex
- Loss of taste to anterior $\frac{2}{3}$ of tongue
- Loss of secretion of lacrimal, submandibular, sublingual, nasal and palatine glands
- Hyperacusis (increased acuity to sound), due to stapedius paralysis

Lesion site:

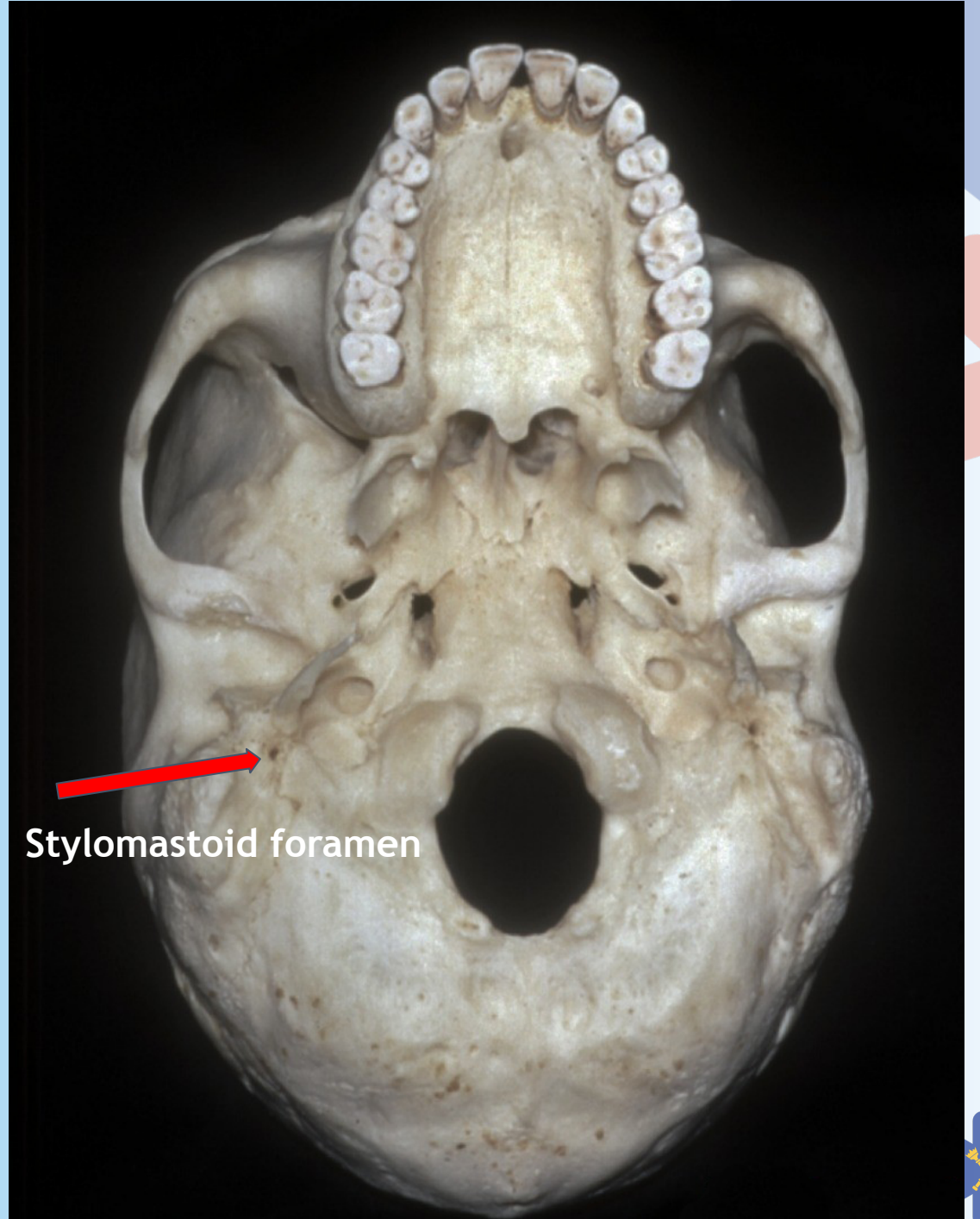

- Lesion of pons
- Injury to internal auditory meatus
- Laceration in parotid region
- Fracture of temporal bone

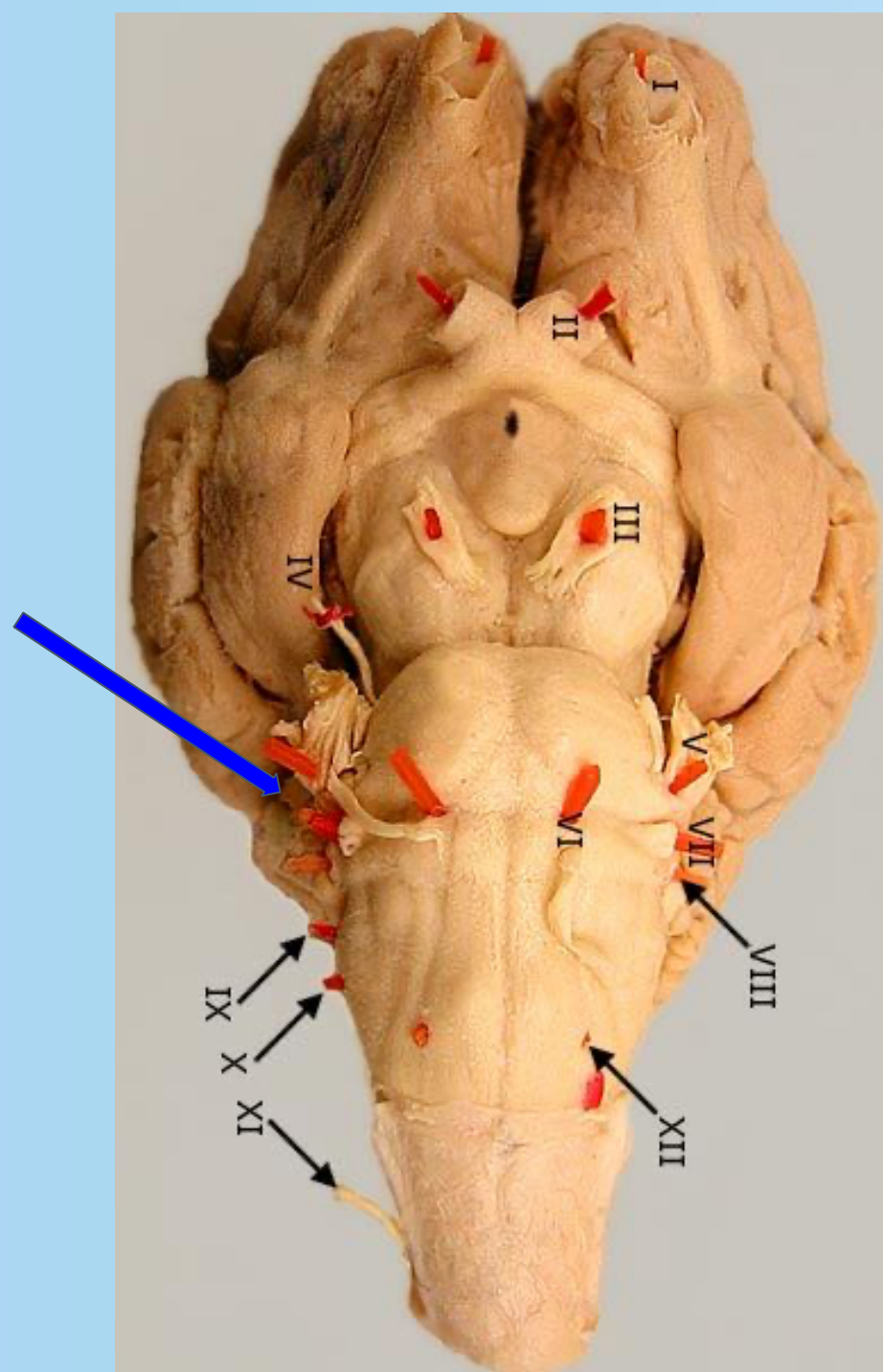


Internal auditory meatus



Stylomastoid foramen





CN VIII: Vestibulocochlear Nerve

Function: Equilibrium, hearing

Cranial exit: Internal auditory meatus

Brainstem exit: Cerebellopontine angle

Functional Component: SSA

CN VIII: Vestibulocochlear Nerve

Effect of nerve injury:

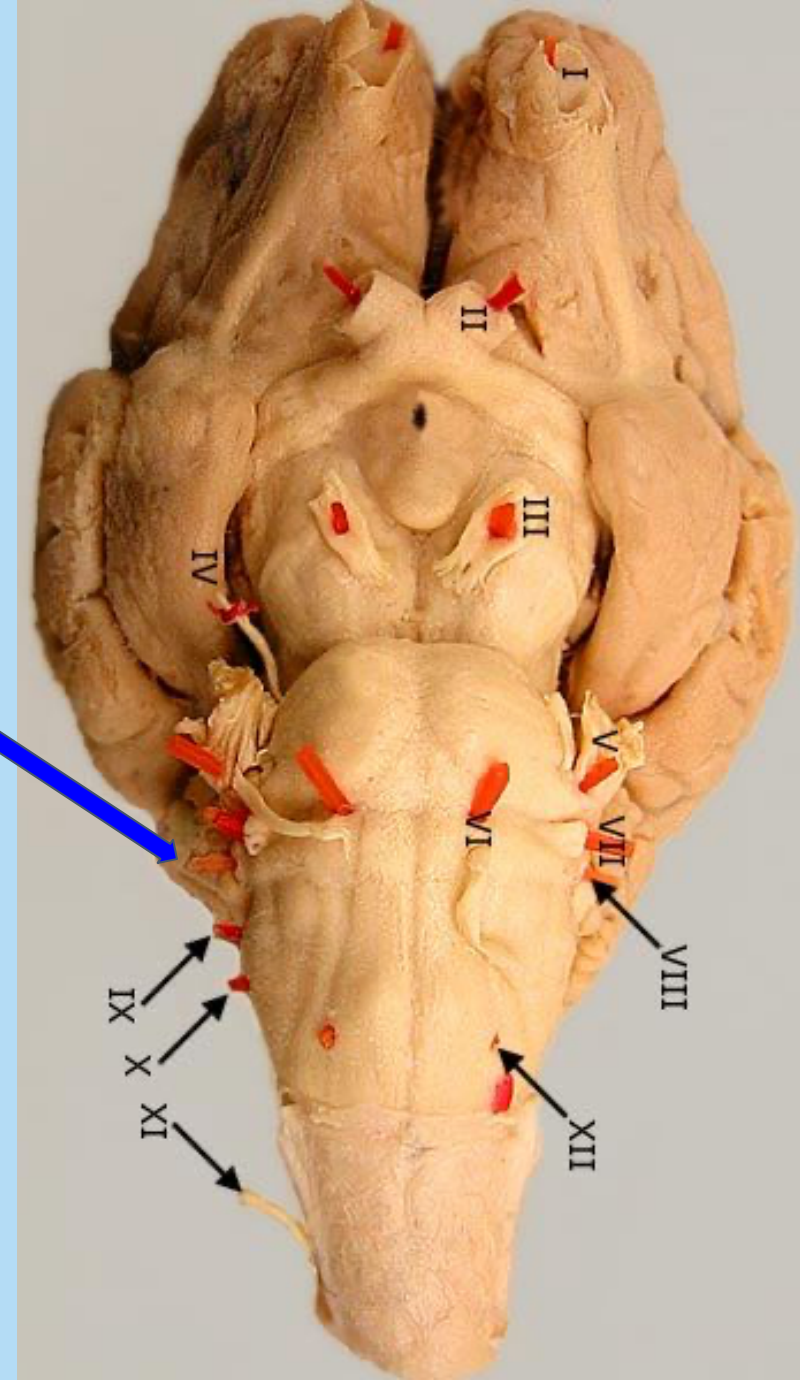
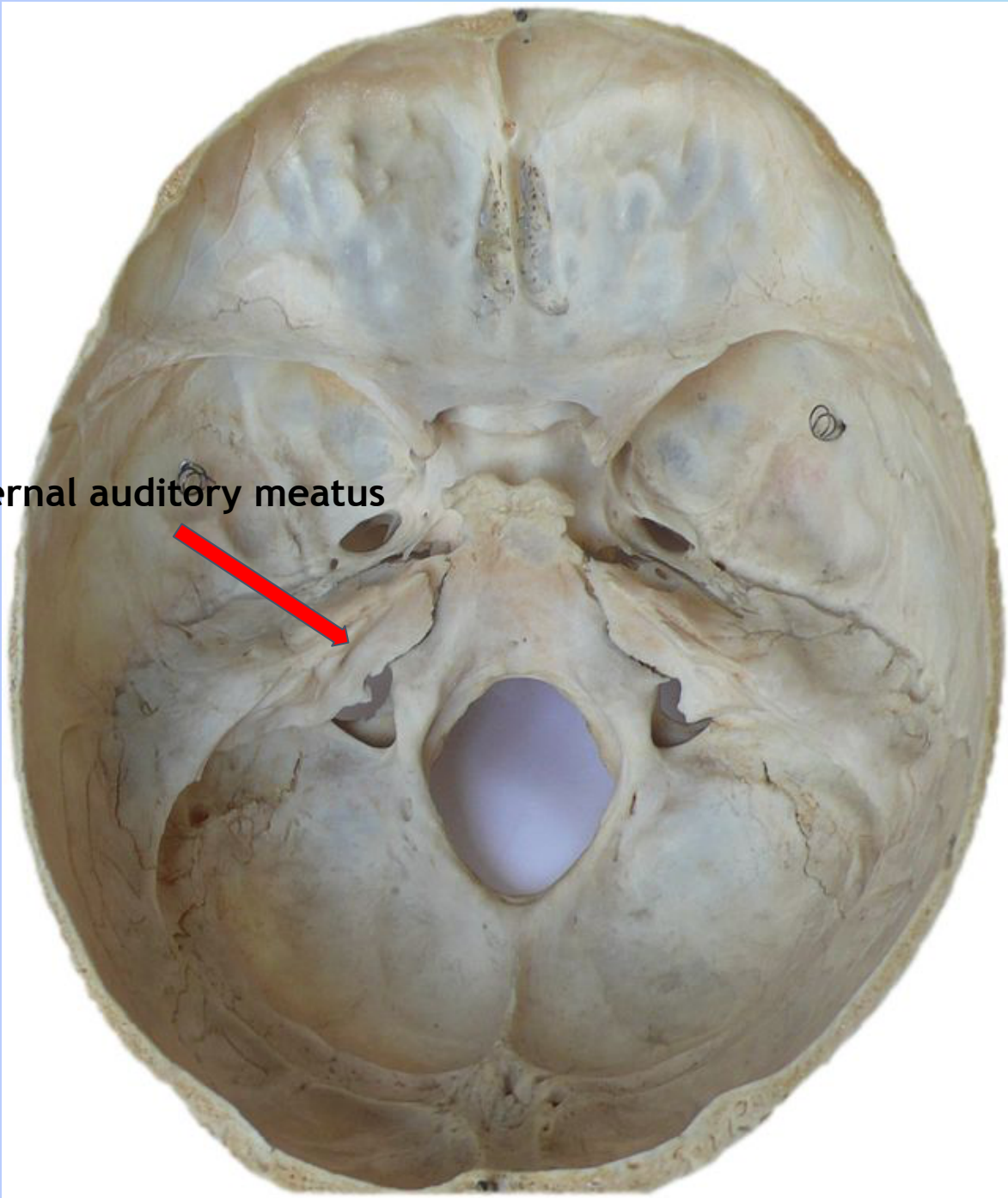
- Loss of hearing
- Loss of balance
- Tinnitus
- Vertigo

Lesion site:

- Tumor in internal auditory meatus
- Tumor at cerebellopontine angle



Internal auditory meatus



CN IX: Glossopharyngeal Nerve

Function: Elevation of pharynx (stylopharyngeus muscle); Secretion of saliva (parotid gland); Carotid sinus and body, tongue, pharynx, and middle ear; Taste from posterior $\frac{1}{3}$ of tongue; External ear.

Cranial exit: Jugular foramen

Brainstem exit: Medulla (postolivary sulcus)

Functional Component: GSA, GVA, GVE, SVA, SVE

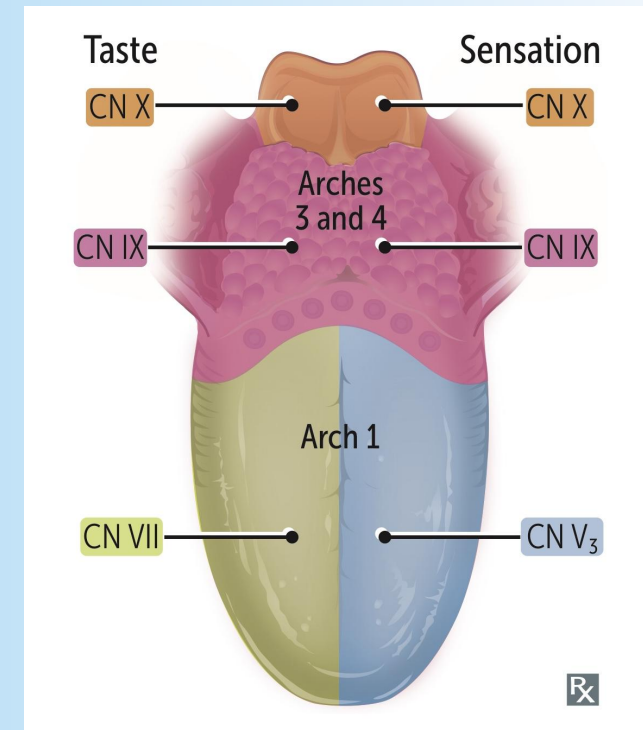
CN IX: Glossopharyngeal Nerve

Effect of nerve injury:

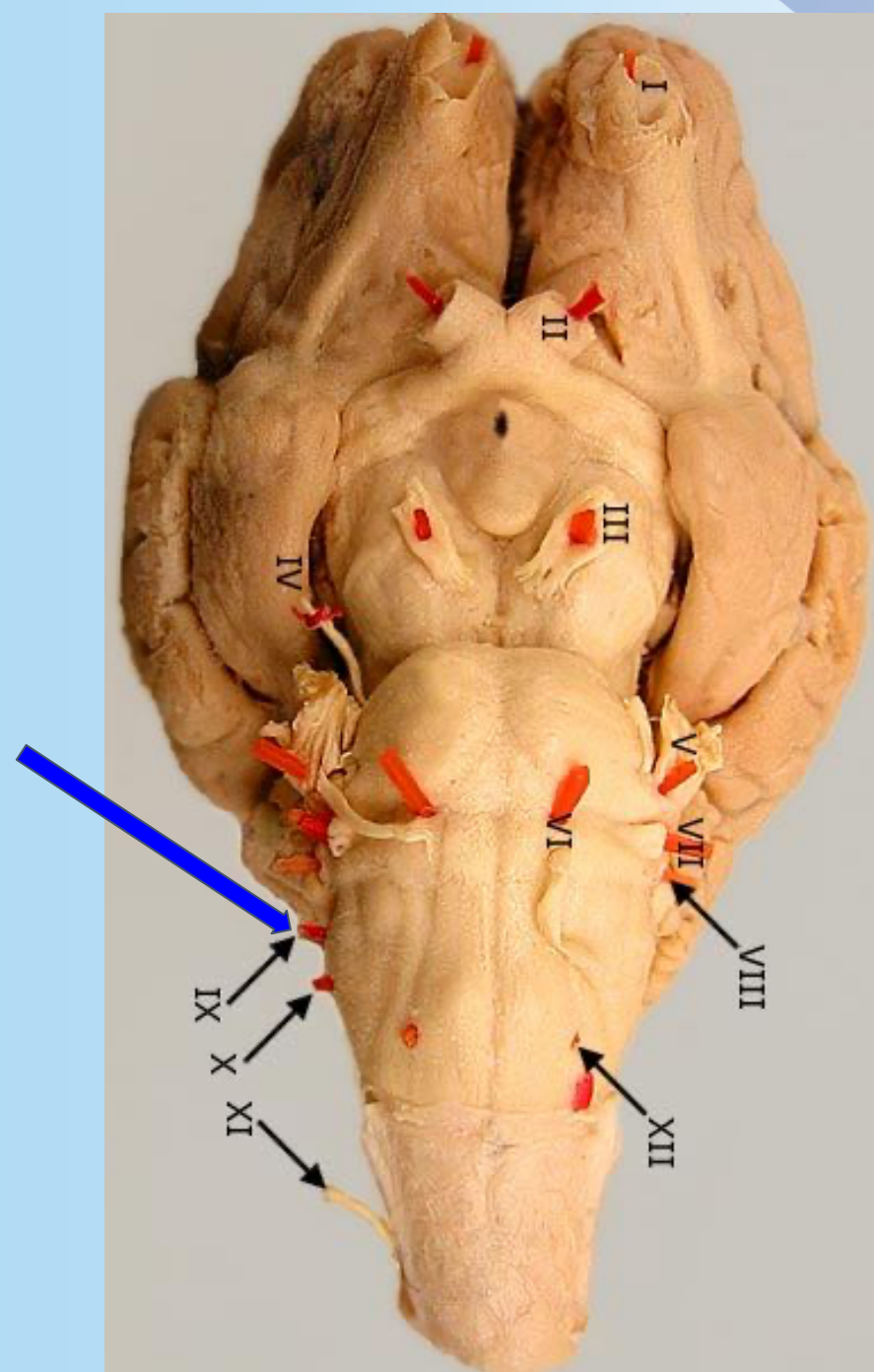
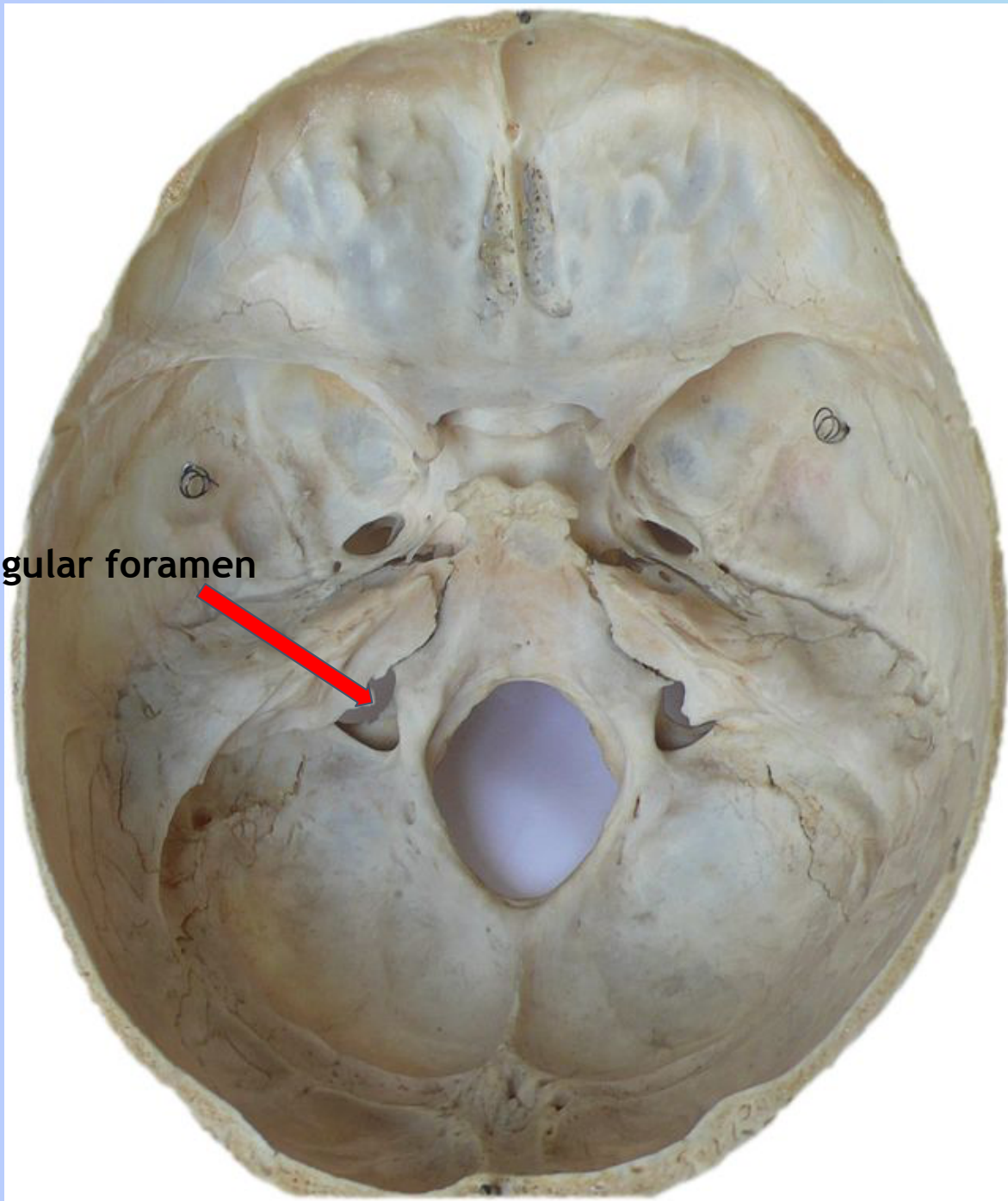
- Loss of taste to posterior 1/3 of tongue
- Loss of receptors in carotid body and sinus
- Loss of parotid gland secretion
- Paralysis of stylopharyngeus muscle
- Loss of afferent limb of gag reflex
- Glossopharyngeal neuralgia

Lesion site:

- Brainstem lesion
- Penetrating neck lesion



Jugular foramen



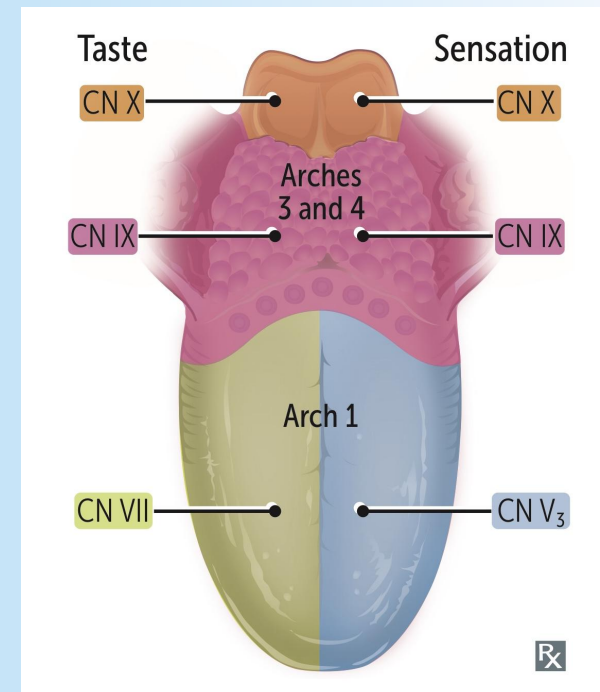
CN X: Vagus Nerve

Function: Muscle of pharynx, larynx, and palate; Smooth muscles and glands in thoracic and abdominal viscera; Sensation in lower pharynx, larynx, trachea, and other viscerae, Taste on epiglottis; Auricle and external acoustic meatus.

Cranial exit: Jugular foramen

Brainstem exit: Medulla (postolivary sulcus)

Functional Component: GSA, GVA, GVE, SVA, SVE



CN X: Vagus Nerve


Effect of nerve injury:

- Loss of efferent limbs, gag, sneeze, and both limbs of cough reflex
- Deviation of uvula toward normal side
- Vocal cord paralysis (left recurrent laryngeal nerve)
 - Thyroidectomy
- Paralysis of palate, pharynx, and larynx
- Loss of receptors in aortic body and arch

Lesion site:

- Brainstem lesion
- Penetrating neck injury
- Skull base fracture

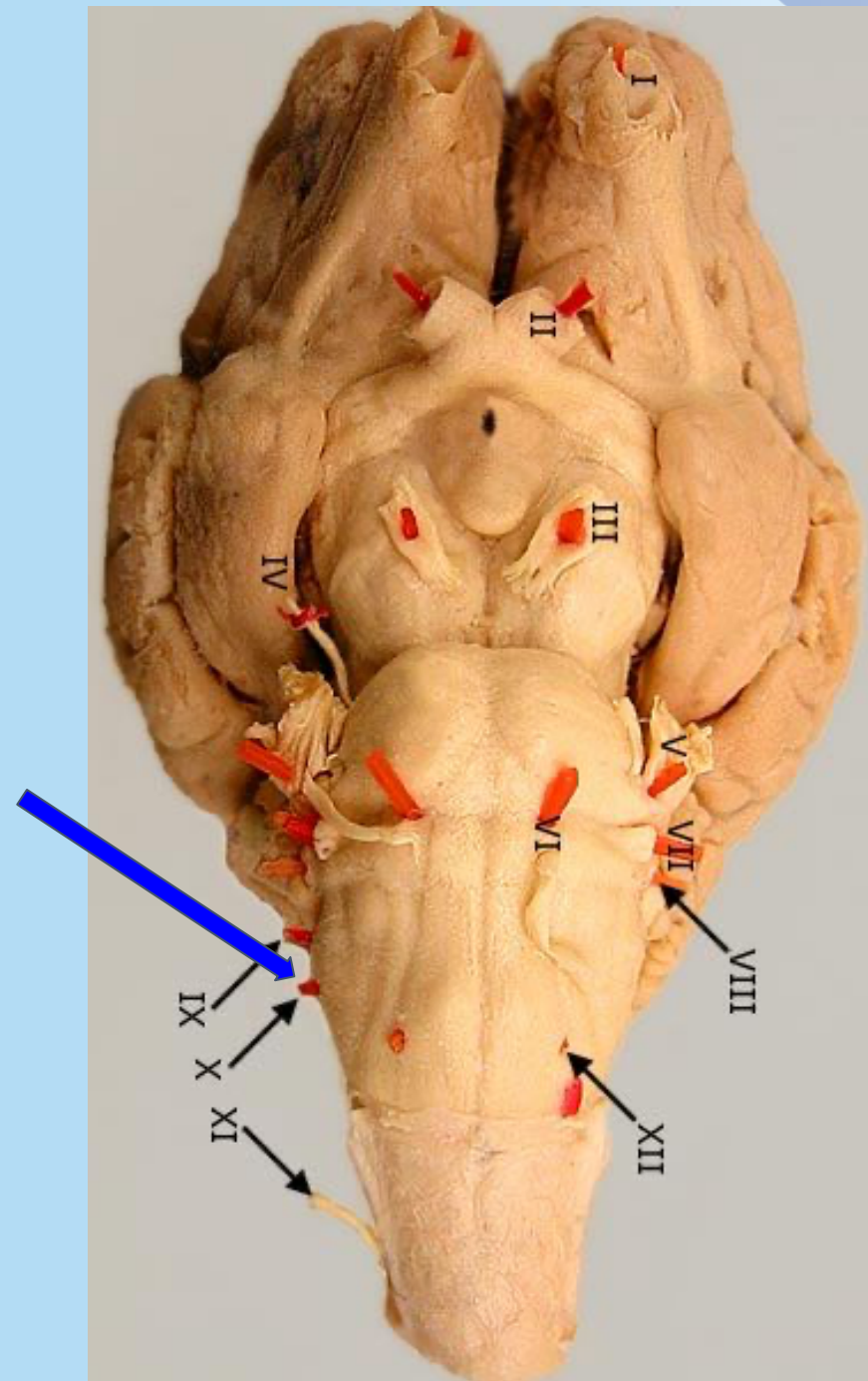
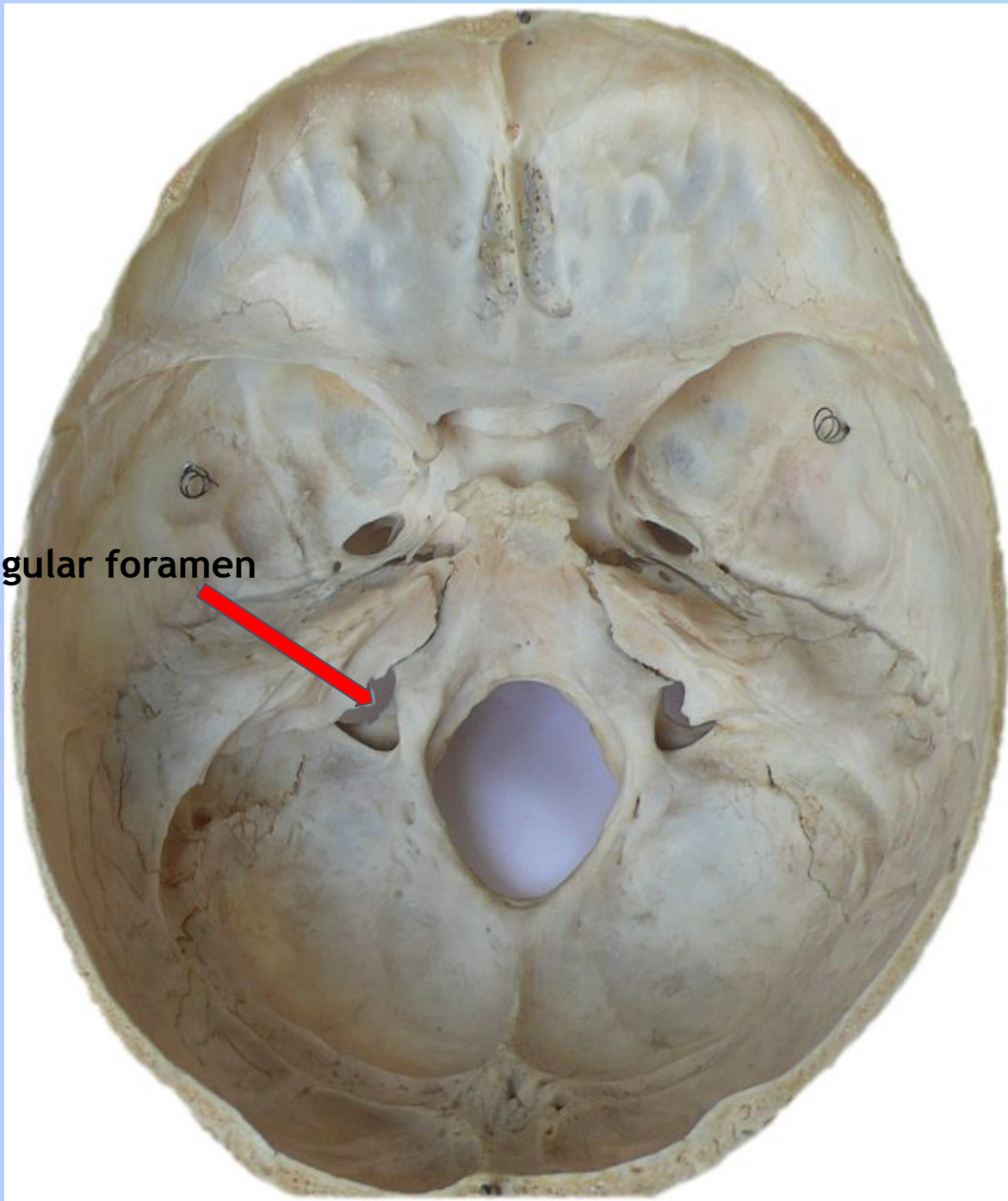
“that must be the uvula”



“oh, so its a *girl* house”



Jugular foramen



CN XI: Accessory Nerve

Function: SCM and trapezius muscle

Cranial exit: Jugular foramen

Brainstem exit: Cranial - Medulla (postolivary sulcus)

Spinal - Passes through the foramen magnum and joins the cranial root

Functional Component: SVE

CN XI: Accessory Nerve

Effect of nerve injury:

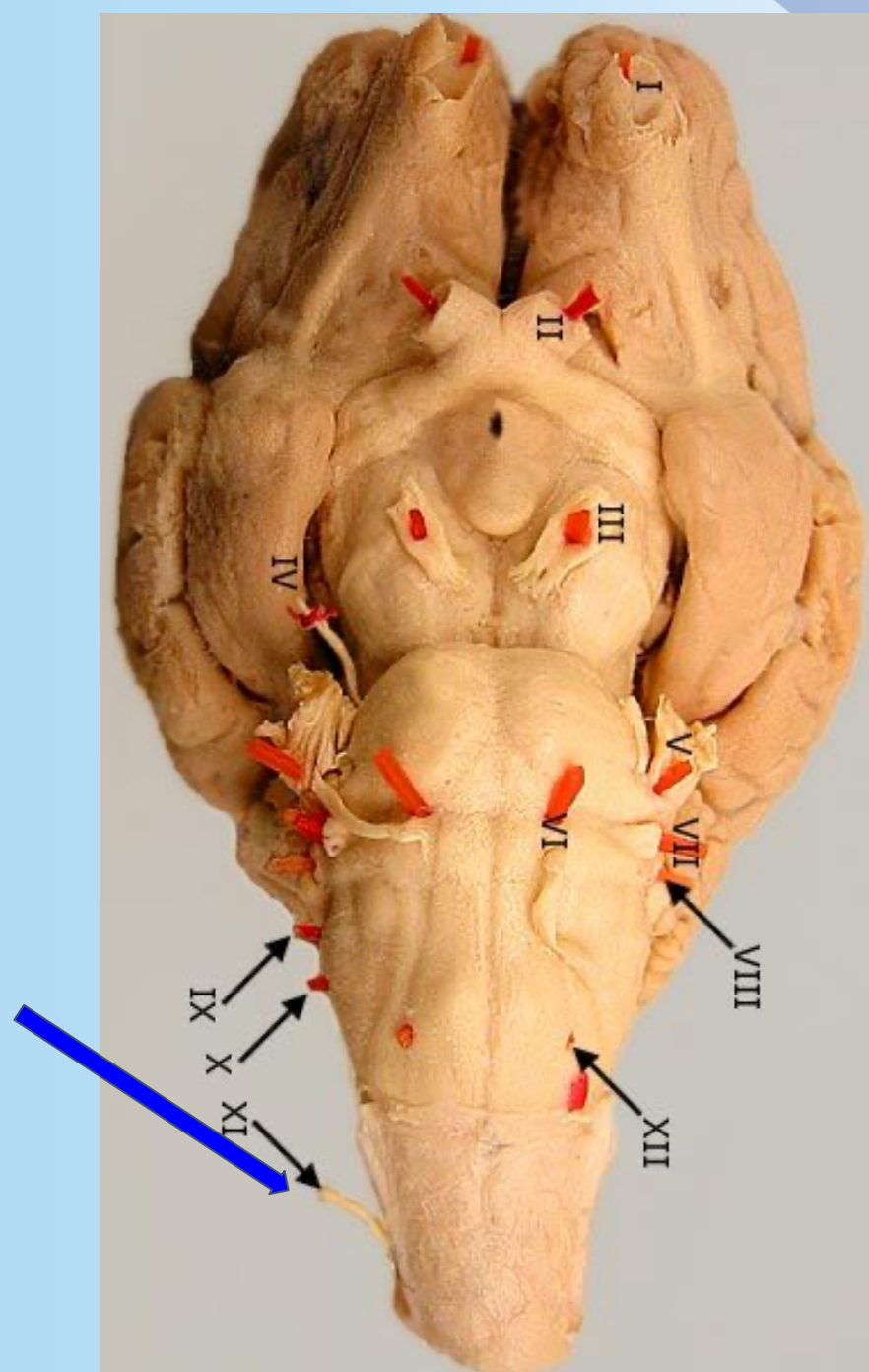
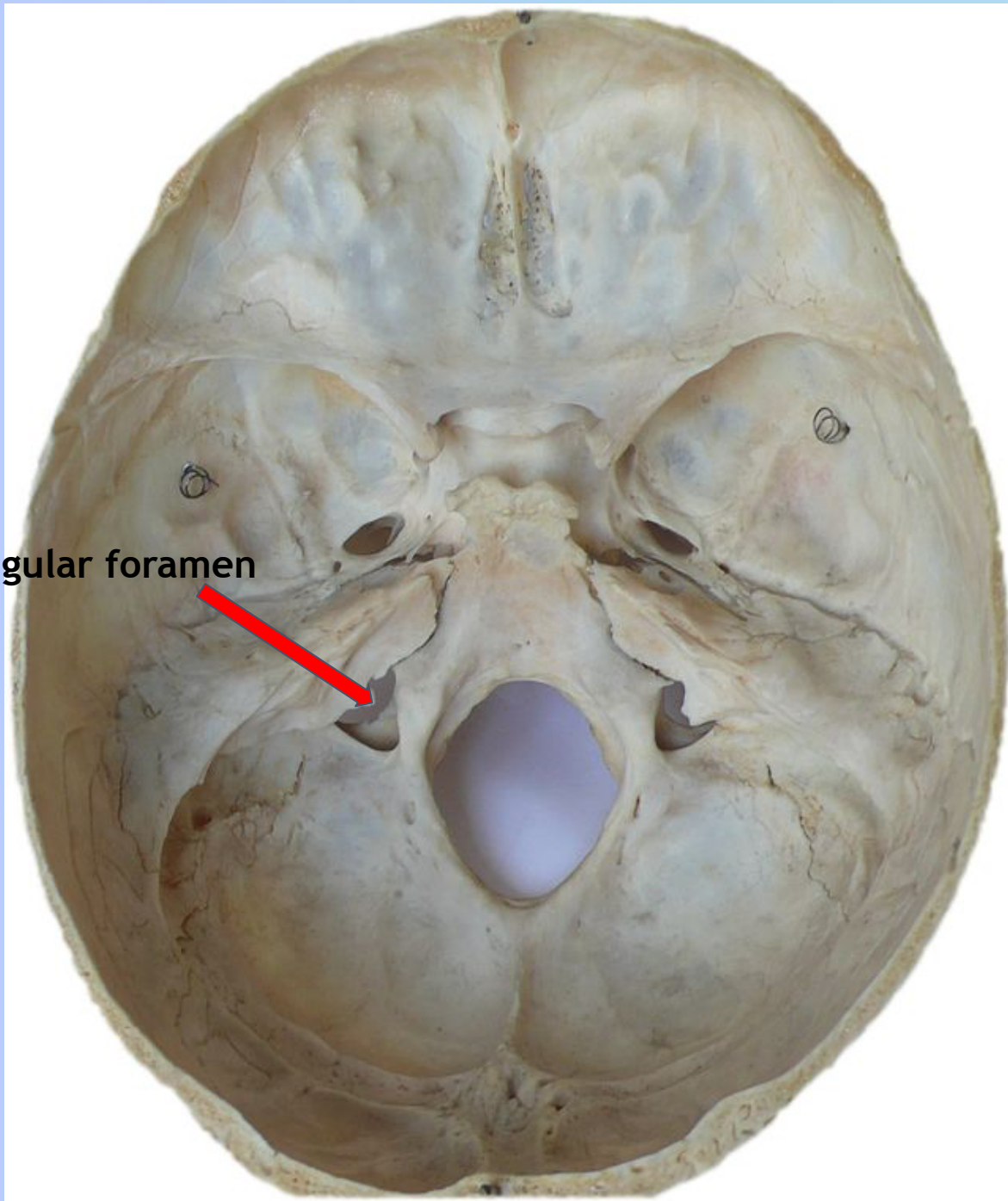
- Inability to shrug shoulder
- Difficulty in turning head to opposite side

Lesion site:

- Penetrating injury to posterior cervical triangle
- Skull base fracture



Jugular foramen



CN XII: Hypoglossal Nerve

Function: Muscles of movement of tongue

Cranial exit: Hypoglossal canal

Brainstem exit: Medulla (preolivary sulcus)

Functional Component: GSE

CN XII: Hypoglossal Nerve

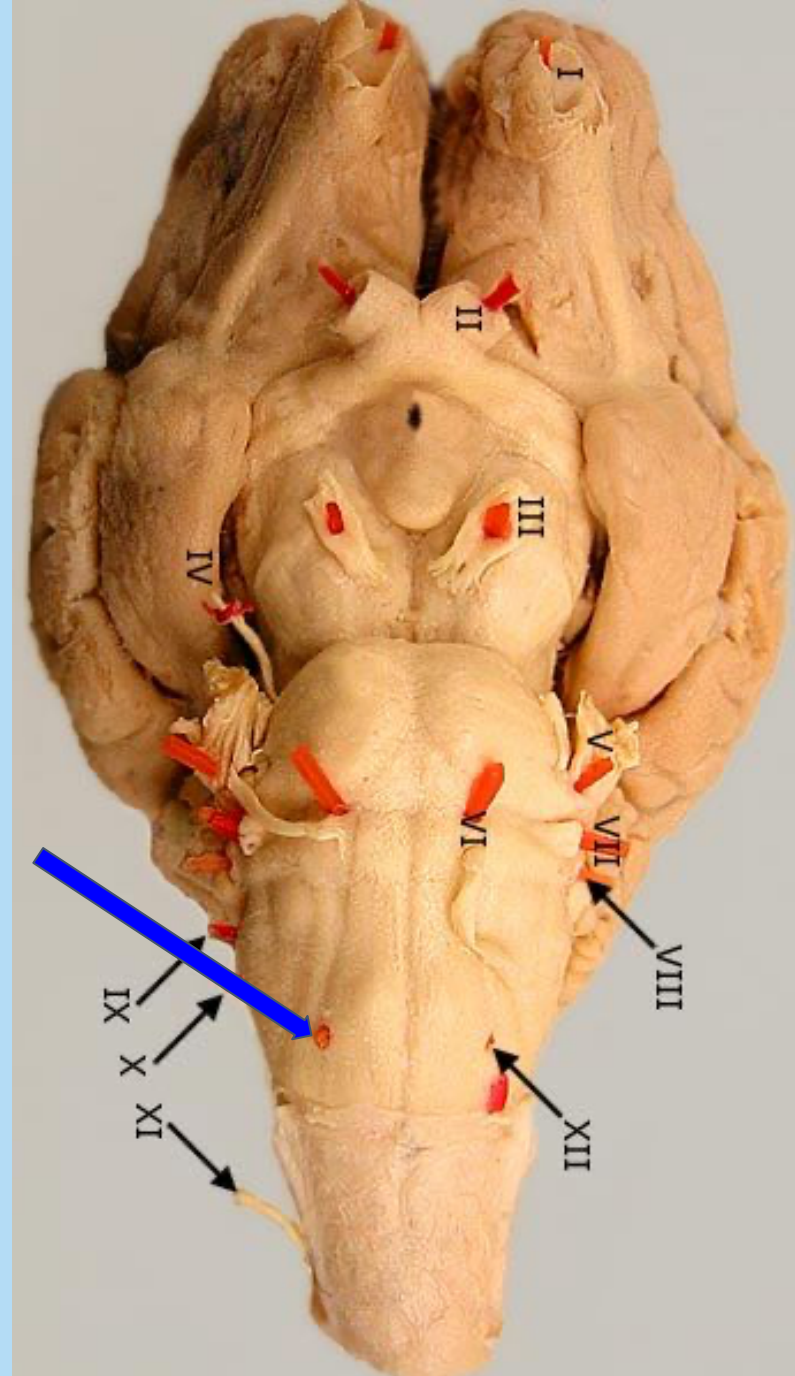
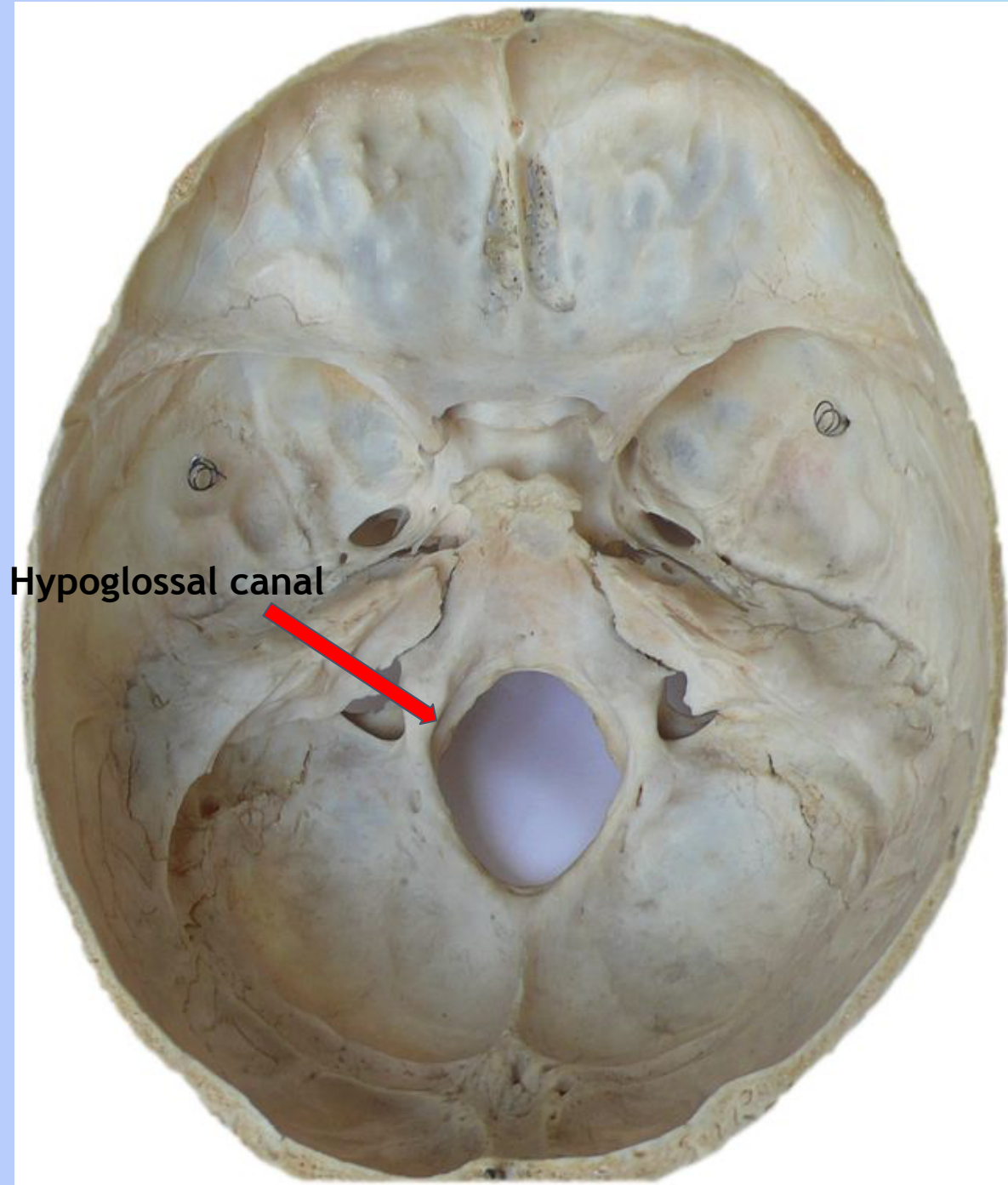
Effect of nerve injury:

- Loss of tongue movements
- Tongue deviation toward lesion side (genioglossus m.)

Lesion site:

- Deep laceration of neck
- Basal skull fracture





Today's Agenda

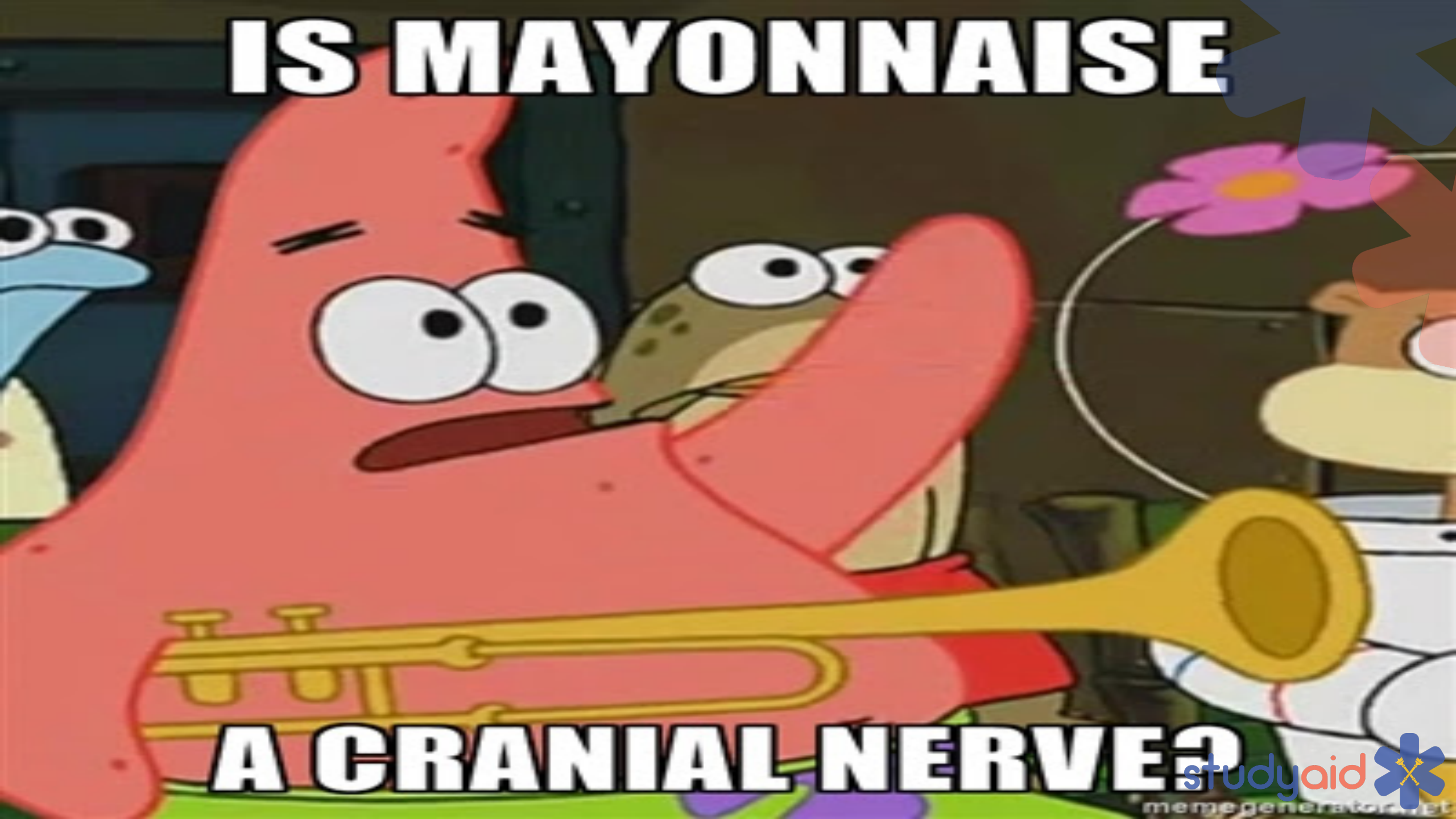
- ~~Quick overview of all cranial nerves~~
- ~~Functional components of cranial nerves~~
- ~~CN I, V, VII-XII~~
- Reflexes

Cranial Nerve Reflexes

Reflex	Afferent	Efferent
Accommodation	II	III
Corneal	V1 ophthalmic (nasociliary branch)	Bilateral VII
Cough	X	X
Gag	IX	X
Jaw jerk	V3	V3
Lacrimation	V1 (emotional tears still possible with lesion)	VII
Pupillary	II	III
Sneeze	V2	X
Carotid sinus	IX	X

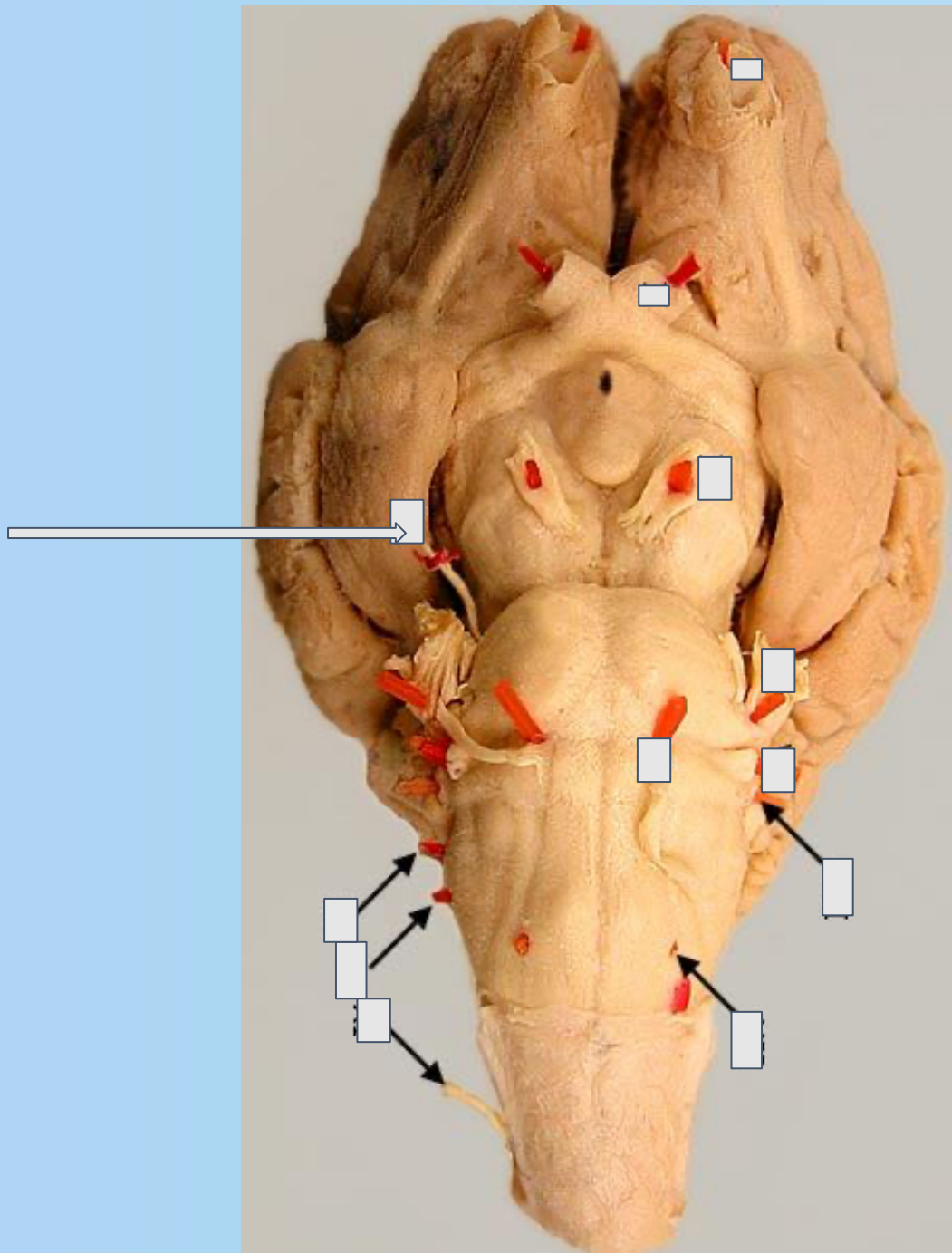


IS MAYONNAISE

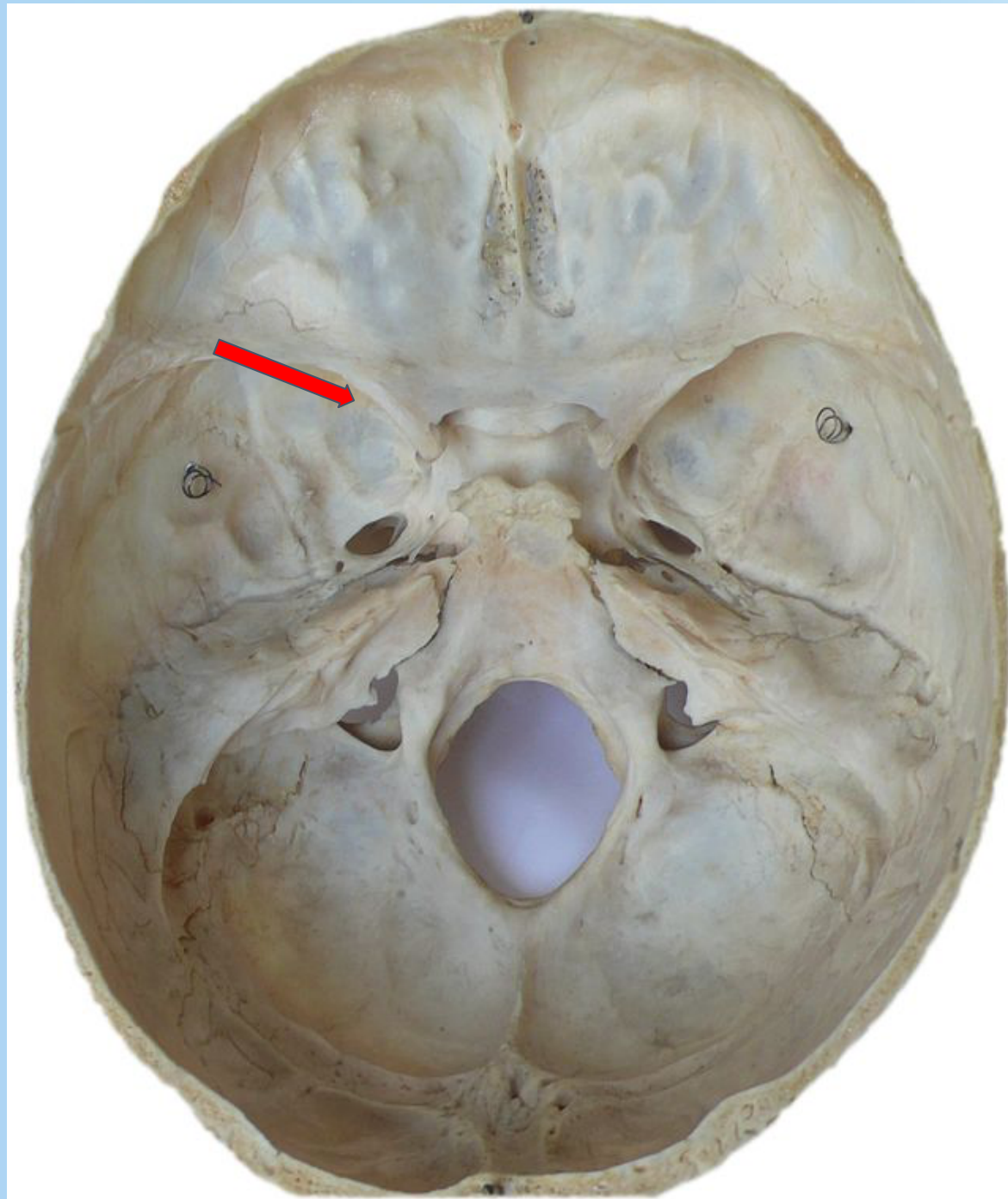


A CRANIAL NERVE?

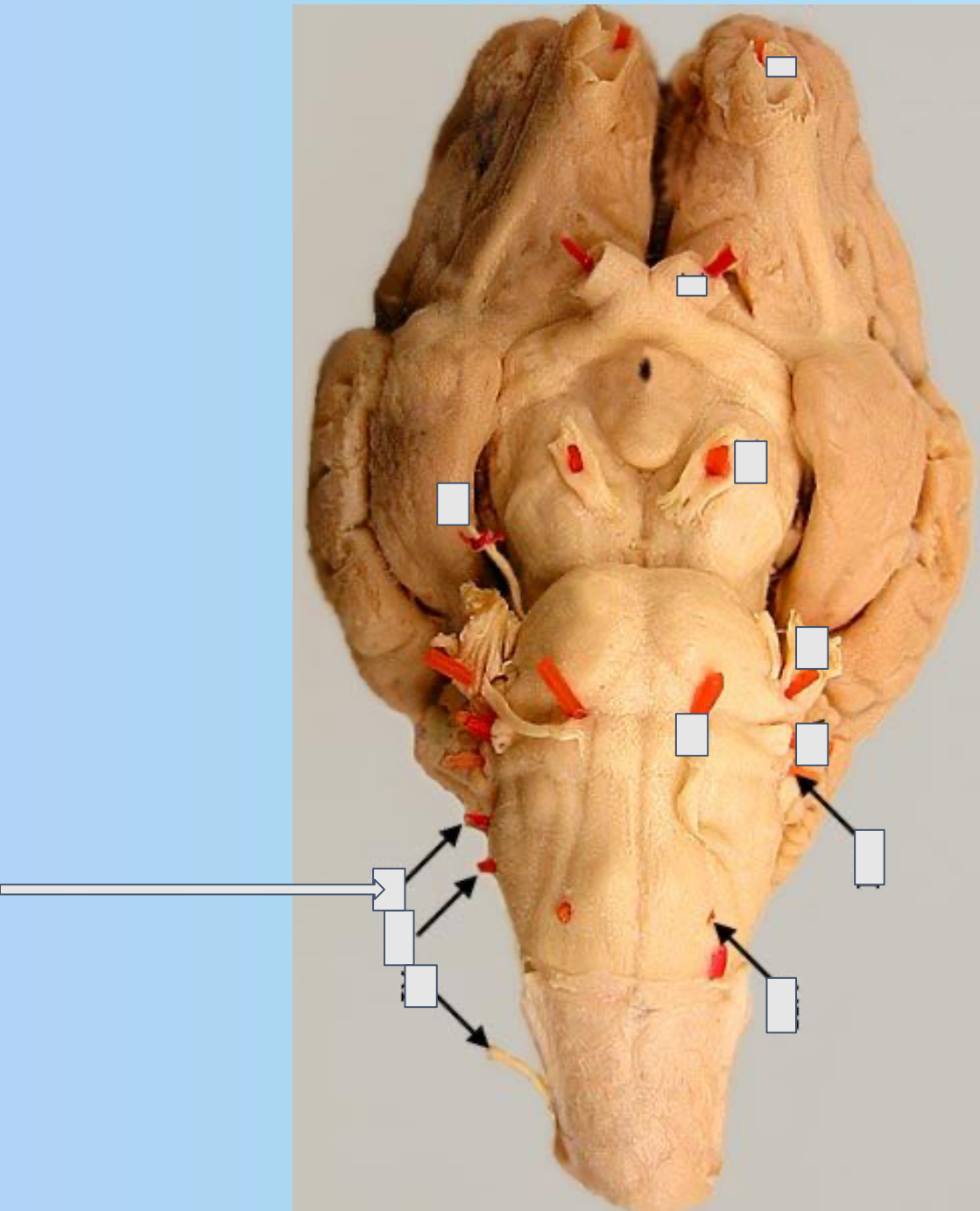
A



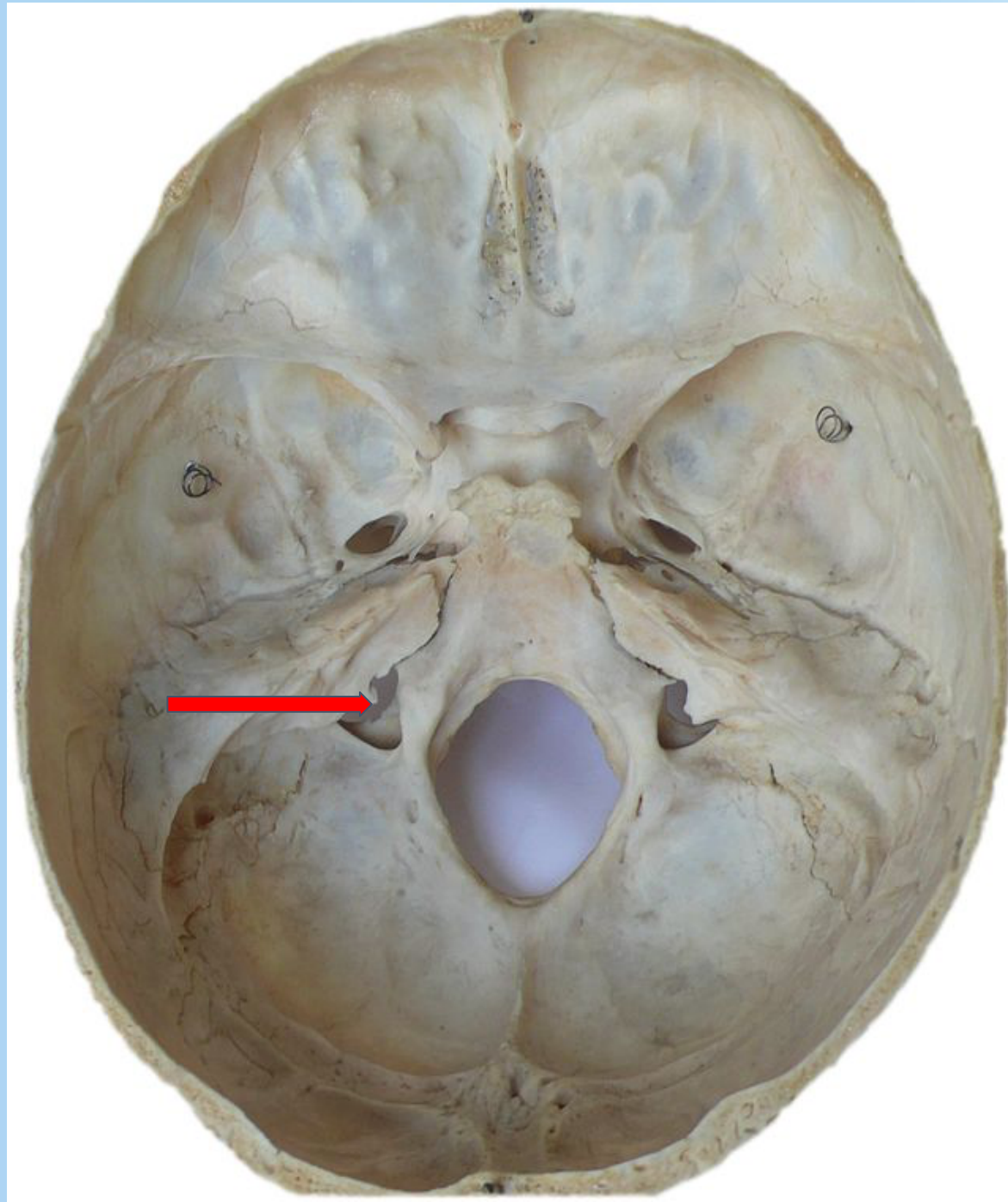
B



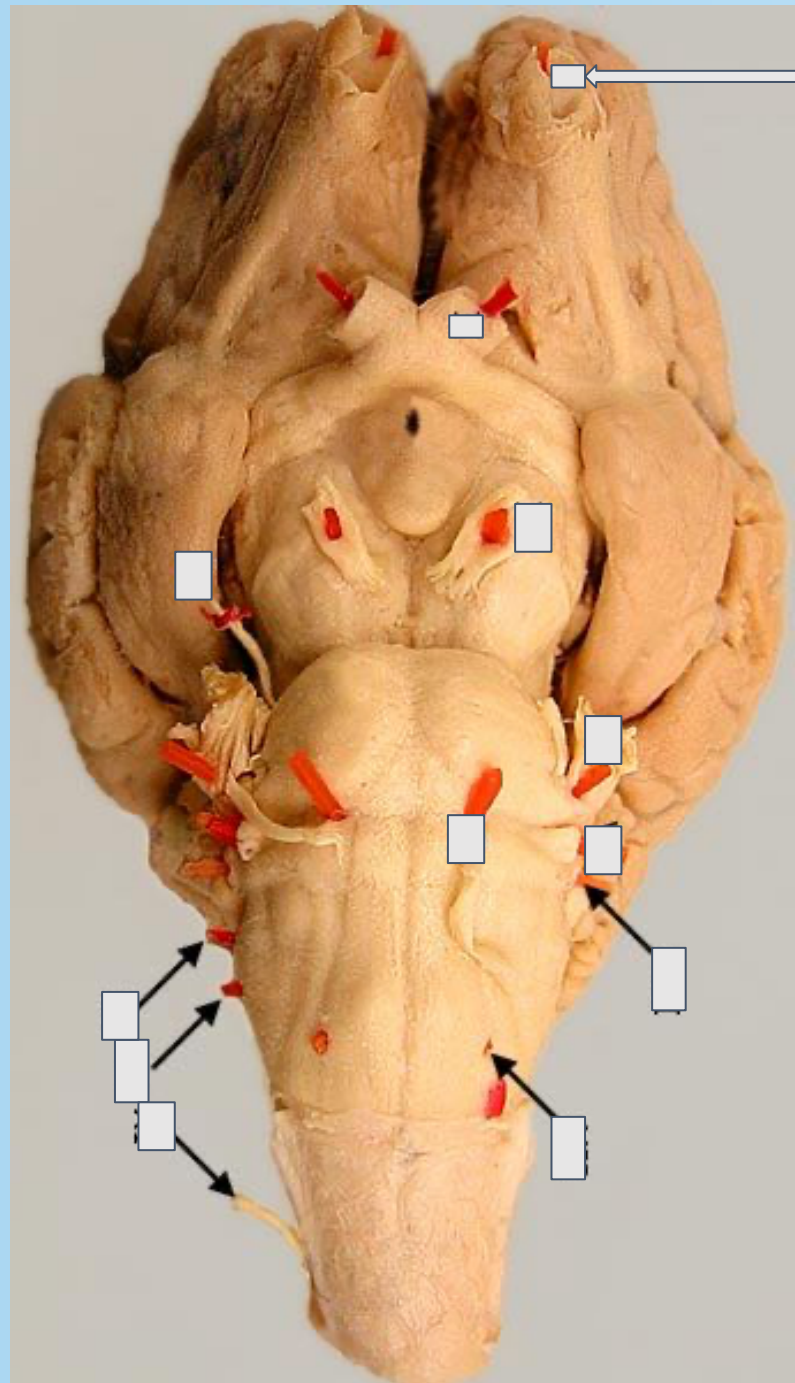
C



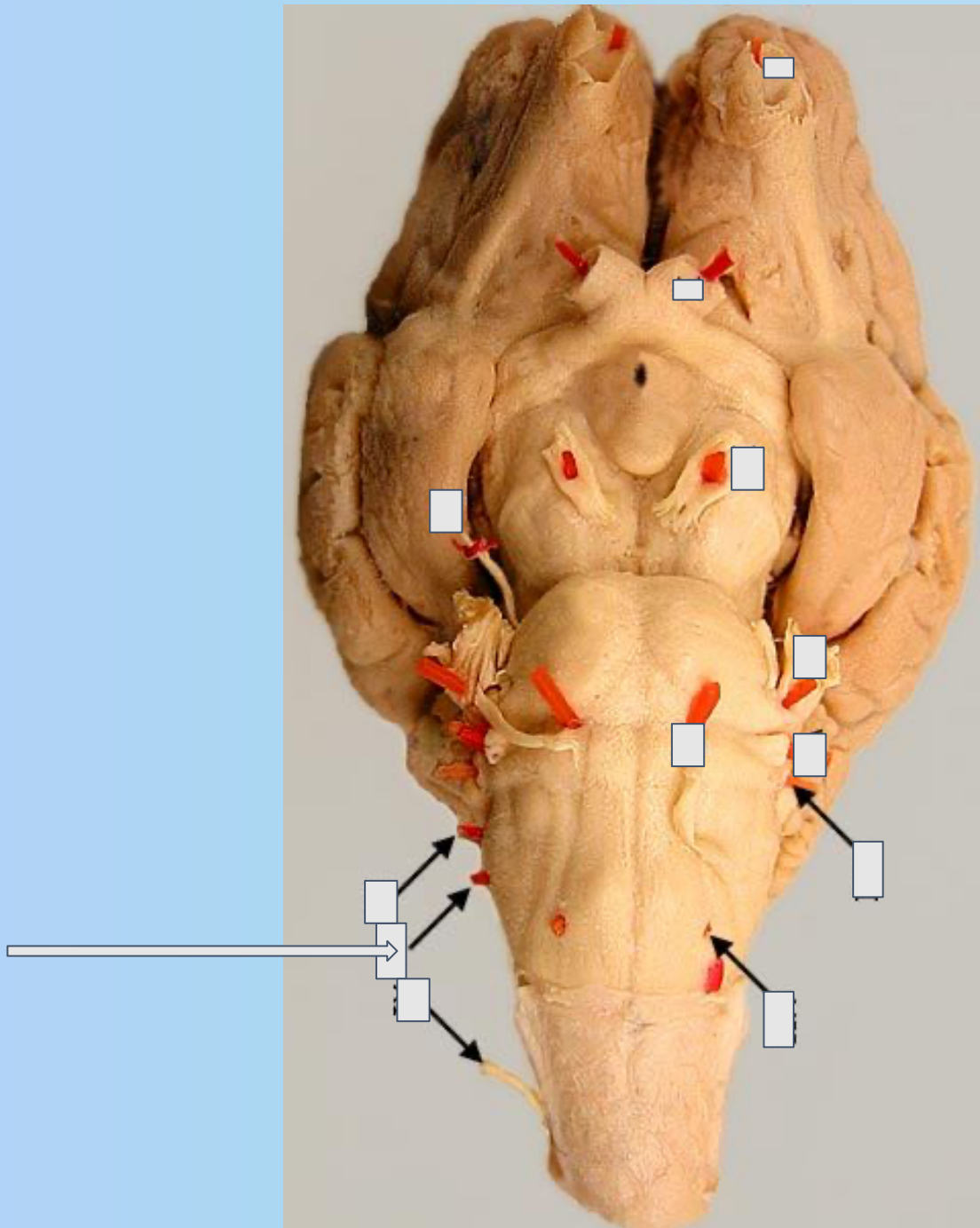
D



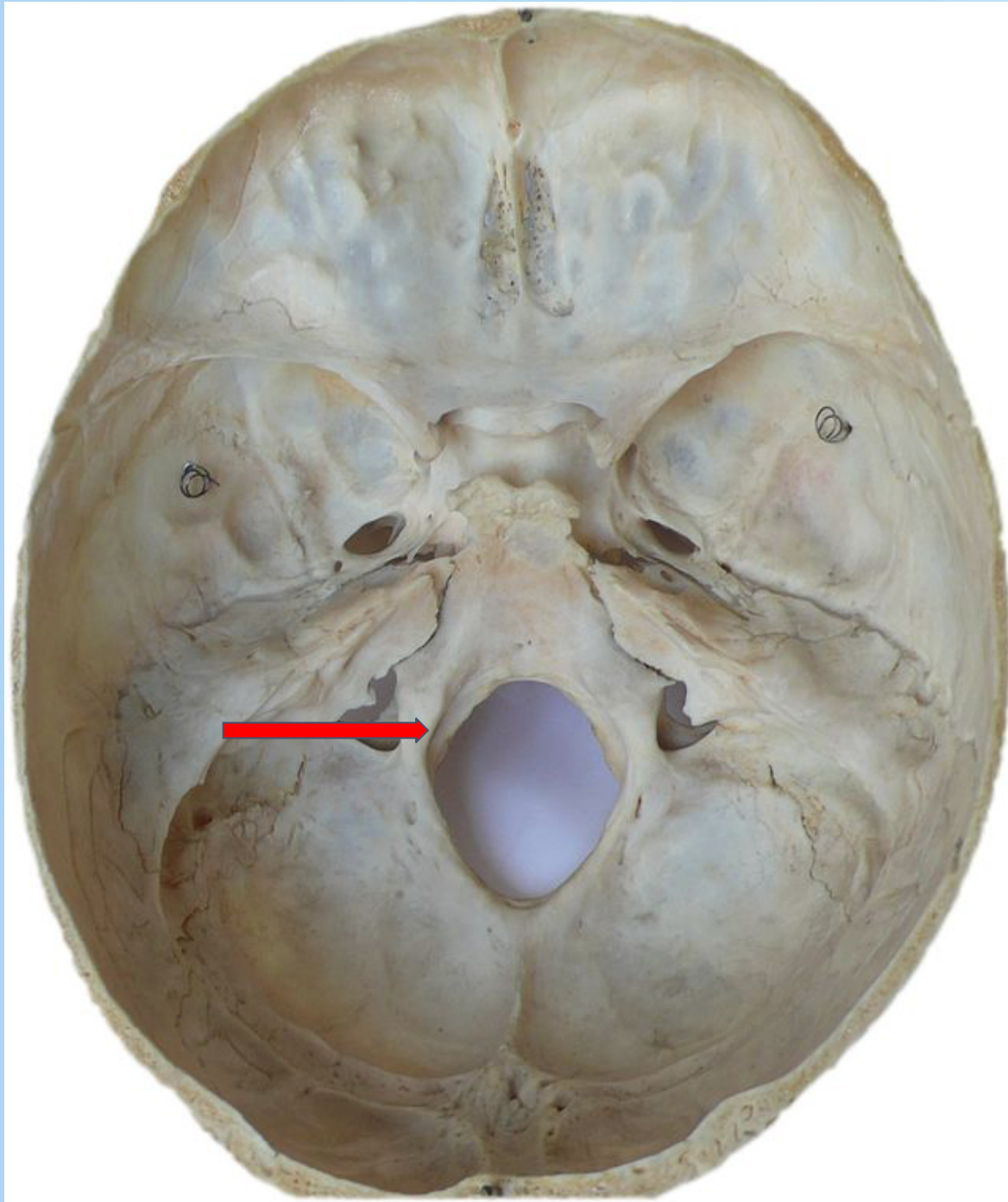
E



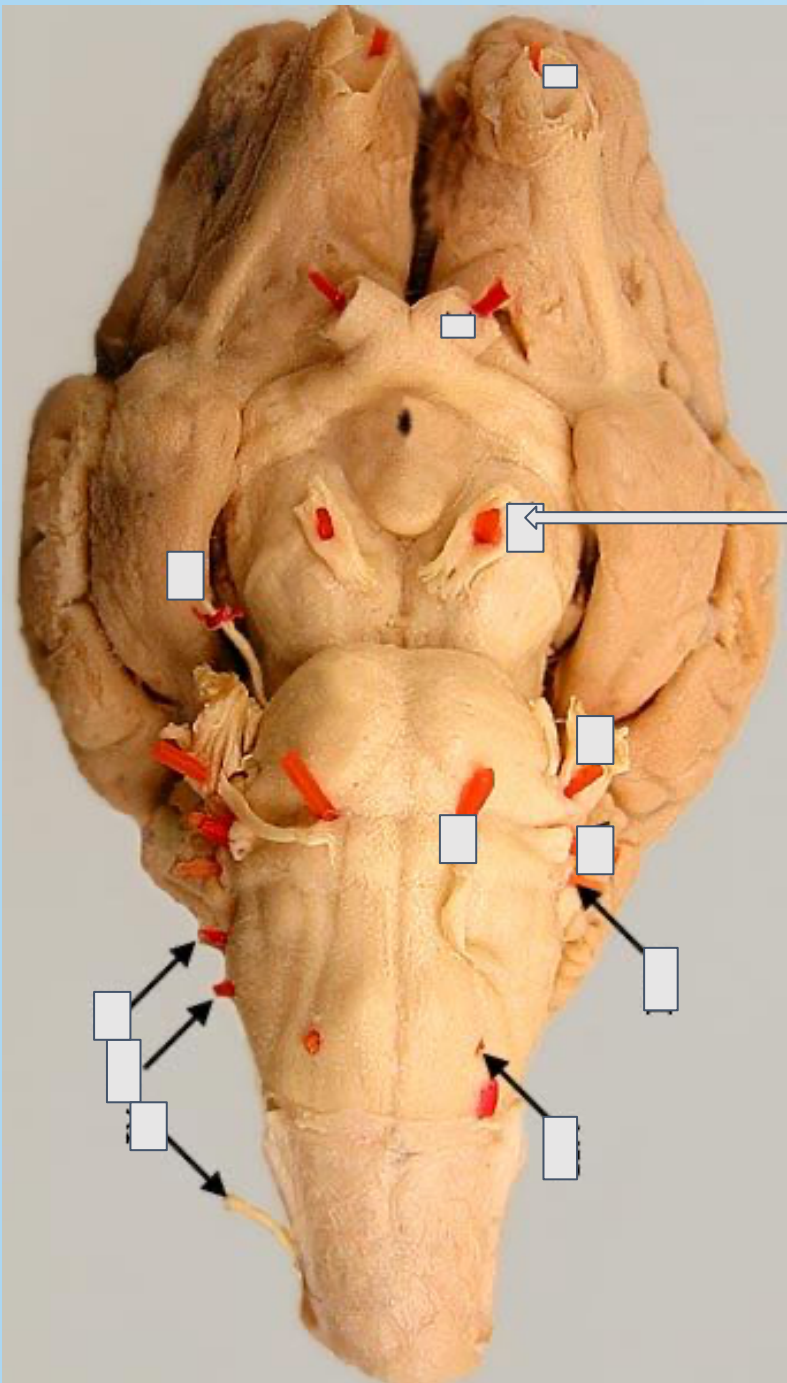
F



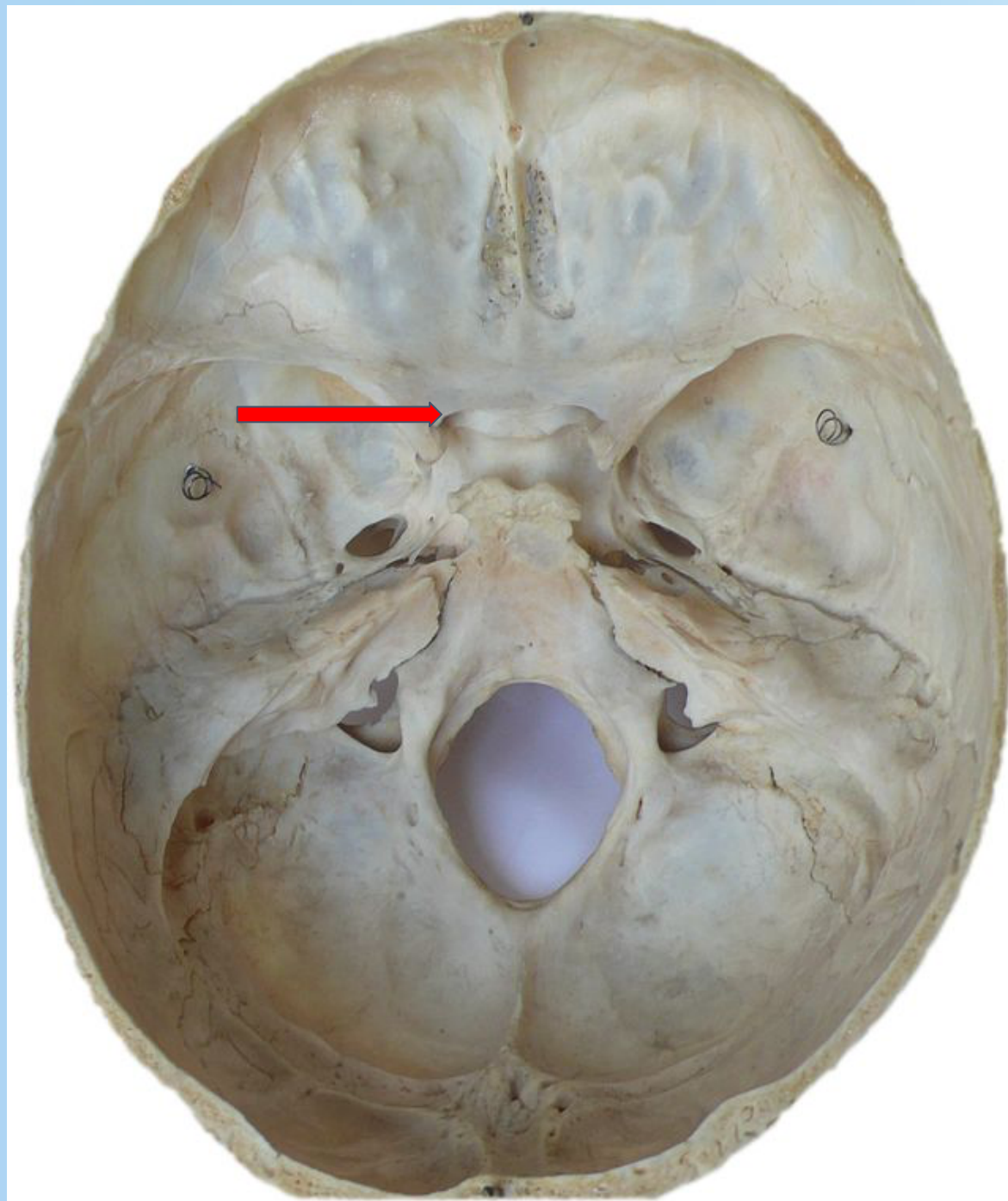
G



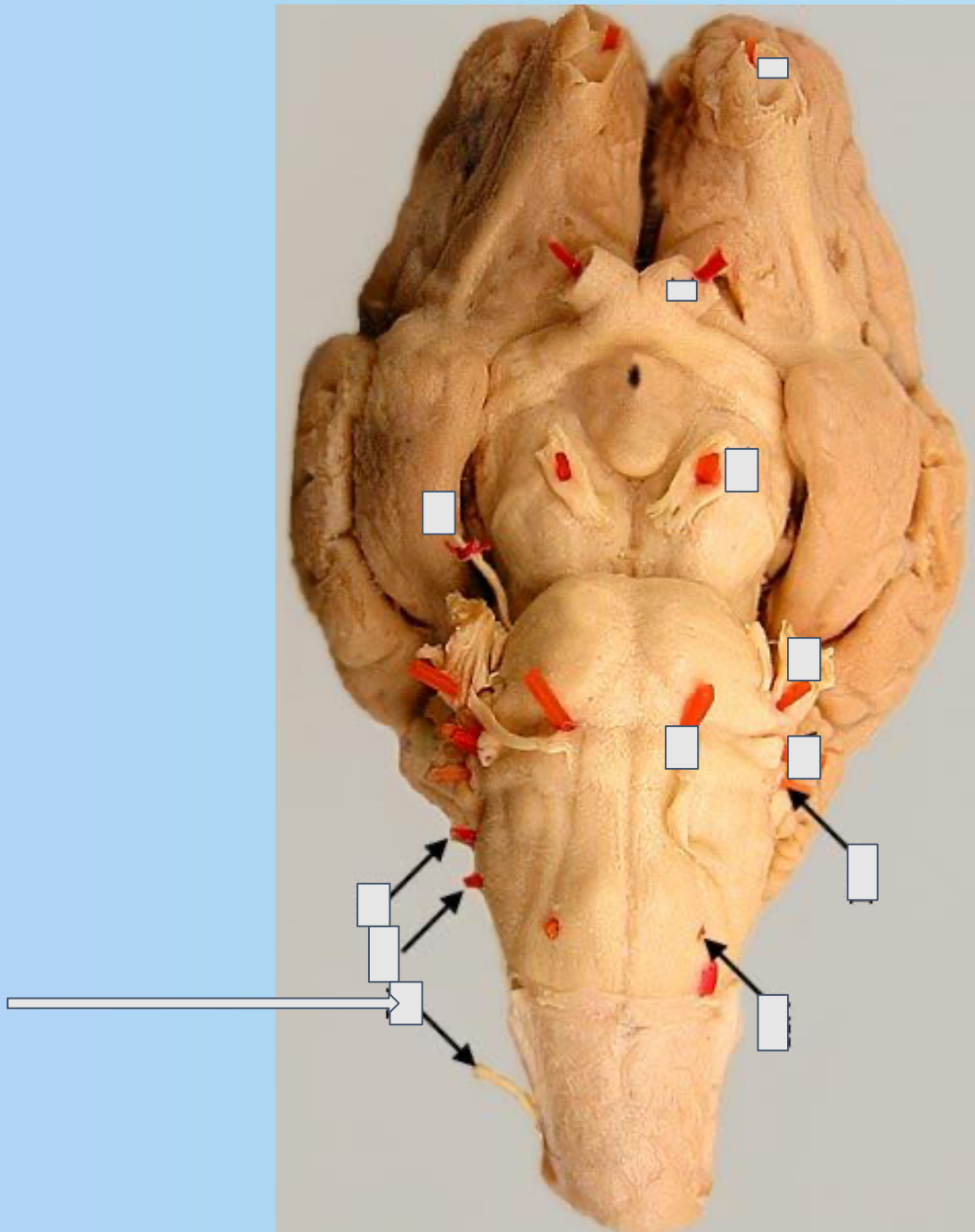
H



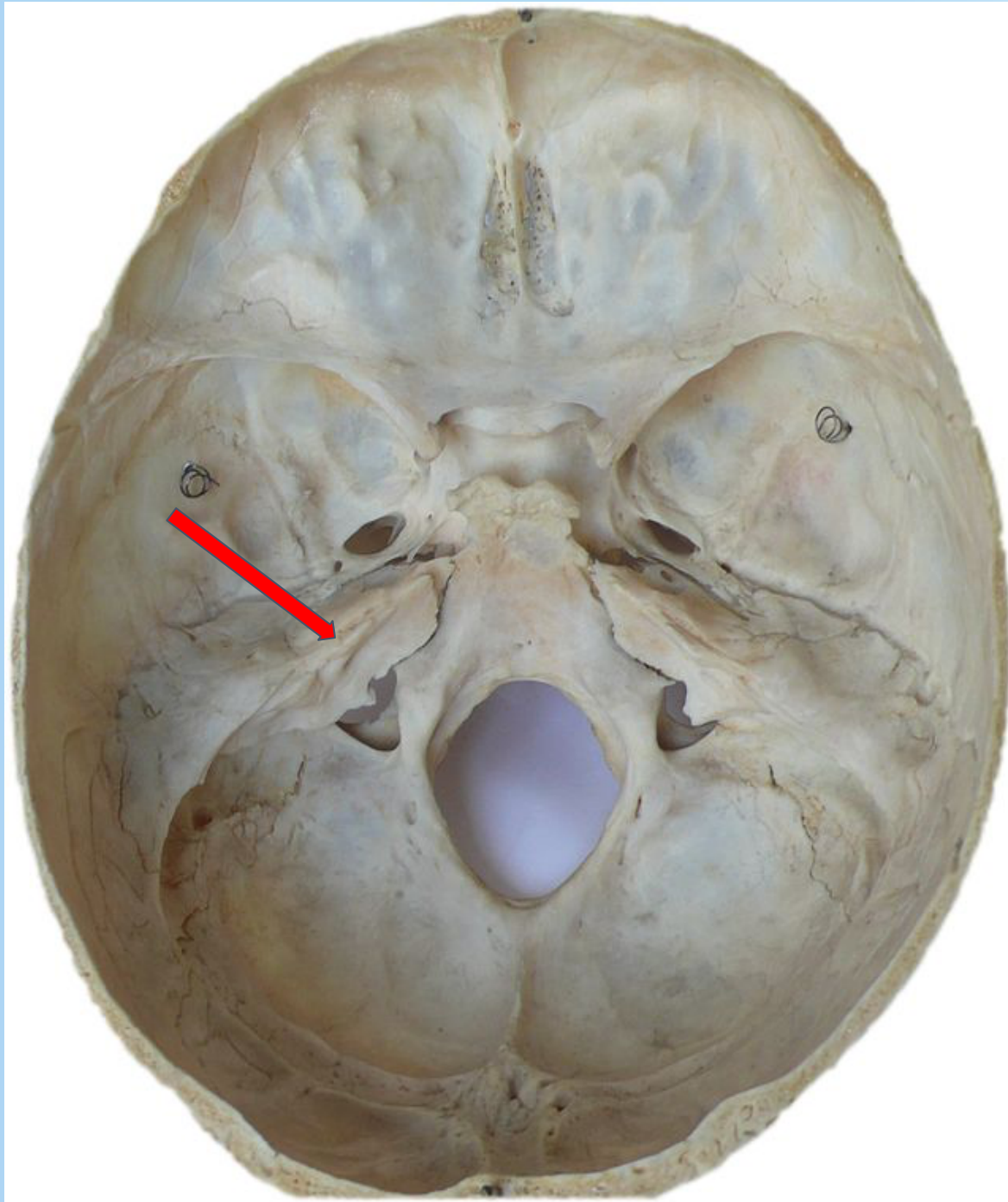
I



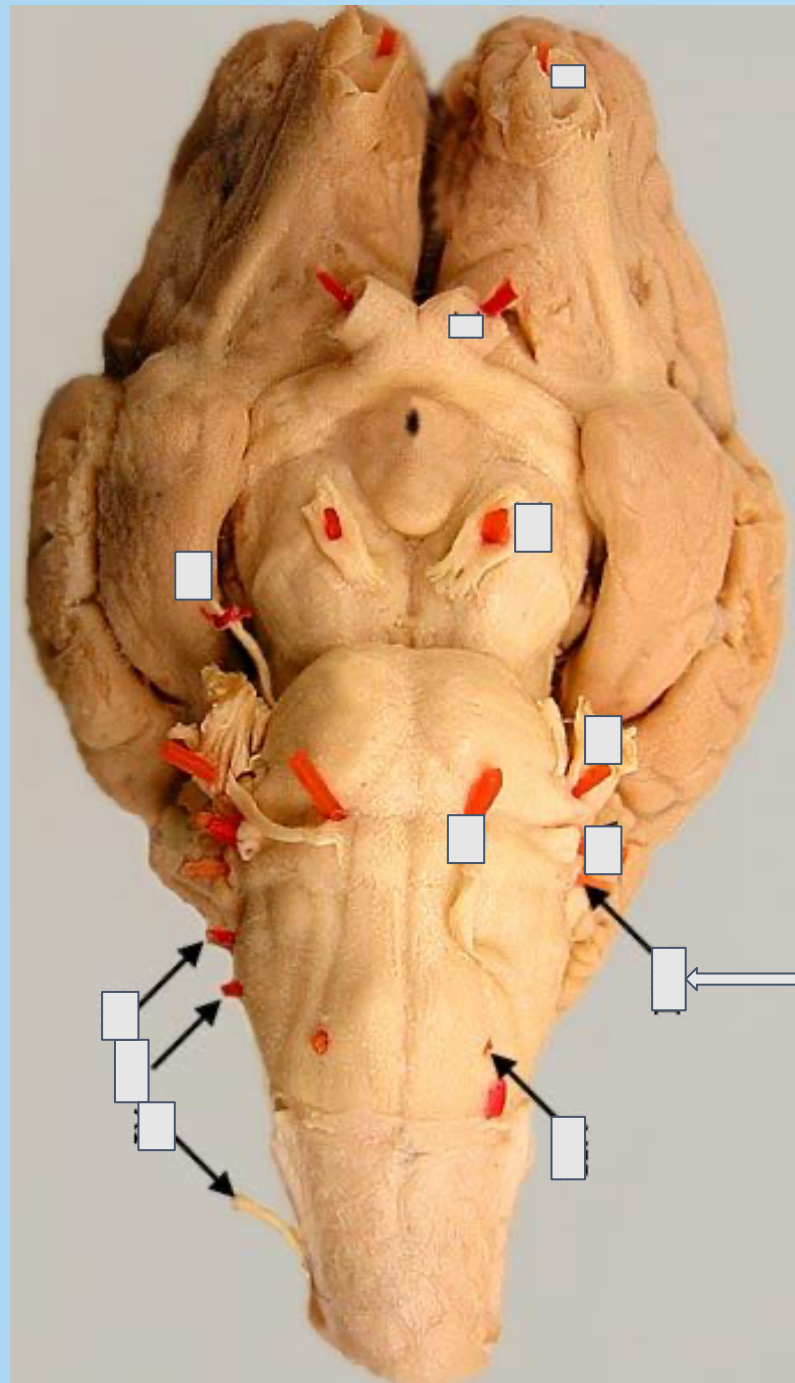
J



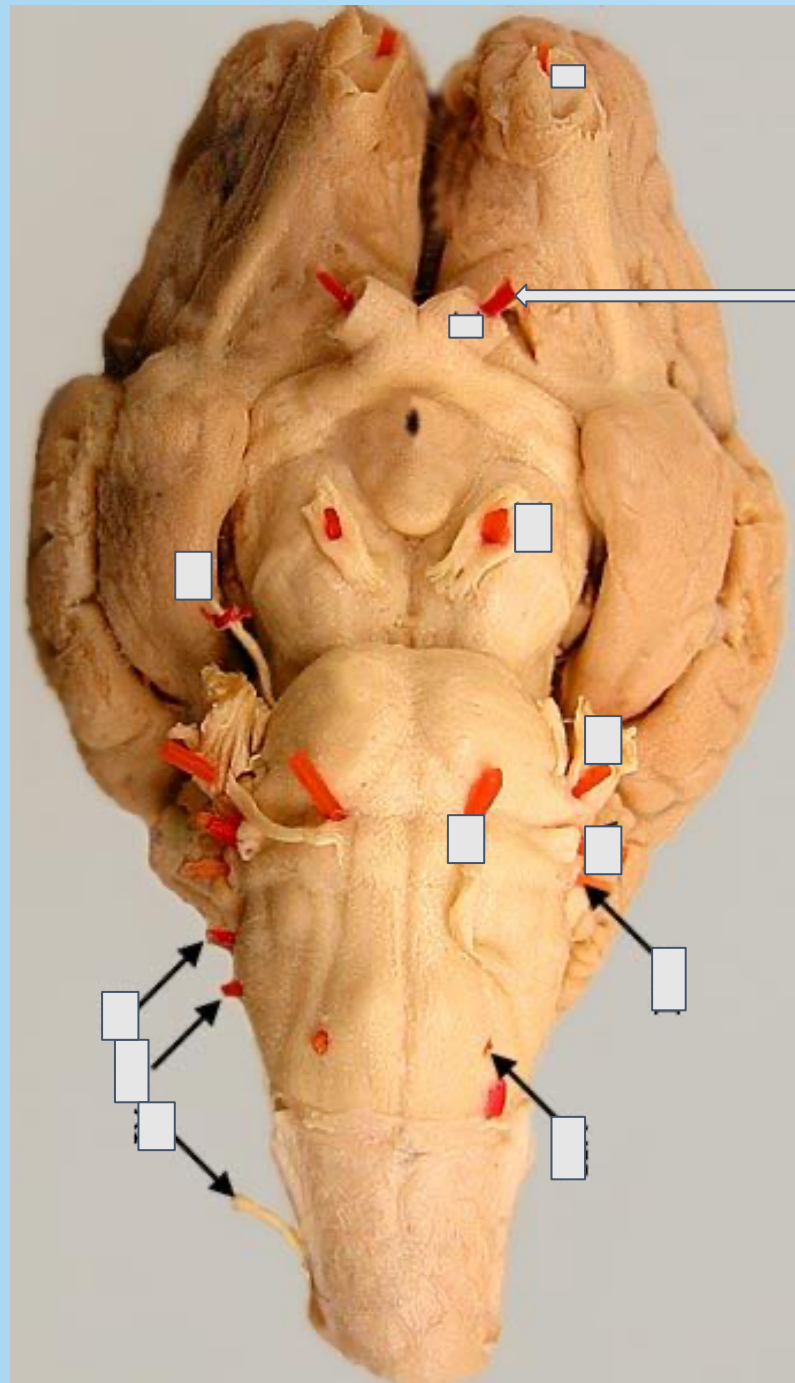
K



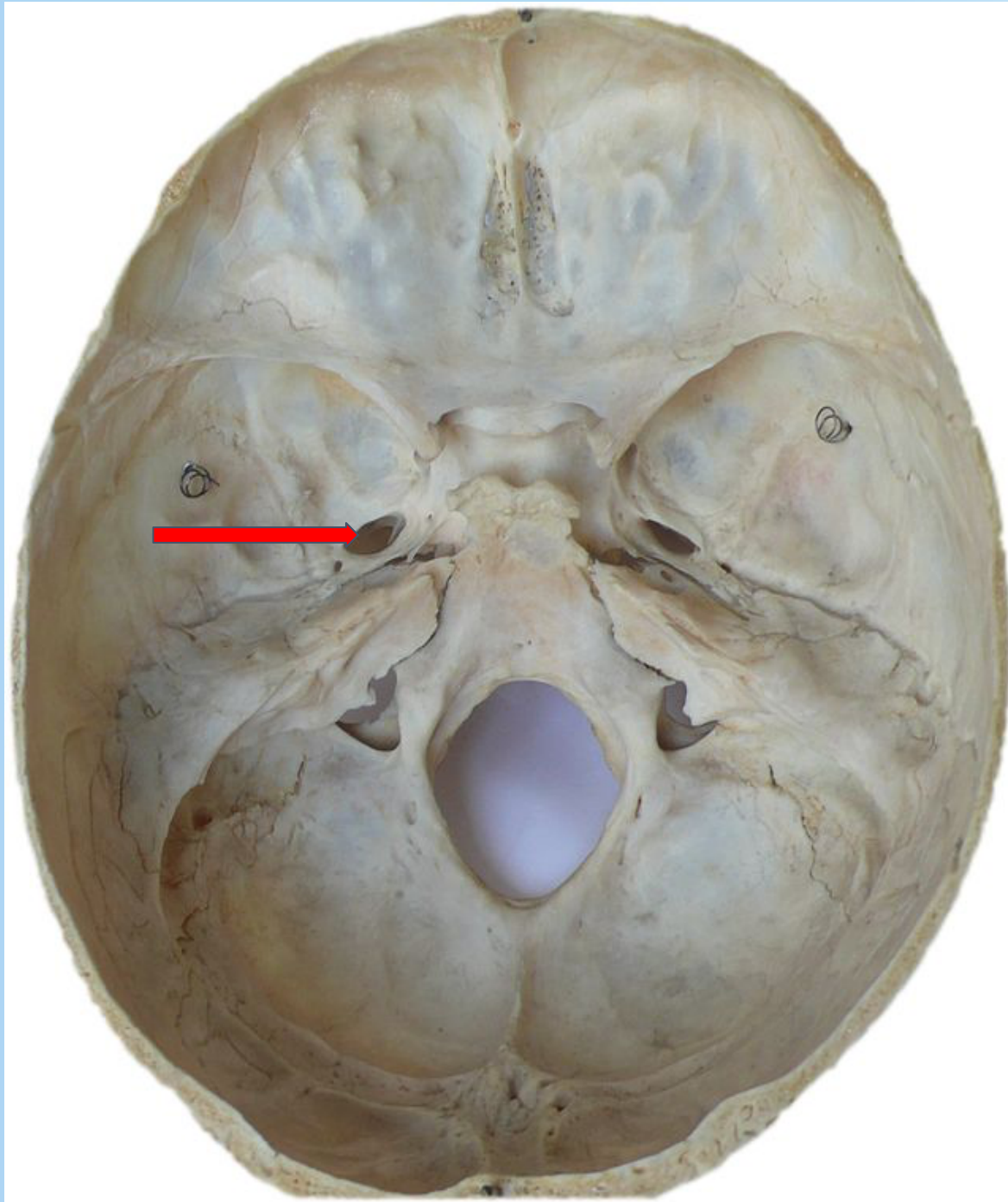
L



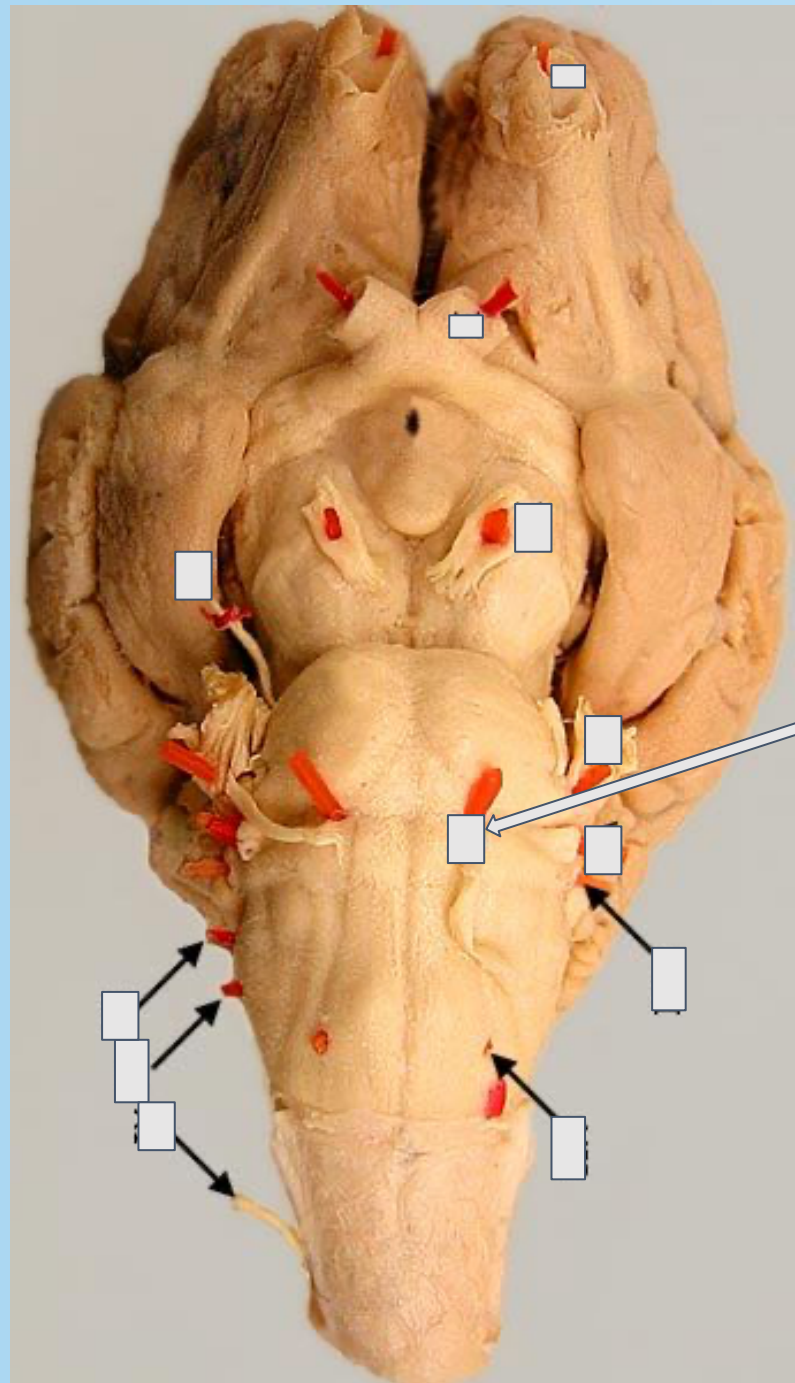
M



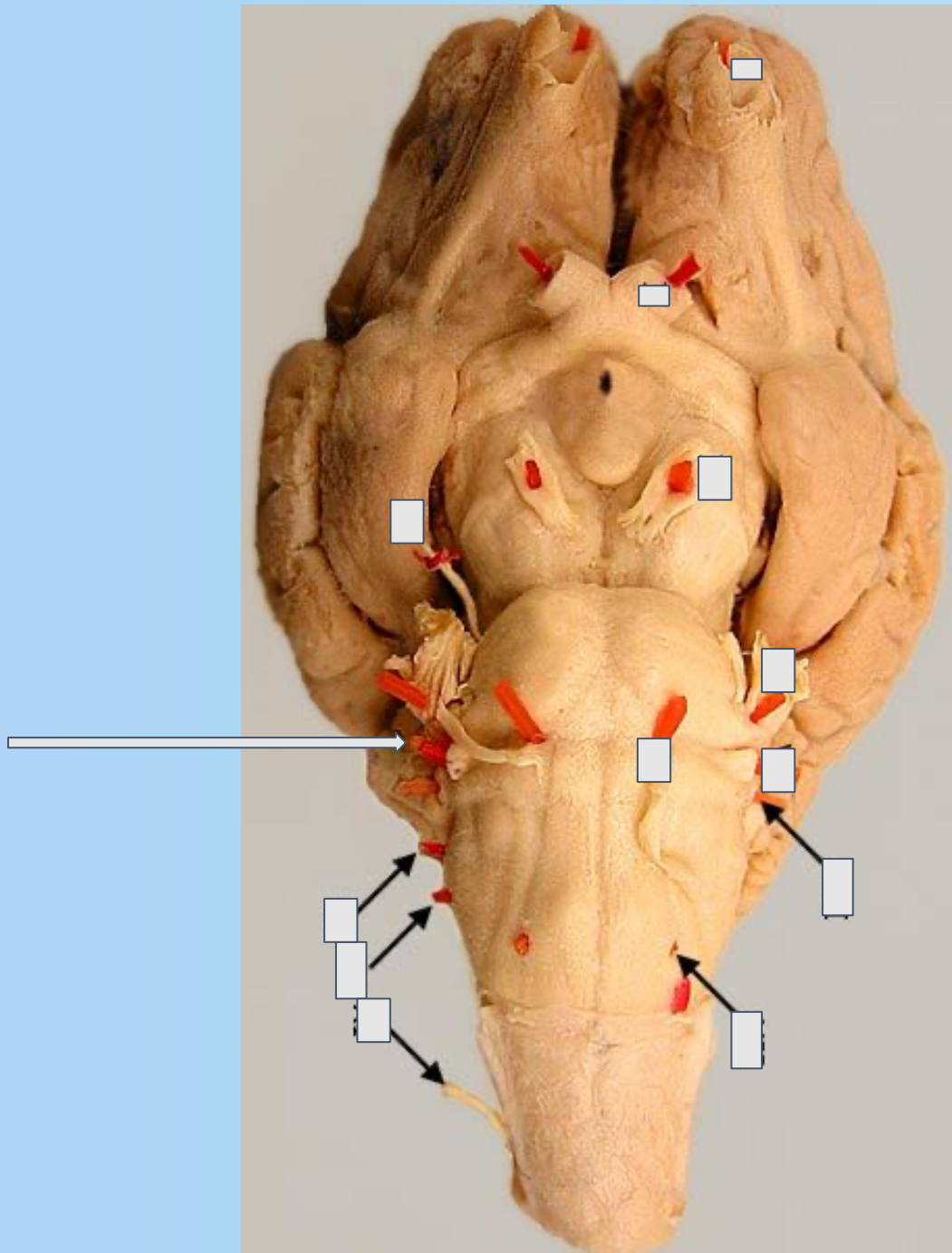
N



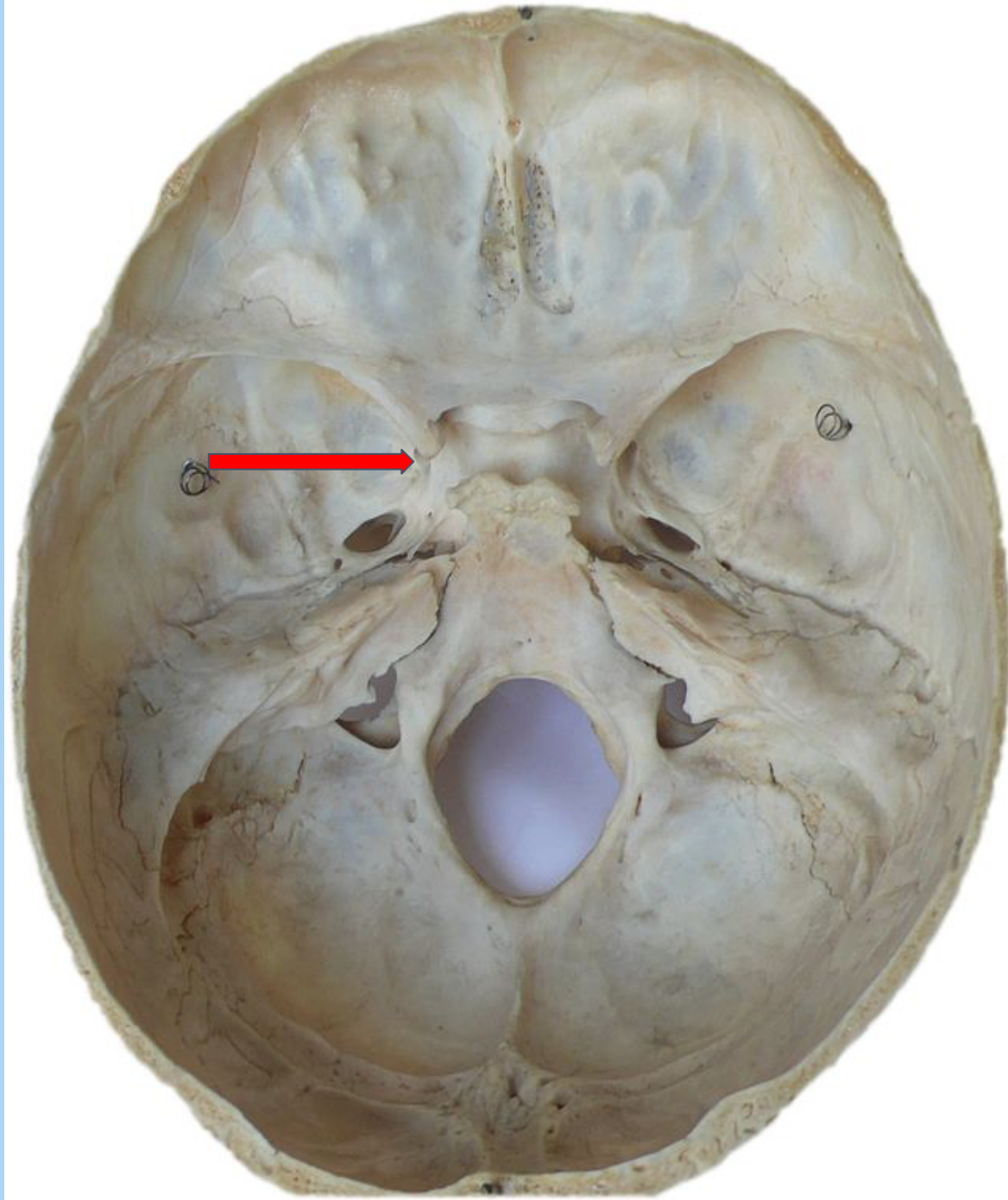
0



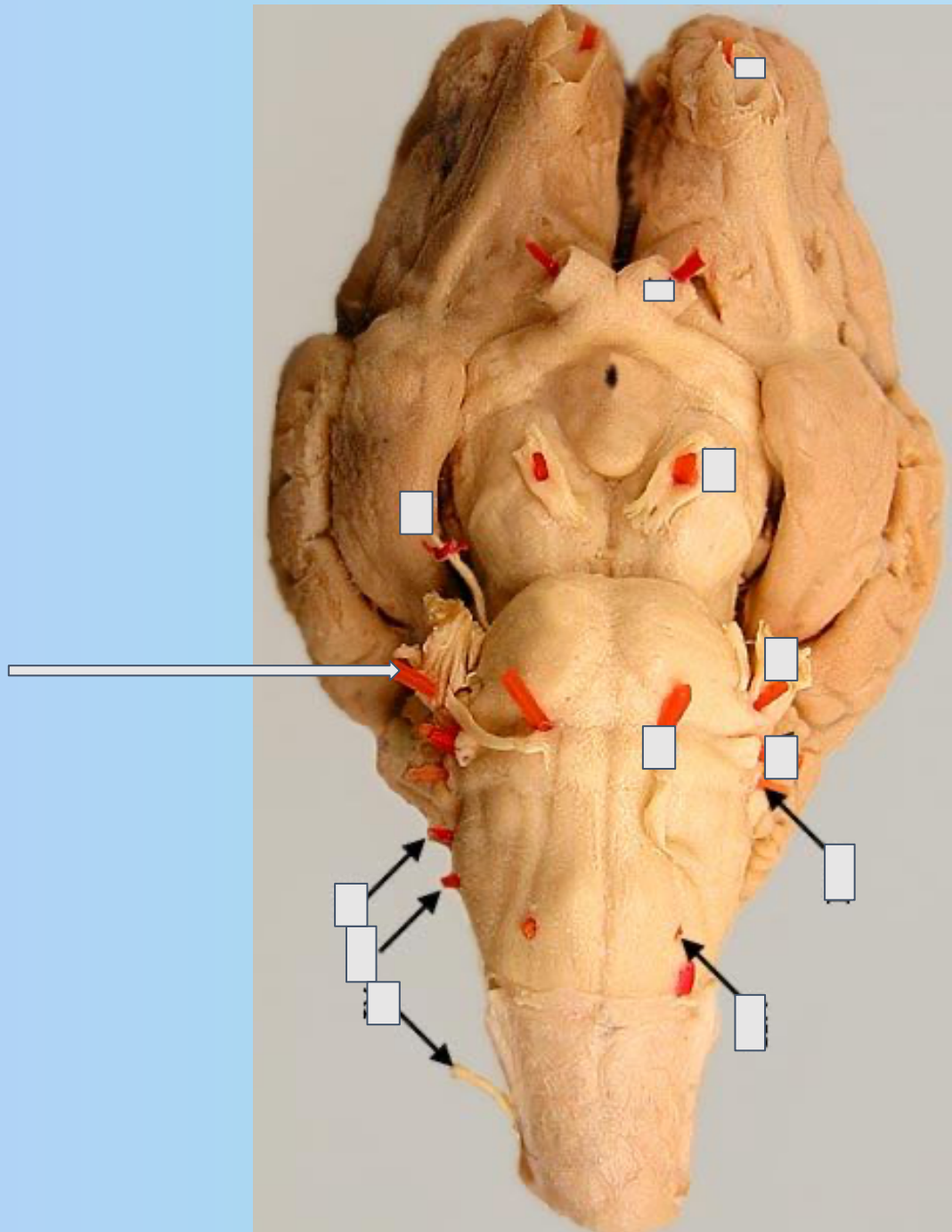
P



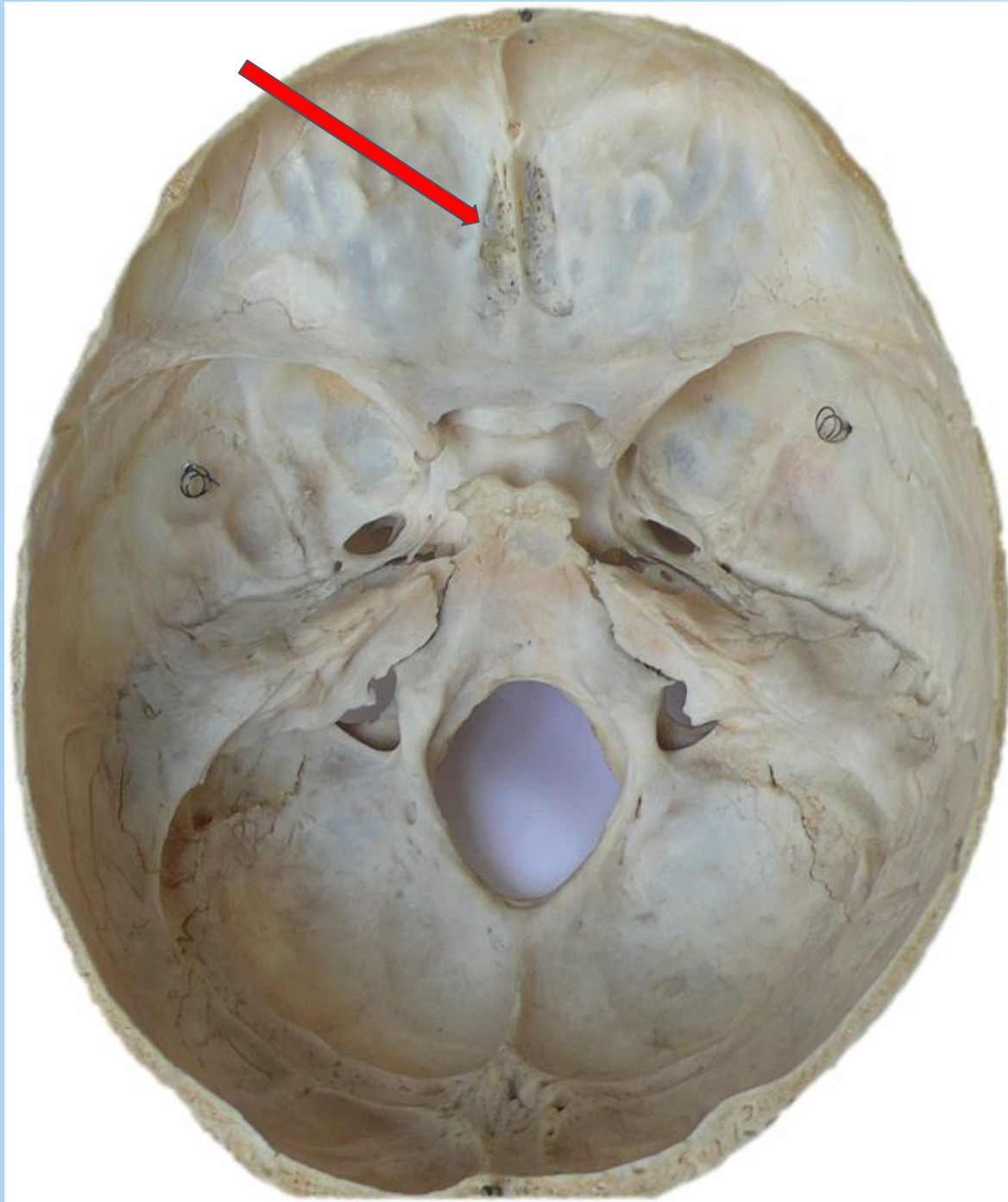
Q



R



S



T

