# Nerve supply of upper limb

By Ola Amland

studyaid

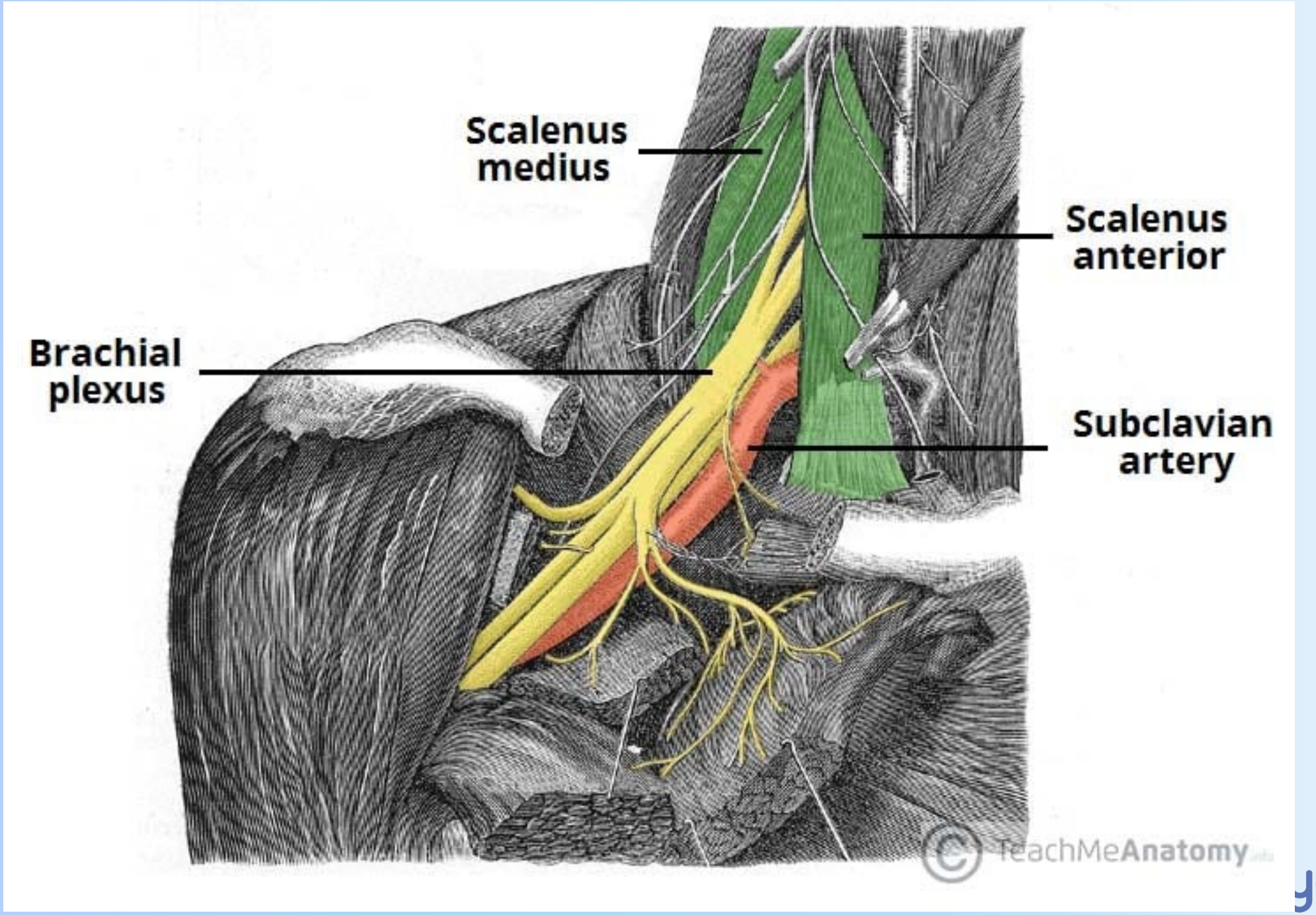
Scalenus medius
Scalenus anterior
Brachial plexus
Subclavian artery
© TeachMeAnatomy

# Scalene triangle

- Brachial plexus
- Subclavian artery (third part)

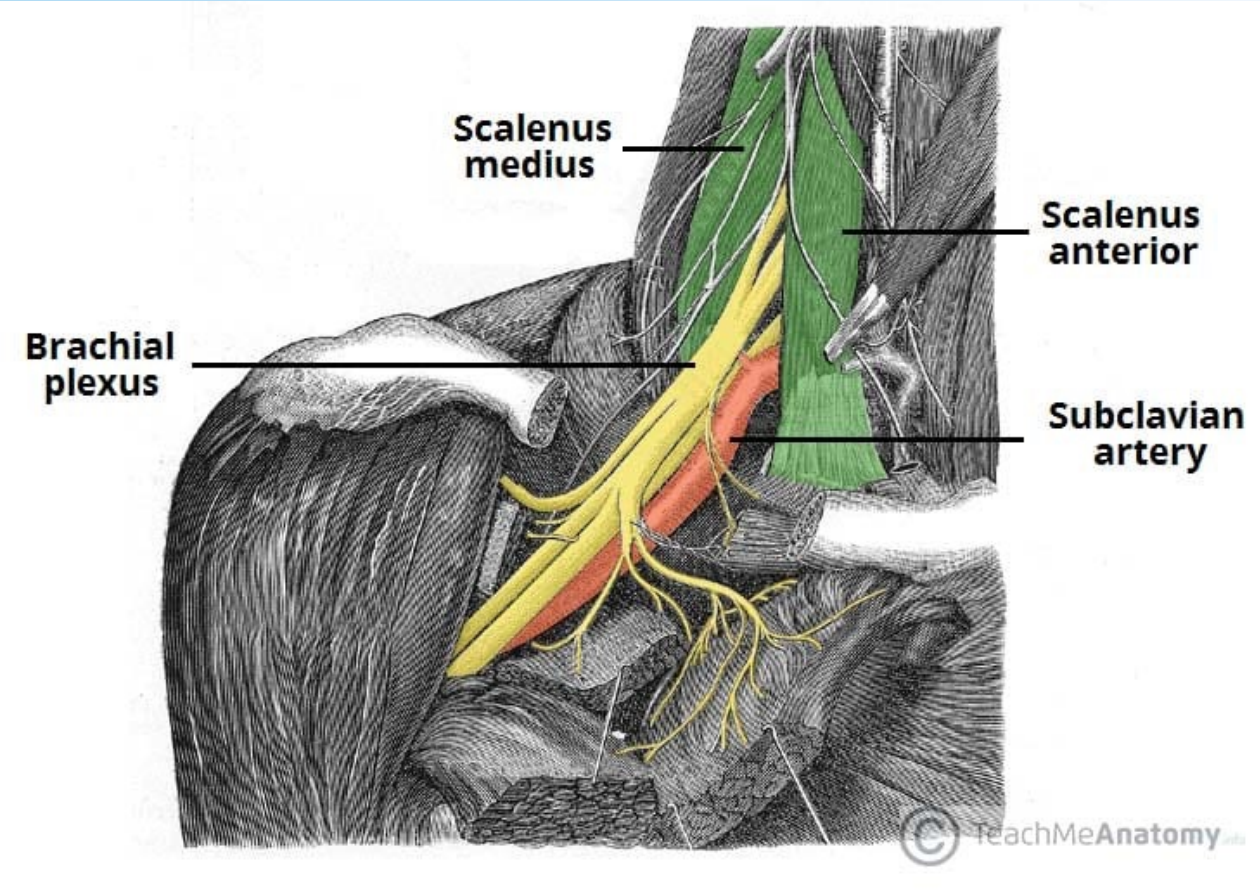

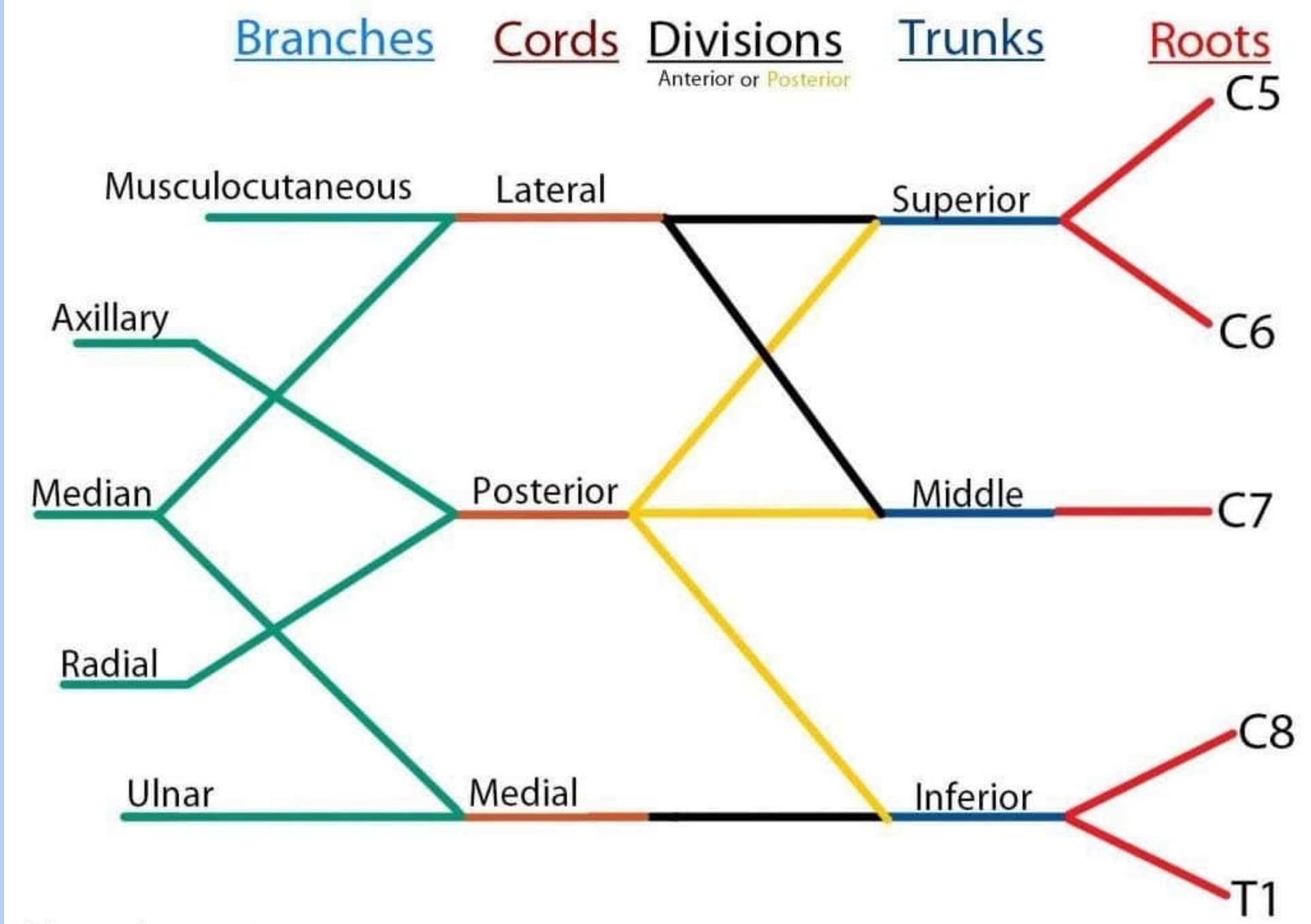


© teachmeanatomy
The #1 Applied Human Anatomy Site on the Web.

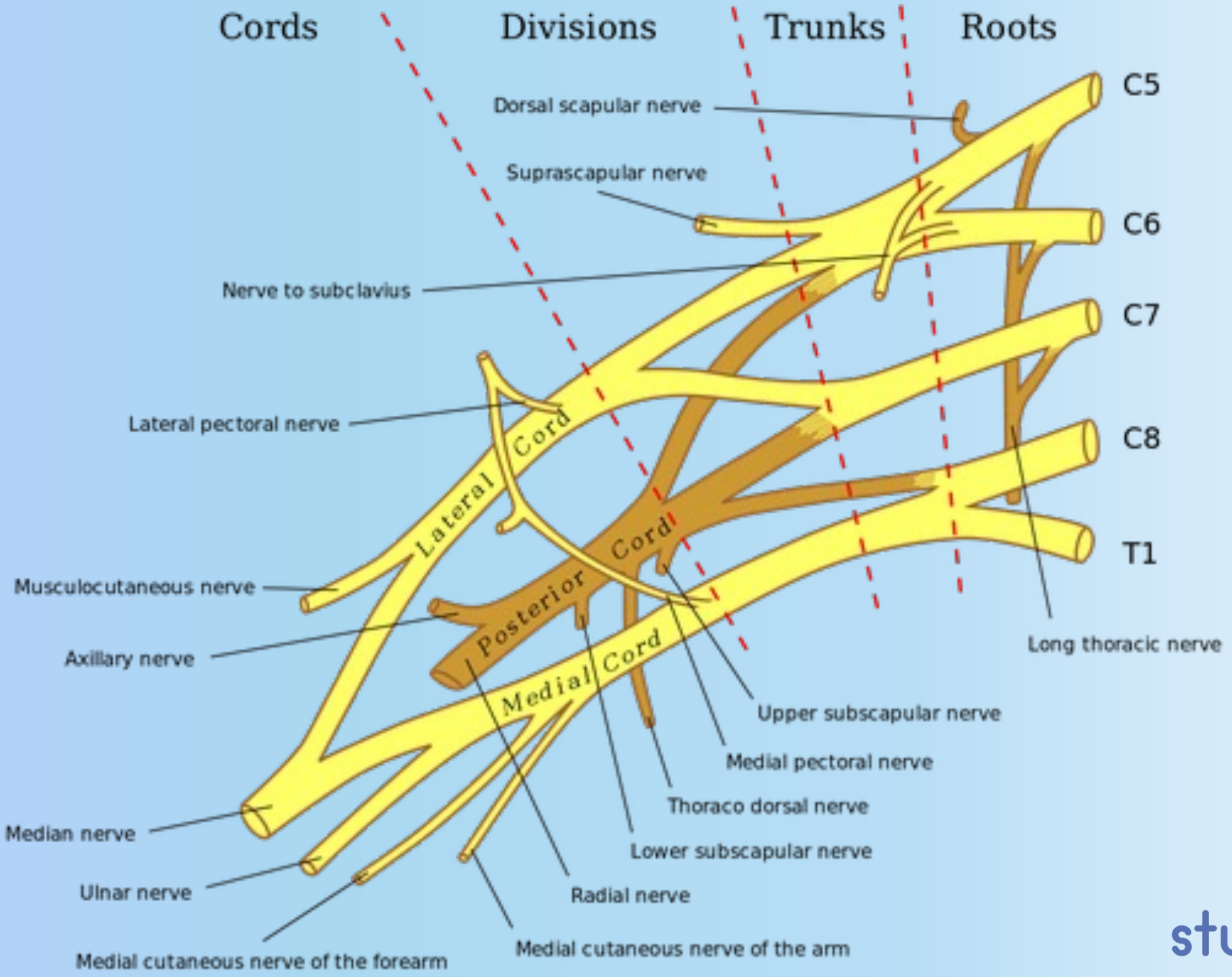
Cords
Divisions
Trunks
Roots
C5
C6
C7
C8
T1
Dorsal scapular nerve
Suprascapular nerve
Nerve to subclavius
Lateral pectoral nerve
Lateral Cord
Posterior Cord
Medial Cord
Musculocutaneous nerve
Axillary nerve
Median nerve
Ulnar nerve
Medial cutaneous nerve of the forearm
Radial nerve
Medial cutaneous nerve of the arm
Lower subscapular nerve
Thoraco dorsal nerve
Medial pectoral nerve
Upper subscapular nerve
Long thoracic nerve

# Nerves from roots of brachial plexus

## Long thoracic nerve C5-7

- Innervates: Serratus anterior
- Protracts the scapula, fixes the scapula to the thoracic wall, and assists in abduction of the shoulder above 90°

## Dorsal scapular nerve C5

- Innervates: Levator scapulae m.
  Rhomboid major
  Rhomboid minor

studyaid

# Nerves from trunks of brachial plexus

## Subclavian nerve C5-6

- Innervates: Subclavius muscle

## Suprascapular nerve C4-6

- Innervates:

  Supraspinatus
  - Abduction of arm 0-15°

  Infraspinatus
  Externally rotates humerus

studyaid

# Pectoral nerves

## Lateral pectoral nerve

- Arises from lateral cord
- Supplies pectoralis major!
  - Flexes, adducts, and internally rotates the humerus

## Medial pectoral nerve

- Arises from medial cord
- Supplies pectoralis major and minor!
- Pectoralis minor: Stabilizes scapula

studyaid

| Nerve (associated nerve root) | Muscle(s) and function |
| --- | --- |
| Axillary nerve (C5-C6) | Deltoid: 15-90 degrees of shoulder abduction<br>Teres minor: Lateral rotation of arm |
| Musculocutaneous nerve (C5-C7) | Biceps: Elbow flexion and forearm supination<br>Coracobrachialis: Elbow flexion and adduction of arm<br>Brachialis*: Elbow flexion |
| Median nerve (C5-T1) | Pronator teres: Pronation of forearm<br>Flexor carpi radialis: Radial flexion of wrist<br>Palmaris longus: Flexion of wrist<br>Flexor digitorum superficialis: Flexion of fingers<br>Flexor pollicis longus[a]: Flexion of terminal phalanx of thumb<br>Flexor pollicis brevis*: Flexion at proximal phalanx of thumb<br>Flexor digitorum profundus I & II[a]: Flexion terminal phalanx of 2,3 fingers<br>Pronator quadratus[a]: Pronation of forearm<br>Abductor pollicis brevis: Abduction of thumb metacarpal<br>Opponens pollicis: Opposition of thumb metacarpal<br>Lumbricals I & II: Flexion of MCP joints and extension of interphalangeal joints |

studyaid

| | |
|---|---|
| Ulnar nerve (C7-T1) | Flexor carpi ulnaris: Ulnar flexion of wrist<br>Flexor digitorum profundus: Flexion of hand and fingers<br>Abductor digiti minimi: Abduction of 5th digit<br>Opponens digiti minimi: Opposition of 5th digit<br>Flexor digiti minimi: Flexion of 5th digit<br>Lumbricals III & IV: Flexion of MCP joints and extension of interphalangeal joints<br>Interosseous muscles: Abduction and adduction of fingers<br>Adductor pollicis: Adduction of MCP joint of thumb<br>Flexor pollicis brevis**: Flexion at proximal phalanx of thumb |
| Radial nerve (C5-C8) | Triceps: Extension of forearm<br>Anconeus: Extension of forearm<br>Brachialis*: Flexion of elbow<br>Brachioradialis: Flexion of elbow<br>Extensor carpi radialis longus: Radial extension of wrist<br>Supinator: Supination of forearm<br>Extensor carpi radialis brevis: Radial extension at the wrist<br>Extensor digitorum: Extensor of MCP joint of 2nd-5th digits<br>Extensor digiti minimi: Extension of MCP joint of 5th digit<br>Extensor carpi ulnaris: Ulnar extension of wrist<br>Abductor pollicis longus: Abduction of MCP of thumb<br>Extensor pollicis longus: Extensor of thumb<br>Extensor pollicis brevis: Extensor of thumb<br>Extensor indicis: Extension of 2nd finger |

studyaid

# Busy day! Lets meet our first patient

Marek, 25, Lover of adrenaline and zakrzowek!
He decided to jump from a cliff to show all his friends how cool he is. He loses his balance and lands with his elbow first!

We find a supracondylar fracture of the humerus on X-ray

Now has problems making a fist →



# Busy day! Lets meet our first patient

Marek, 25, Lover of adrenaline and zakrzowek!
He decided to jump from a cliff to show all his friends how cool he is. He loses his balance and lands with his elbow first!

We find a supracondylar fracture of the humerus on X-ray

Now has problems making a fist →

What famous person also makes this hand?
A. Yoda
B. The pope
C. GG



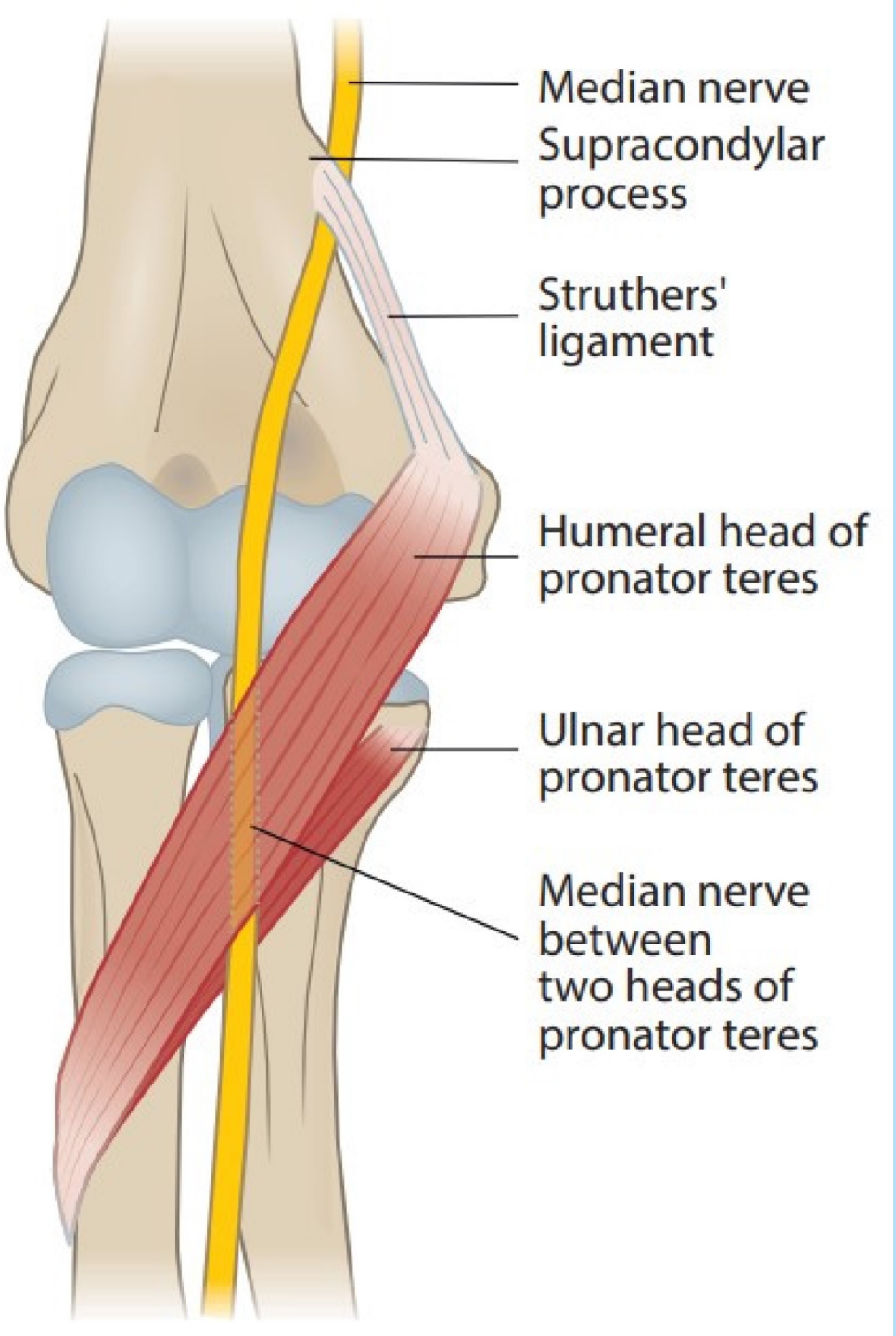
Median nerve
Supracondylar process
Struthers' ligament
Humeral head of pronator teres
Ulnar head of pronator teres
Median nerve between two heads of pronator teres

studyaid

# Median nerve landmarks

1. Medial and lateral cords of brachial plexus C5-T1
2. Lateral to supracondylar process
3. Cubital fossa, medial to biceps brachii tendon
4. Enters wrist through carpal tunnel

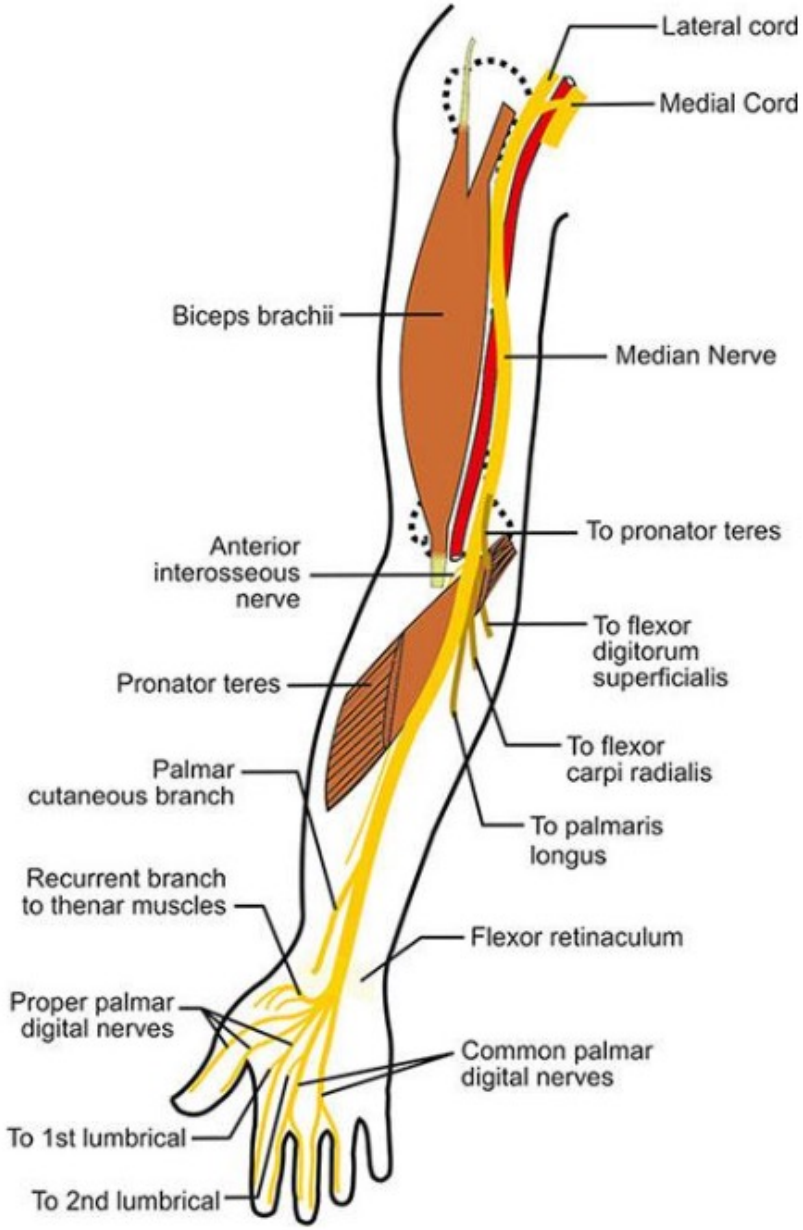

# Median nerve

Innervates: 1. Flexor carpi radialis
2. Palmaris longus
3. Pronator quadratus
4. Pronator teres
5. Digital flexors

Main movement: Wrist flexion and abduction, Forearm pronation, Thumb flexion and opposition and flexion of digits 2 and 3

Sensory: Skin over <u>anterolateral</u> surface of hand

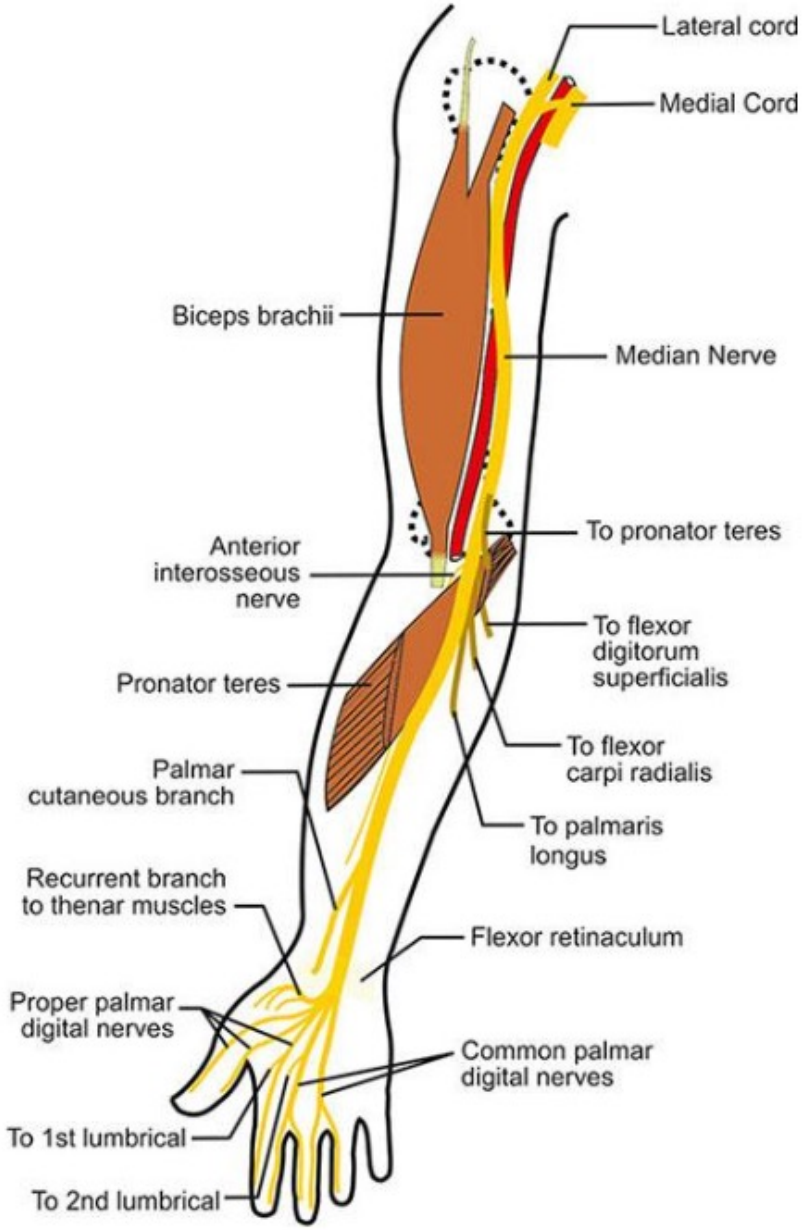

# Busy day! Lets meet our first patient

Marek, 25, Lover of adrenaline and zakrzowek!
He decided to jump from a cliff to show all his friends how cool he is. He loses his balance and lands with his elbow first!

We find a supracondylar fracture of the humerus on X-ray

Now has problems making a fist →

What famous person also makes this hand?
A. Yoda
***B. The pope***
C. GG

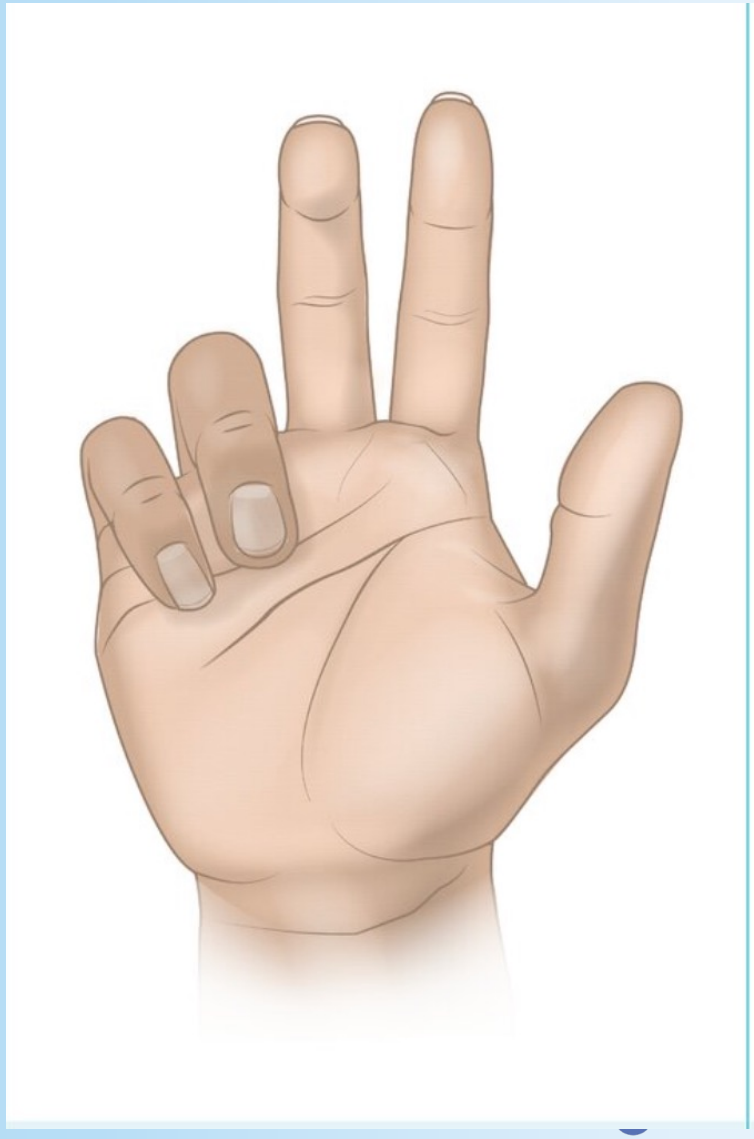

# Busy day! Lets meet our first patient

Peter, 42, Loves adrenaline and zakrzowek

supracondylar fracture after an accident

Now has problems making a fist →

***Proximal median nerve compression. Impossible for the patient to flex thumb, and 2. and 3rd digits. Called «Popes blessing» or «Hand of Benedection»***



# The medical students demise

Peter, 1st year MD, presents to you with weakness when gripping and a tingling sensation accompanied by some pain.
Limited to the first 3 digits, and a little in the 4th digit. Only in the right hand.

The past 3 weeks he has had histology, biochemistry and now is getting ready for his anatomy test. He loves taking notes, and carries his ipad and pen everywhere he goes. He is anxious, sleep deprived and tells you about vivid dreams of aminoacids



studyaid

# The medical students demise

Peter, 1st year MD, presents to you with weakness when gripping and a tingling sensation accompanied by some pain.
Limited to the first 3 digits, and a little in the 4th digit. Only in the right hand.

The past 3 weeks he has had histology, biochemistry and now is getting ready for his anatomy test. He **loves** taking notes, and carries his ipad and pen everywhere he goes. He is anxious, sleep deprived and tells you about vivid dreams of aminoacids

**What do you recommend him to do?**

A. Stop taking notes
B. Take even more notes, no pain no gain
C. Maybe its time for a christmas break



studyaid

# Carpal tunnel syndrome

Compression of median nerve
*(distal median nerve lesion)*

Paresthesia (numbness, burning, tingling)

***Does not feature hand of benection***

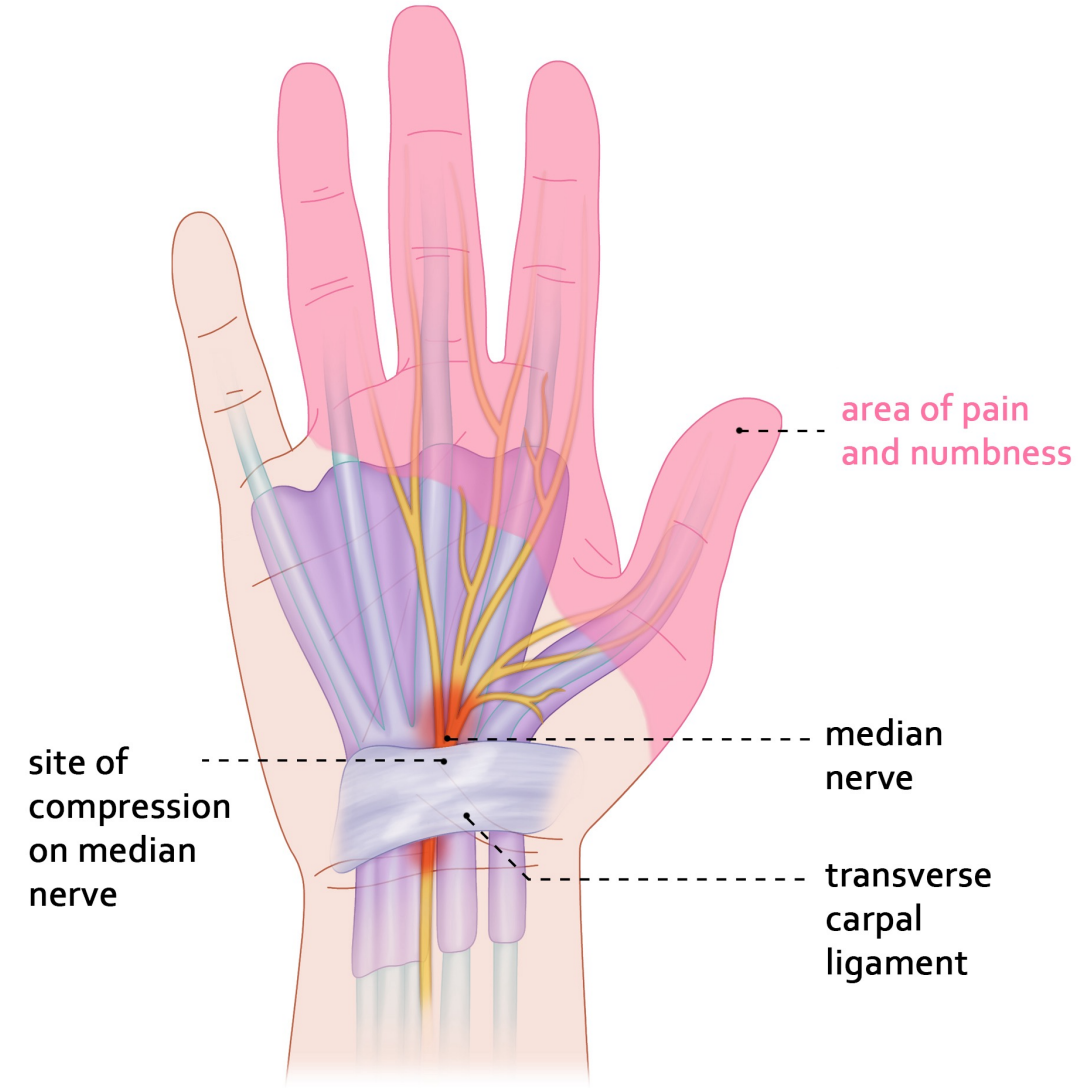


Carpal Tunnel Syndrome

# Tests for carpal tunnel syndrome

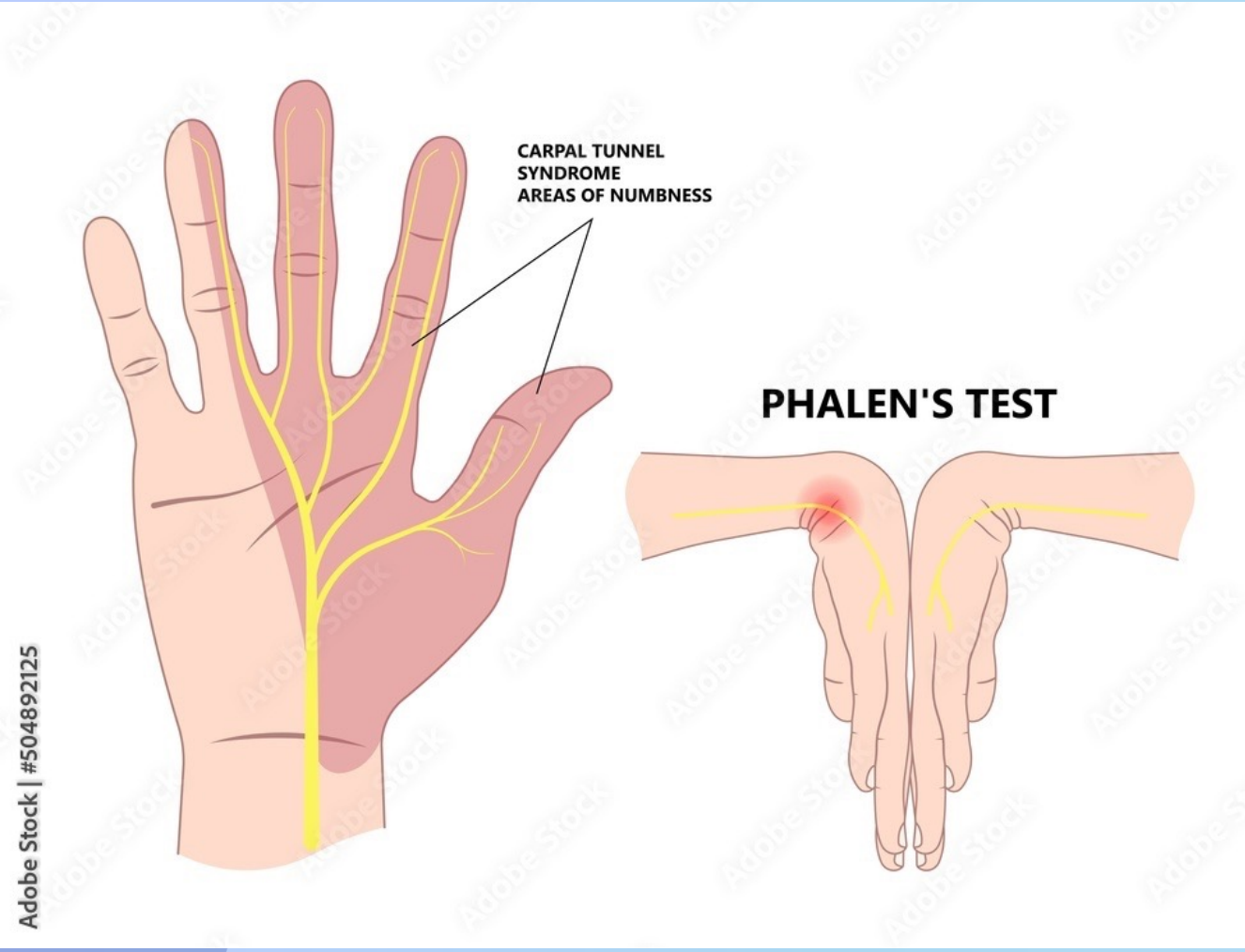


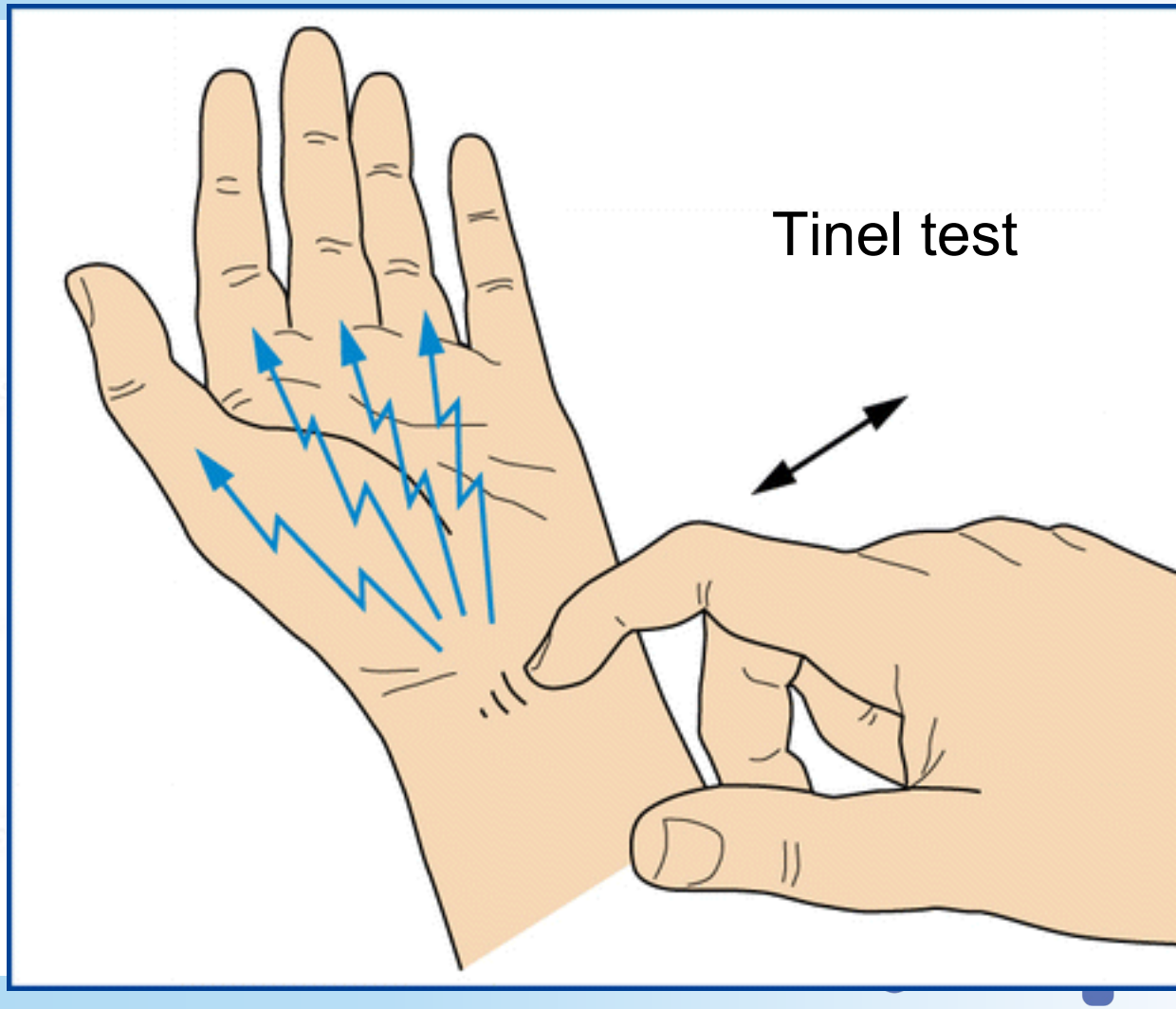

# The medical students demise

Peter presents to you with weakness when gripping and «pins and needles» feeling accompanied by some diffuse pain. Limited to the first 3 digits, and a little in the 4th digit. Only in the right hand.

The past 3 weeks he has had histology, biochemistry and now is getting ready for his anatomy test. He loves taking notes, and carries his ipad and pen everywhere he goes. He is anxious, sleep deprived and tells you about vivid dreams of aminoacids

What do you recommend him to do?

A. Stop taking notes
B. Take even more notes, no pain no gain
C. ***Maybe its time for a christmas break***



# The medical students demise

Peter presents to you with weakness when gripping and «pins and needles» feeling accompanied by some diffuse pain. Limited to the first 3 digits, and a little in the 4th digit. Only in the right hand.

The past 3 weeks he has had histology, biochemistry and now is getting ready for his anatomy test. He loves taking notes, and carries his ipad and pen everywhere he goes. He is anxious, sleep deprived and tells you about vivid dreams of aminoacids



***Compression of median nerve in the carpal tunnel, due to overuse of muscles causing inflammation of the transverse carpal ligament.***

***Called carpal tunnel syndrome***

***This is a <u>distal</u> median nerve lesion***

# Patient number 3!

Cant r

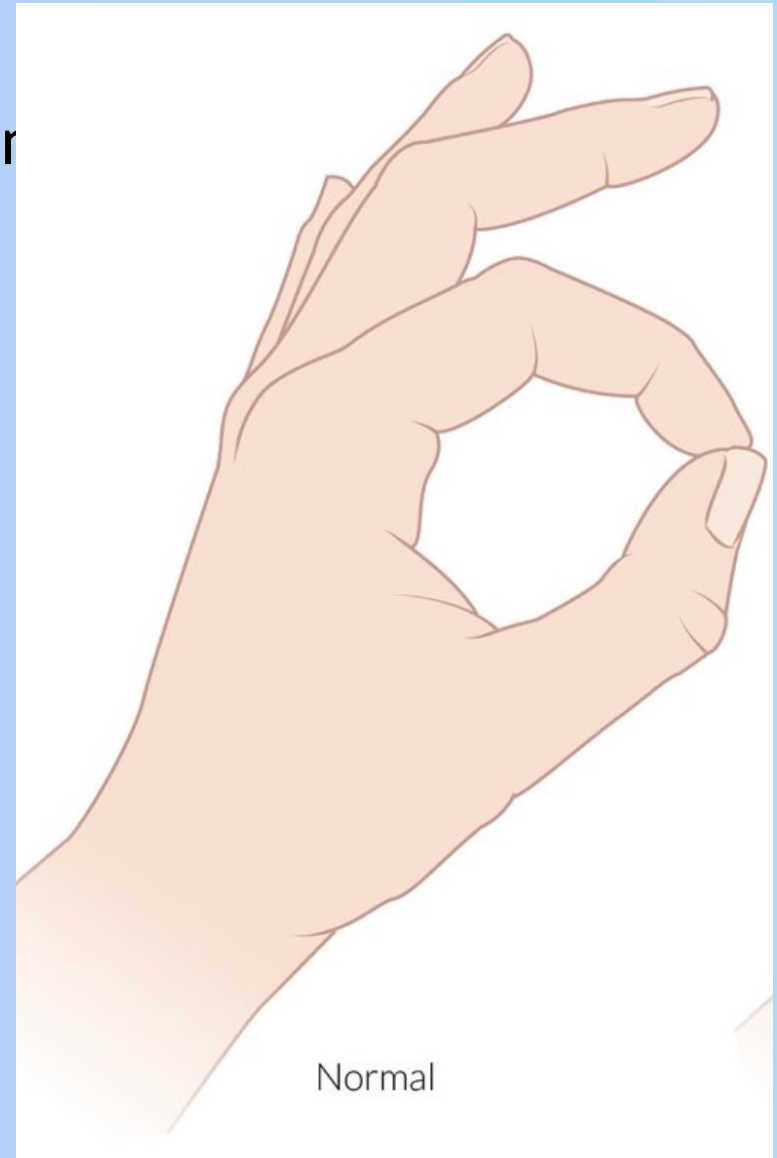


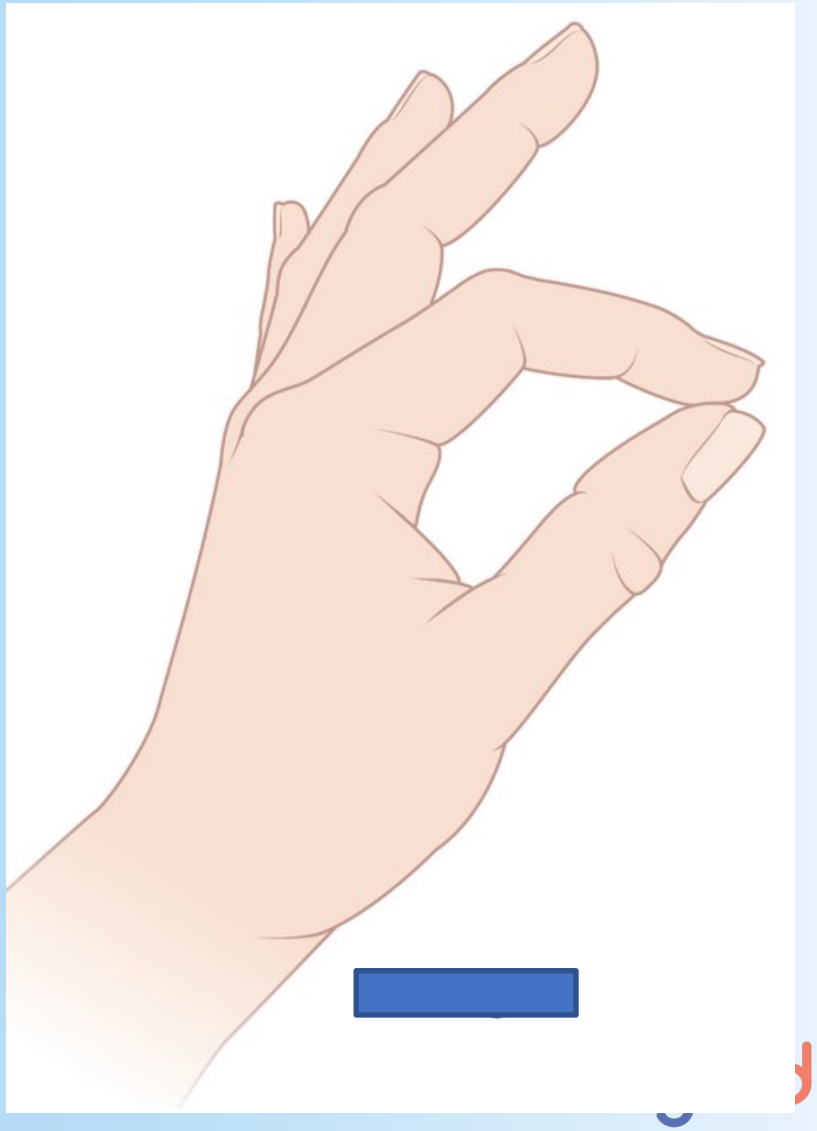

# Anterior interosseous nerve

Innervates:
1. Pronator quadratus
2. Flexor pollicis longus
3. Flexor digitorum profundus (lateral)

Pure motor branch of median nerve

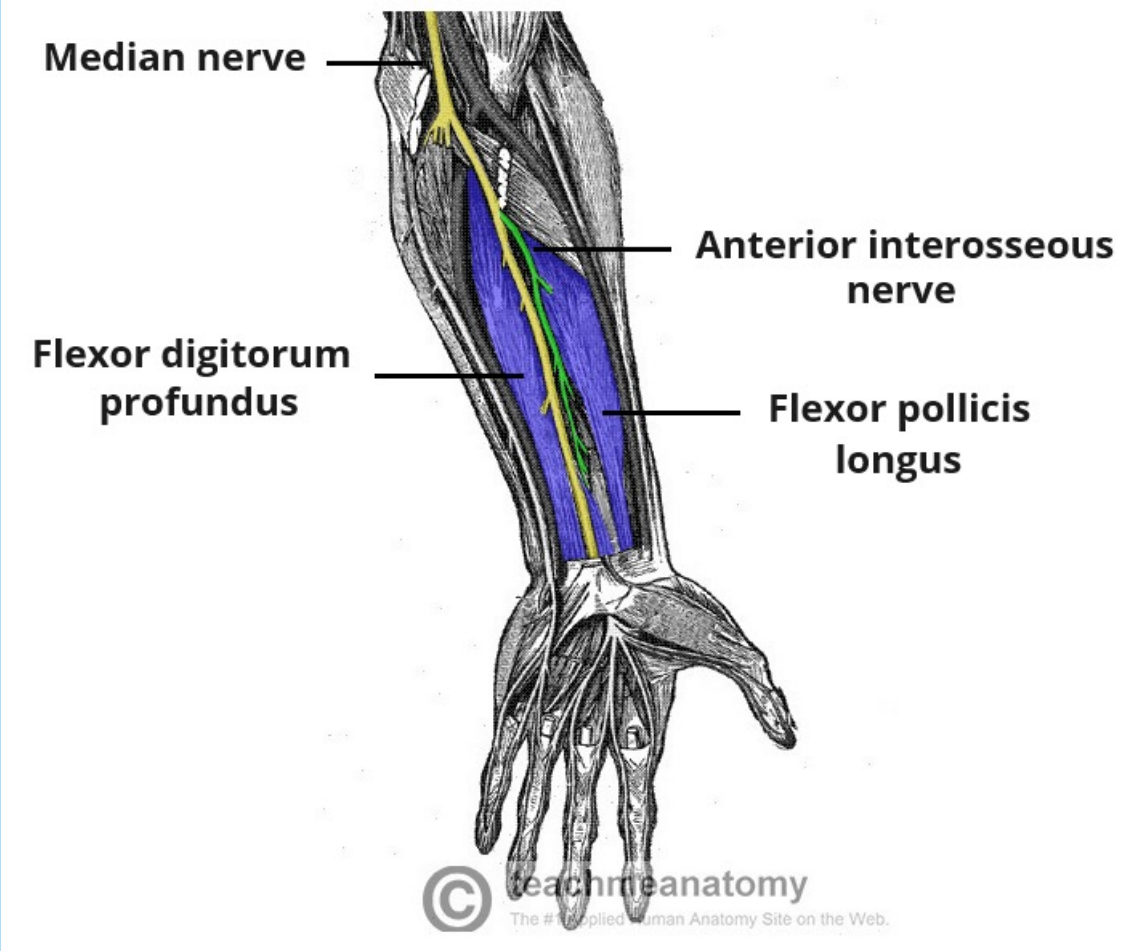

# Atrophy of thenar muscles

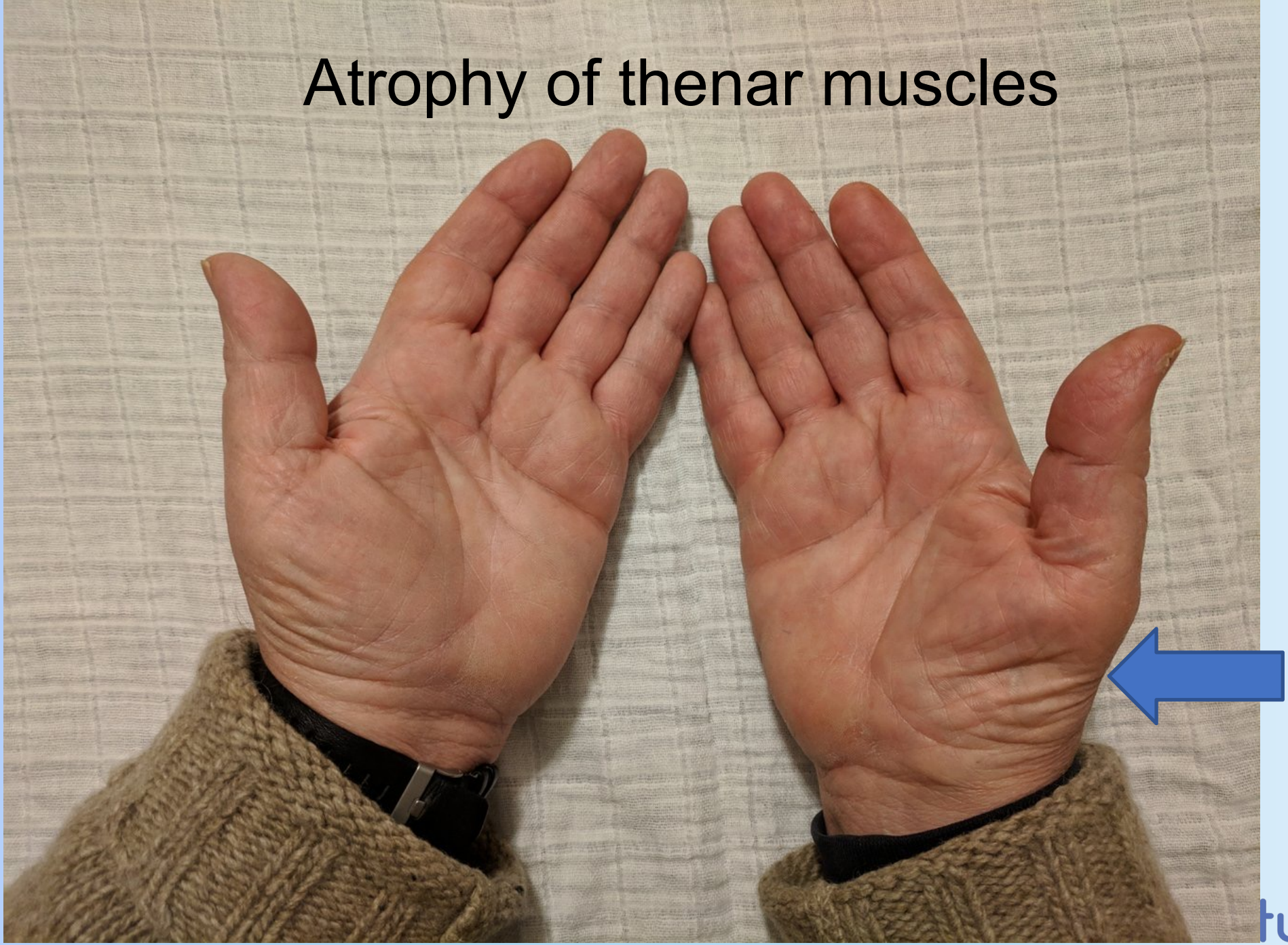

# The party lion from Katowice

Tomasz, has been out partying all night and fell asleep on a chair at a narch at westerplatte. When he wakes up he is numb and is totally unable to extend his wrist!

What has happened???



# Nerves of the Upper Extremities

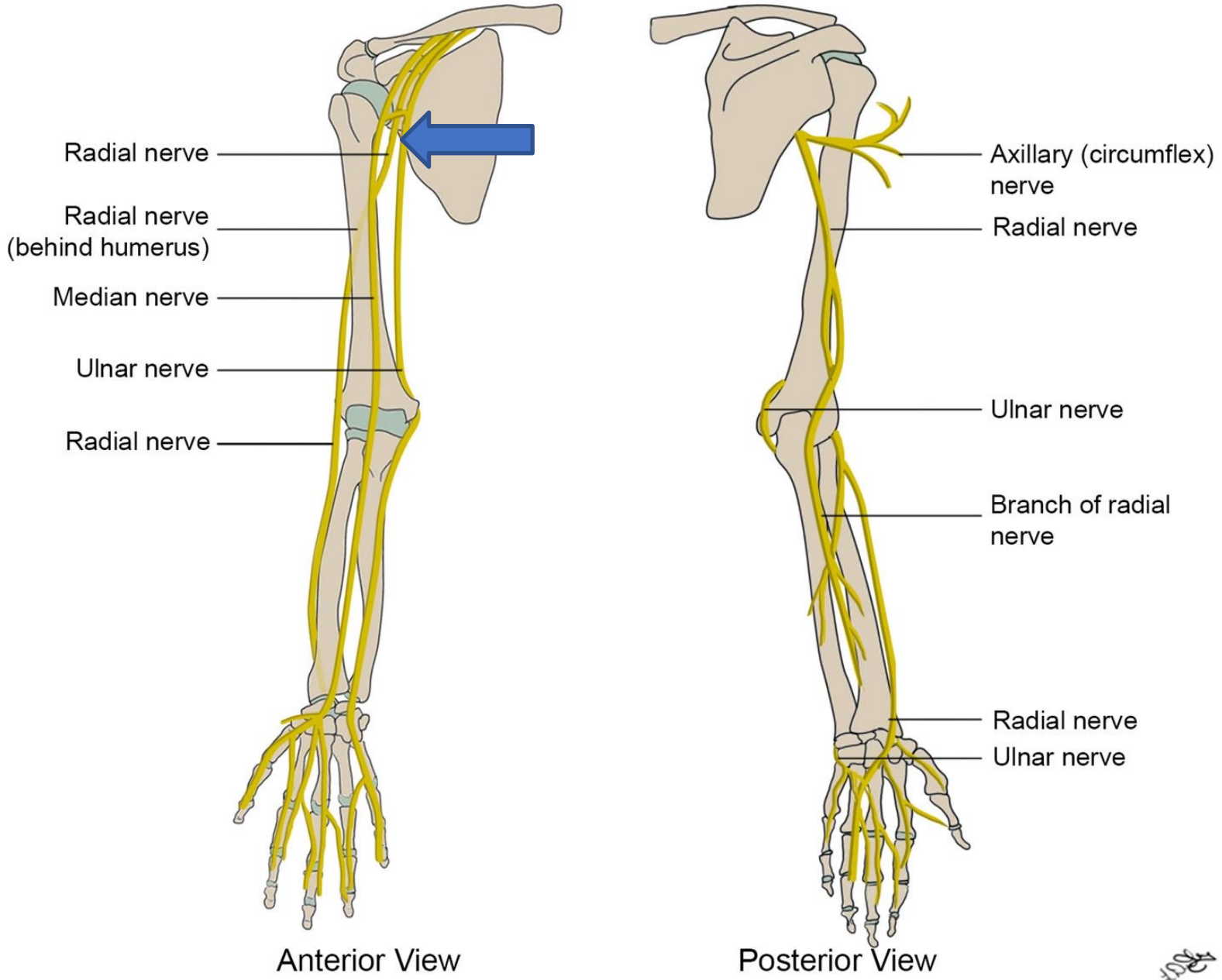


© Lineage

studyaid

# Radial nerve landmarks

1. Posterior chord of brachial plexus C5-T1

2. Radial groove of humerus, between lateral and medial heads of triceps

3. Passes anterior to lateral epicondyle

4. Passes through cubital fossa and divides into deep (motor) and superficial branch (sensory)



# Radial nerve motor innervation

1. Arm: Triceps brachii, Anconeus

2. Forearm:
Superficial extensors (3): Brachioradialis
Extensor carpi radialis longus + brevis

Deep extensors: Extensor digitorum
Extensor digiti minimi
Extensor carpi ulnaris
Supinator
Abductor pollicis longus
Extensor pollicis longus + brevis

Via posterior interosseous nerve!

studyaid

# The party lion from Katowice

Tomasz, has been out partying all night and fell asleep on a chair at a narsj. When he wakes up he is numb and is totally unable to flex his wrist!
What has happened???

***Radial nerve compression!***

***High yield: Mid-shaft fracture of humerus also gives radial nerve compression***




studyaid

# Radial nerve sensory innervation

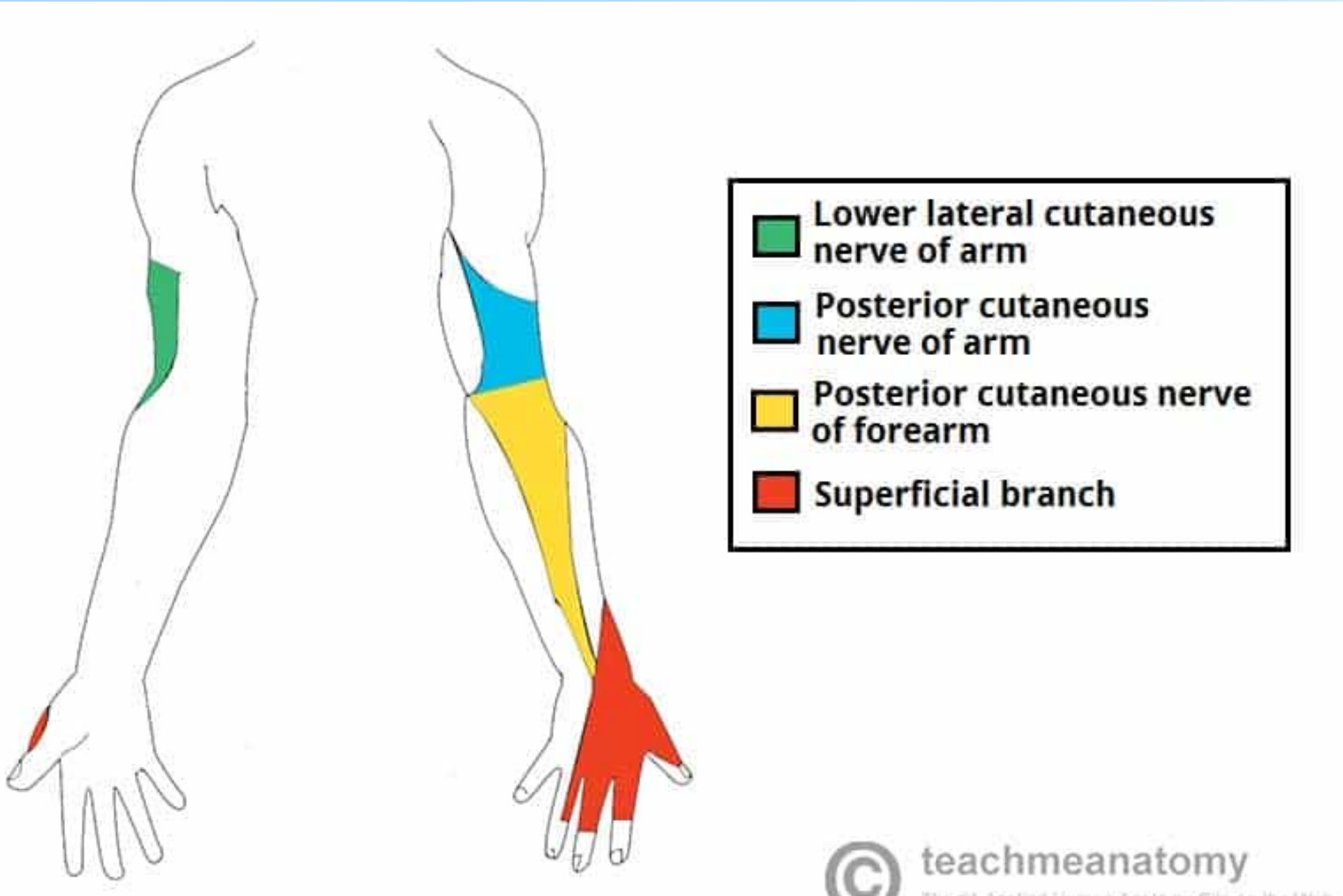

# Symptoms of Radial Nerve Injury

## At the axilla:

- weakness
- tingling and numbness from the back of the arm to the hand

## To the spiral groove:

- weakening of the brachioradialis muscle of the forearm
- interferes with a person's ability to bend the wrist back and straighten the fingers

## To the posterior interosseous nerve:

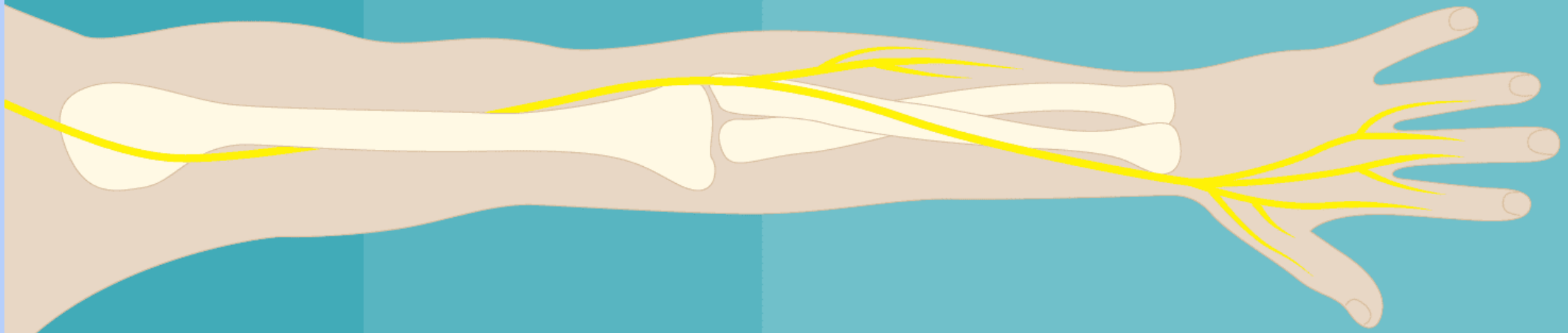

- muscle weakness
- inability to extend one's fingers

verywell

# The local cyclist

Patient walks into your office with pain in his elbow and numbness and weakness in his fingers. He is a semi-professional cyclist and every year he trains extremely hard for Tour De Krakow, but after a dislocation of his elbow he has so much discomfort that he cannot train!

He presents to you with this hand at rest.



# The local cyclist

Patient walks into your office with pain in his elbow and numbness in his fingers. He is a semi-professional cyclist and every year he trains extremely hard for Tour De Krakow, but now he has so much discomfort that he cannot train!

He presents to you with this hand at rest.



What is going on?

A. Seems fine to me
B. He's just making a pistol with his fingers, everything is fine
C. Ulnar nerve compression?

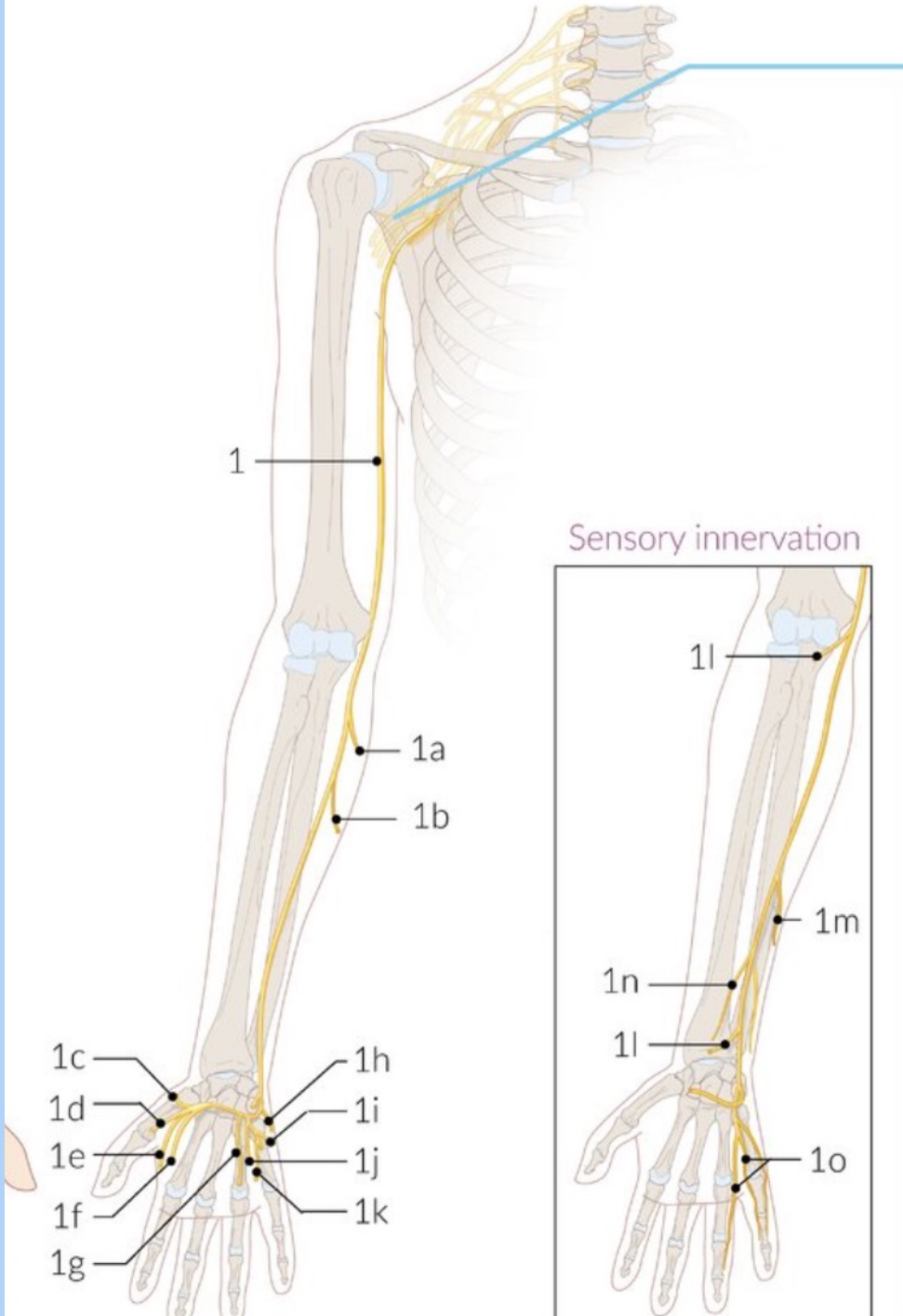


Derived from the medial cord of the brachial plexus

- 1 Ulnar nerve
  - 1a Flexor carpi ulnaris muscle
  - 1b Flexor digitorum profundus muscle (digits III–V)
  - 1c Adductor pollicis muscle
  - 1d Flexor pollicis brevis muscle, deep head
  - 1e Dorsal interosseous muscles I–IV
  - 1f Palmar interosseous muscles I–III
  - 1g Lumbrical muscles III and IV
  - 1h Abductor digiti minimi muscle
  - 1i Flexor digiti minimi brevis muscle
  - 1j Opponens digiti minimi muscle
  - 1k Palmaris brevis muscle
  - 1l Articular branches
  - 1m Dorsal branches of ulnar nerve
  - 1n Palmar branches of ulnar nerve
  - 1o Palmar digital nerves

Sensory innervation

Motor innervation

# Ulnar pathway

Behind medial epicondyle of the humerus (*In cubital tunnel*)

Enters palm through ***Guyon canal***

*Deep motor branch* and *superficial branch*

***High yield: Superficial innervates palmaris brevis!***

***High yield: Fracture of medial epicondyle -> Ulnar nerve lesion***

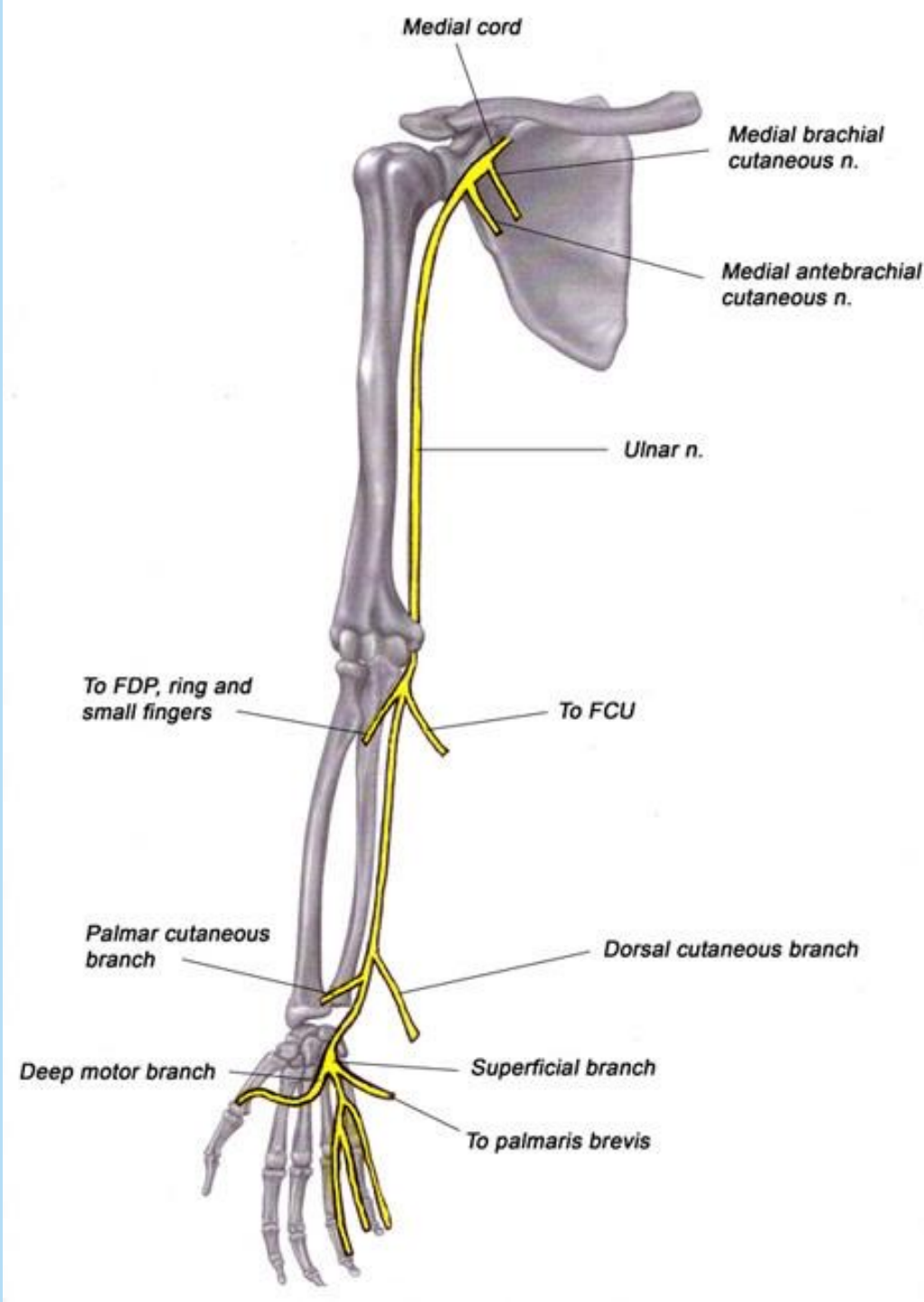

# Ulnar nerve motor Innervation

**Hand:**
Hypothenar muscles (Little finger m.):
Abductor digiti minimi
Flexor digiti minimi brevis
Opponens digiti minimi

Palmar muscles:
Lumbricals (medial 2)
Interossei muscles:
Palmar (3) – **AD**ducts fingers
Dorsal (4) – **AB**ducts fingers

**Hand:**
Thenar muscles (Thumb muscles):
Adductor pollicis
Deep head of flexor pollicis brevis

Other: Palmaris brevis (superficial ulnar)

**Forearm** - Flexor carpi ulnaris
Flexor digitorum Profundus

studyaid

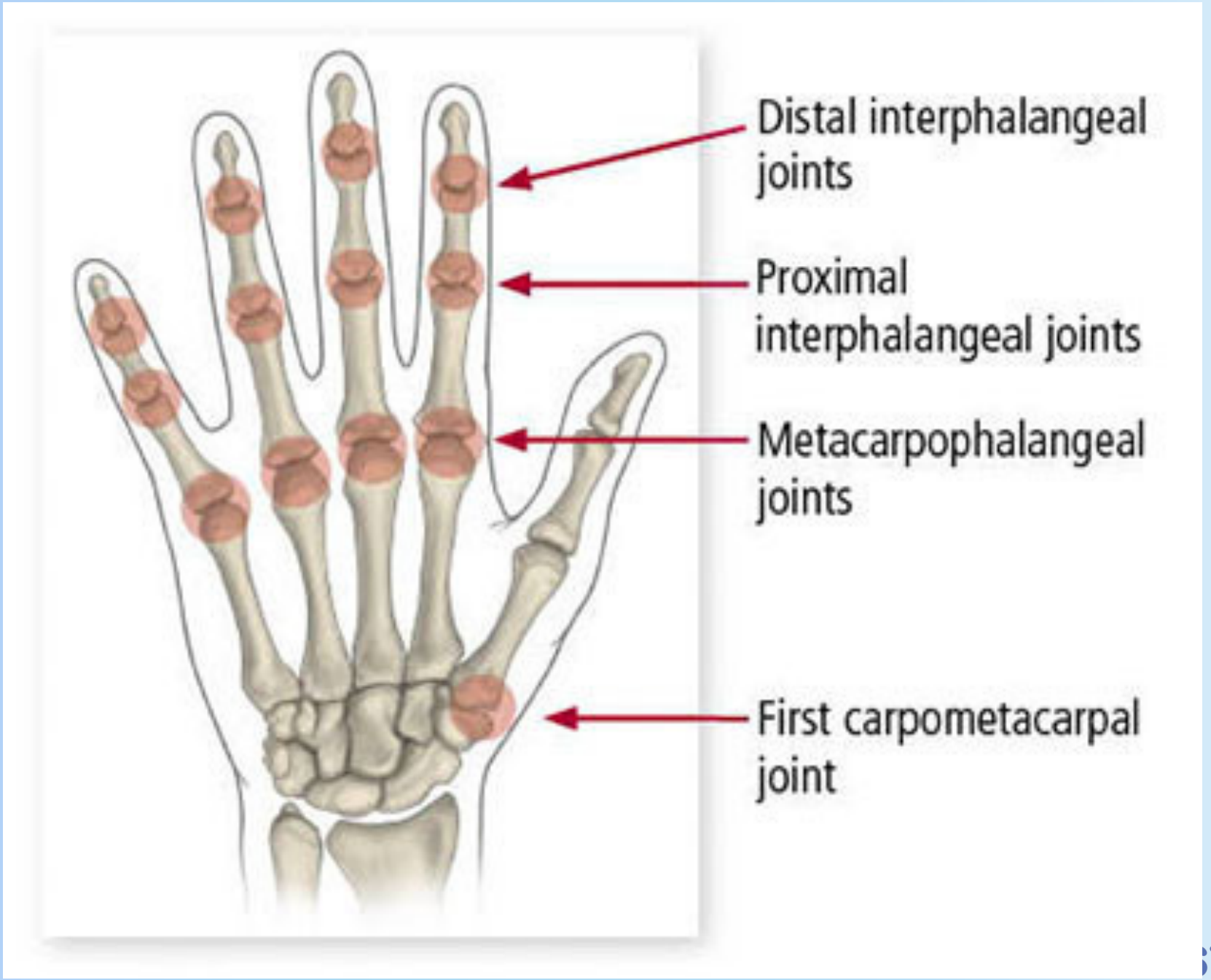
Distal interphalangeal joints
Proximal interphalangeal joints
Metacarpophalangeal joints
First carpometacarpal joint

# Lumbricals

- Flexes MCP
- Extends PIP and DIP
- **Median nerve**: Lumbricals 1 and 2
- **Ulnar nerve**: Lumbricals 3 and 4

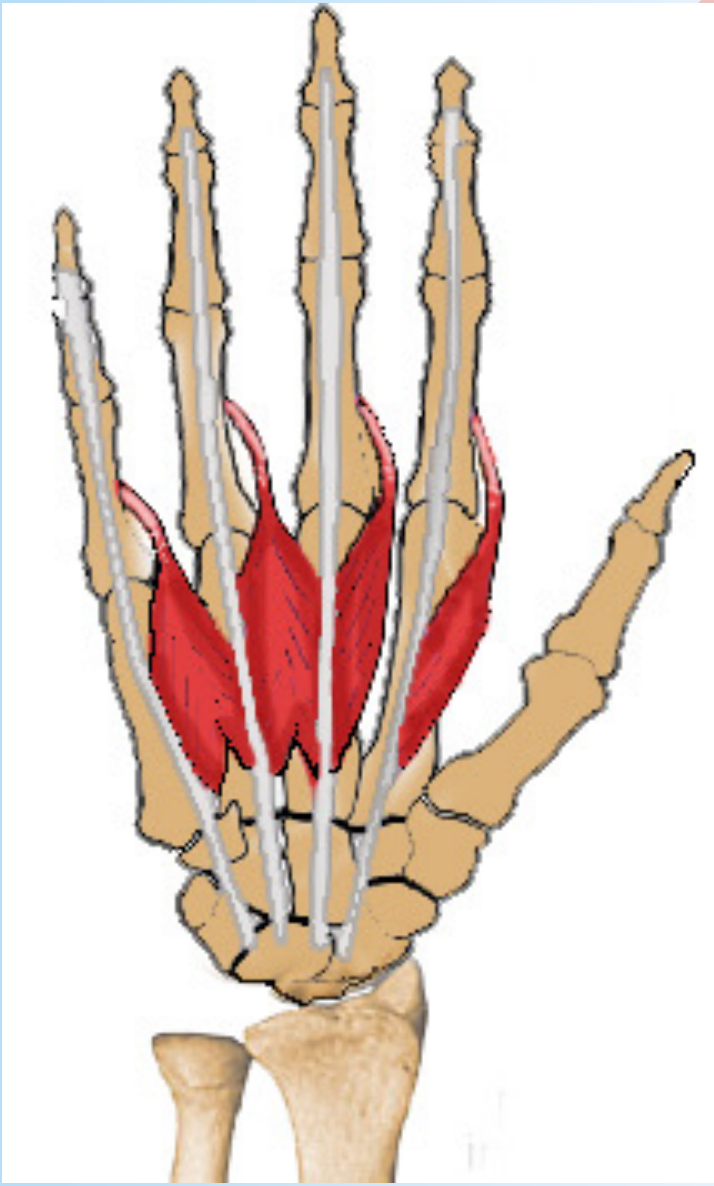

studyaid

# The local cyclist

Patient walks into your office with pain in his elbow and numbness in his fingers. He is a semi-professional cyclist and every year he trains extremely hard for Tour De Krakow, but now he has so much discomfort that he cannot train!

He presents to you with this hand at rest.



What is going on?

A. Seems fine to me
B. He's just making a pistol with his fingers, everything is fine
***C. Ulnar nerve compression!***

# The local cyclist

Patient walks into your office with this hand at rest.



***Cubital tunnel syndrome (entrapment of the ulnar nerve)*** Because of dislocation of his elbow

***Ulnar claw hand, flexed proximal and distal interphalangeal joint (PIP, DIP) and extension of metacarpophalangeal joint (MCP), Caused by <u>lesion to ulnar nerve</u>***

studyaid

# Ulnar Nerve Impingement

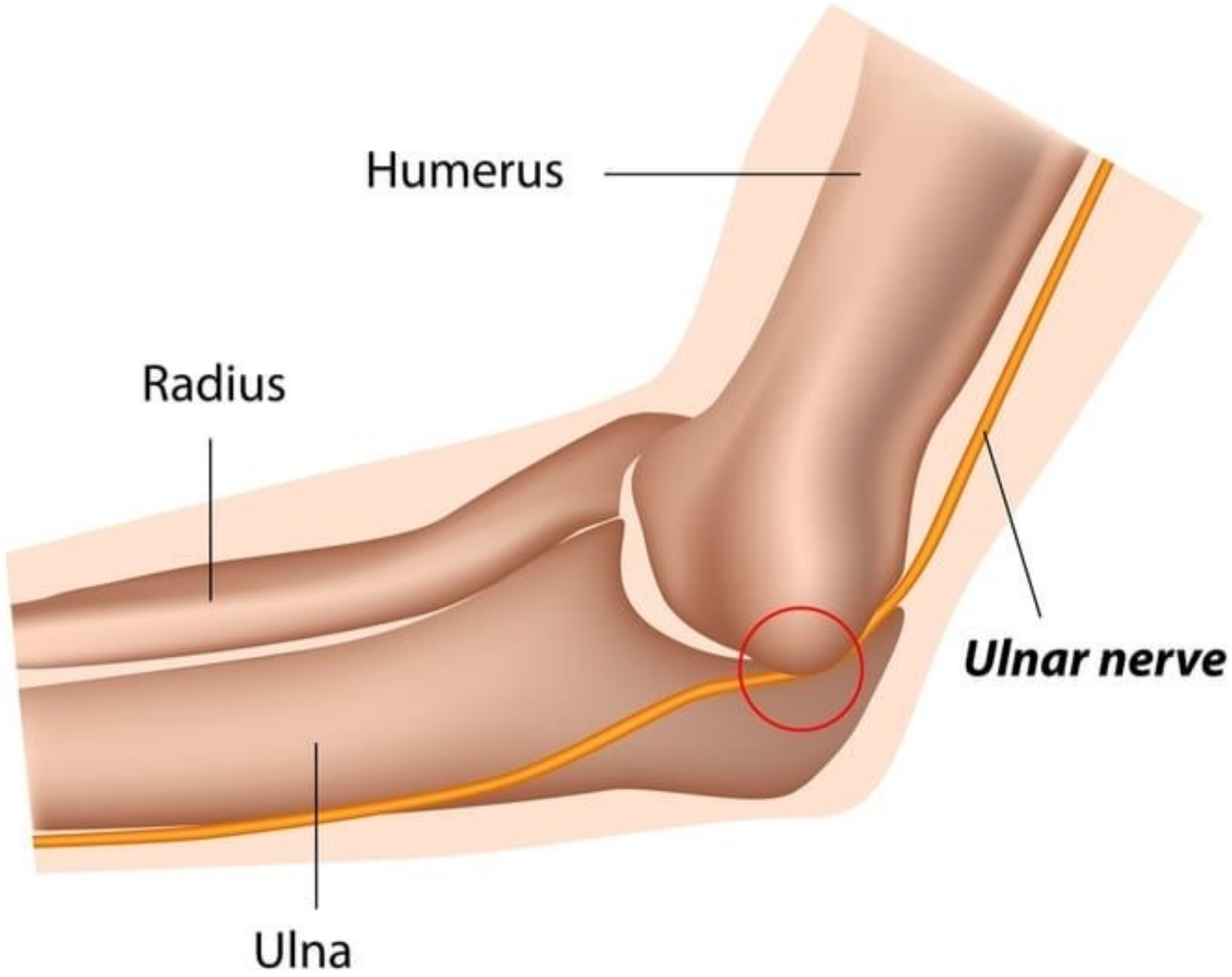


studyaid

1. Flexion of PIP and DIP at the 4th and 5th digits
2. Hypothenar atrophy
3. Hyperextension of the 4th and 5th digits at the MCP joints
4. Atrophy of the interosseous muscles
- Inability to adduct thumb

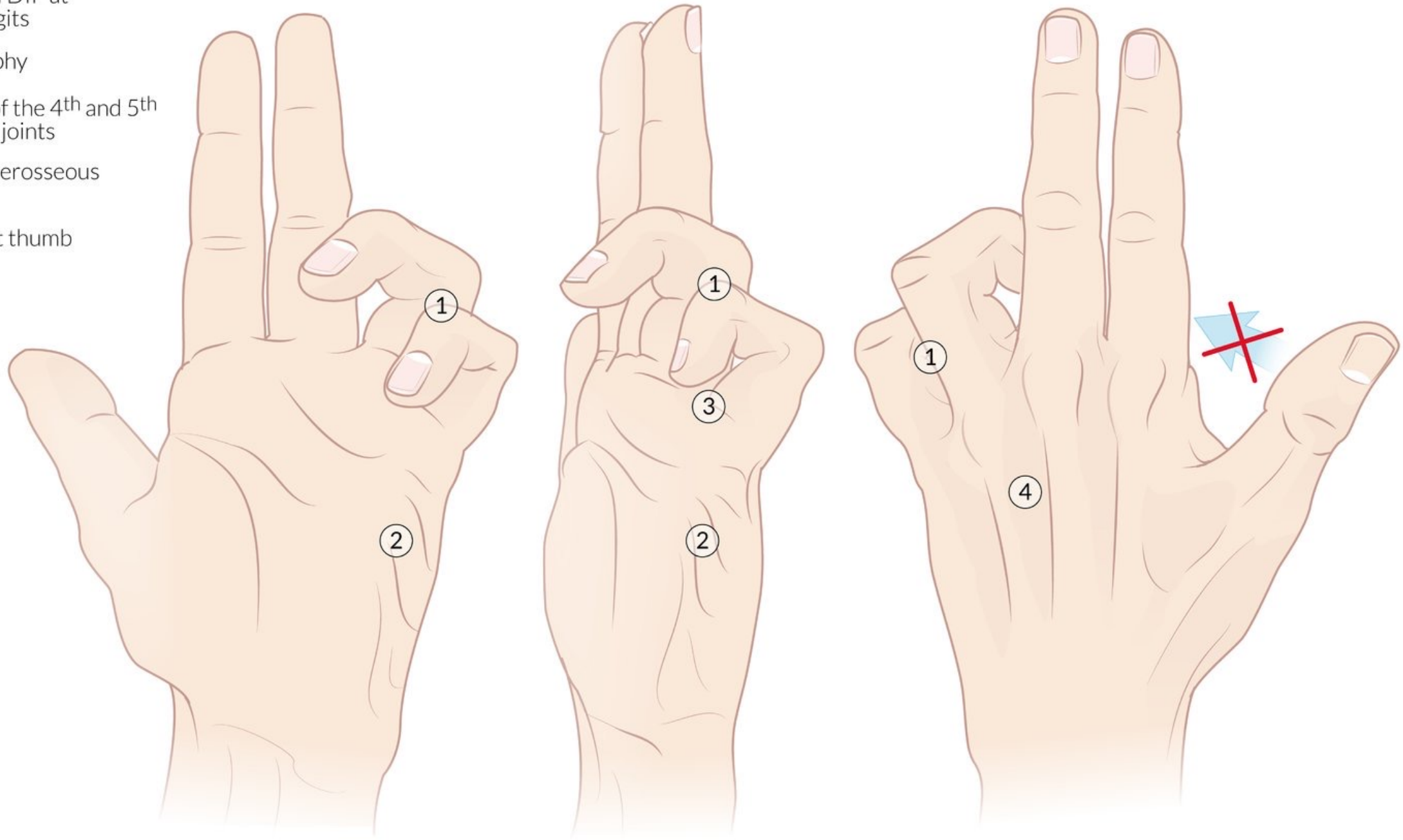


Frontal view

Ulnar lateral view

Dorsal view

## Distal median nerve lesions
(below AI nerve origin)



**Median claw**

*When patient tries to extend fingers*



studyaid

# High yield: Froment sign





# Ulnar sensory innervation

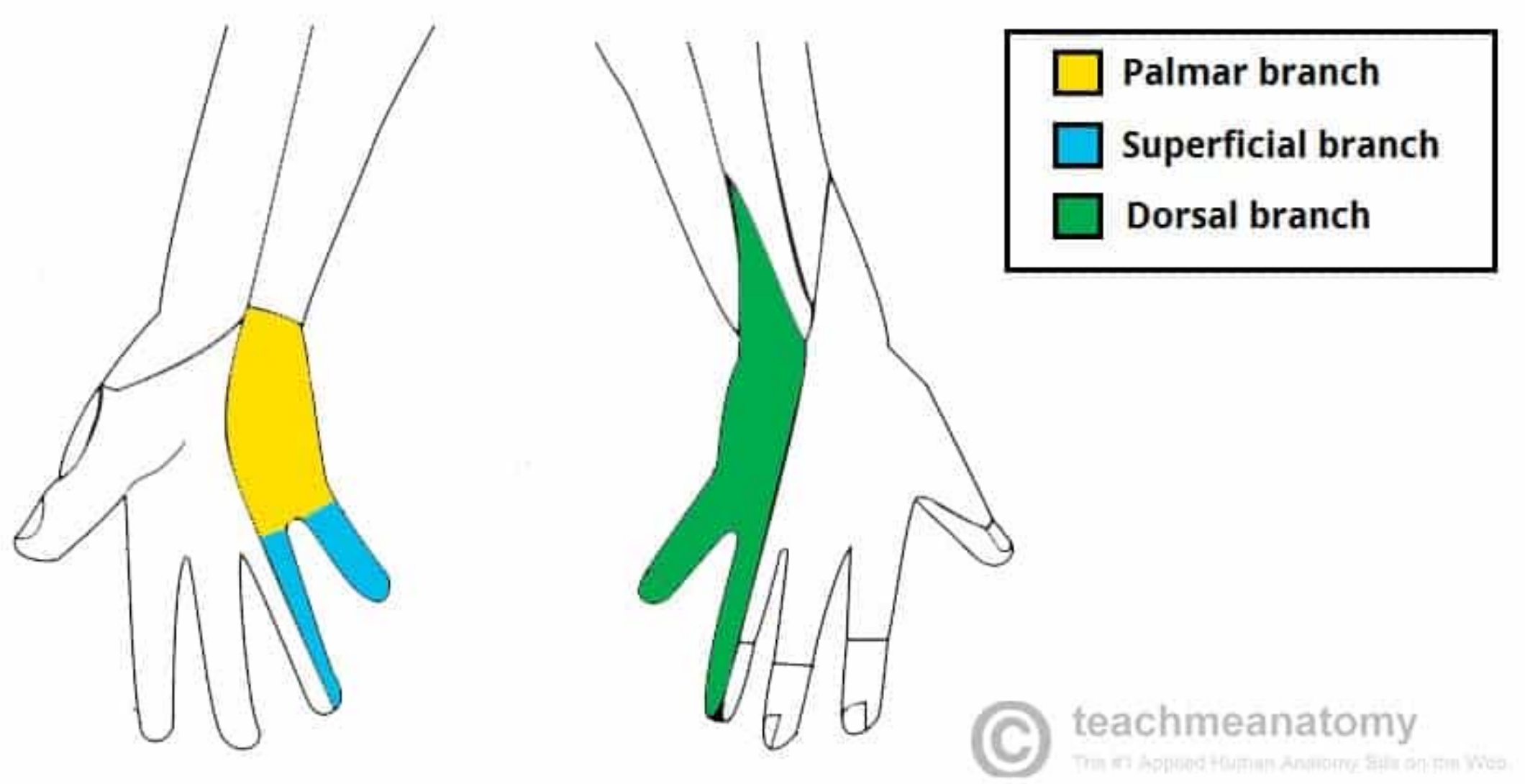

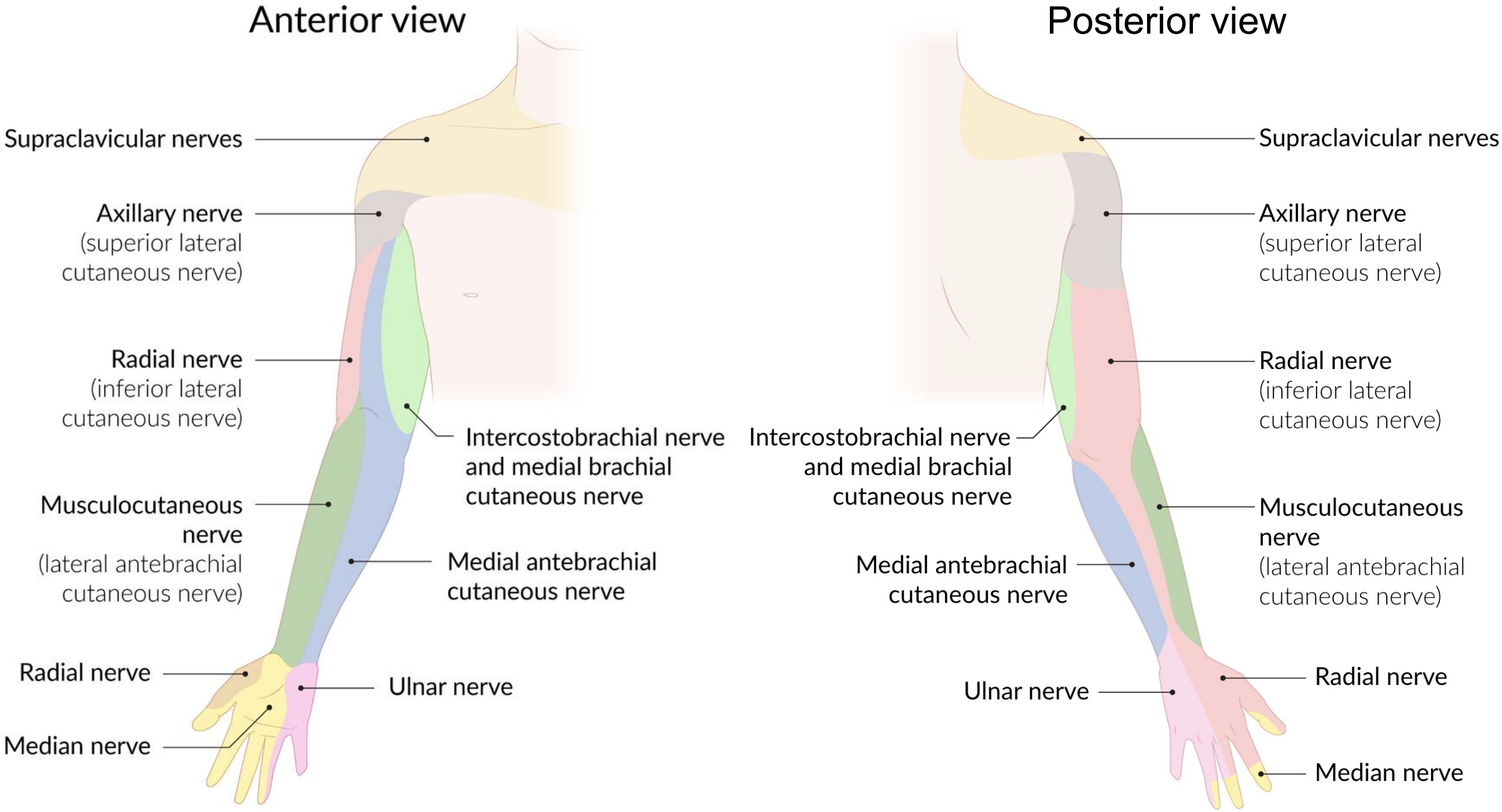
Anterior view
Supraclavicular nerves
Axillary nerve
(superior lateral
cutaneous nerve)
Radial nerve
(inferior lateral
cutaneous nerve)
Musculocutaneous
nerve
(lateral antebrachial
cutaneous nerve)
Radial nerve
Median nerve
Intercostobrachial nerve
and medial brachial
cutaneous nerve
Medial antebrachial
cutaneous nerve
Ulnar nerve
Posterior view
Supraclavicular nerves
Axillary nerve
(superior lateral
cutaneous nerve)
Radial nerve
(inferior lateral
cutaneous nerve)
Intercostobrachial nerve
and medial brachial
cutaneous nerve
Medial antebrachial
cutaneous nerve
Musculocutaneous
nerve
(lateral antebrachial
cutaneous nerve)
Ulnar nerve
Radial nerve
Median nerve

# High yield about fractures

| Fracture Location | Commonly Affected Nerve | Key Deficits |
| --- | --- | --- |
| Proximal humerus/surgical neck | Axillary nerve | Weak deltoid/teres minor, regimental badge sensory loss |
| Mid-shaft | Radial nerve | Wrist drop, posterior arm/hand sensory loss |
| Distal humerus/supracondylar | Median nerve | Weak finger/thumb flexion, lateral hand sensory loss |
| Medial epicondyle | Ulnar nerve | Claw hand, medial hand sensory loss |

studyaid

# Axillary nerve

Innervates: Deltoid and teres minor

Main movement: Abduction of arm 15-90 degress

Sensory: Skin over shoulder

***High yield: Surgical neck of humerus fracture? Probably axillary nerve***

studyaid

# Musculocutaneous nerve C5-C7

Innervates:
1. Biceps brachii
2. Brachialis
3. Coracobrachialis

Main movement: Elbow flexion

Sensory: Lateral cutaneous nerve of forearm (Lateral forearm)

***High yield: Strongest supinator muscle is the biceps brachii***

studyaid

# Erb-Duchenne palsy

- Usually due to problems during birth
- Damage to upper part of brachial plexus
- Internal rotation of arm of the affected side
- «Waiter-tip» deformity

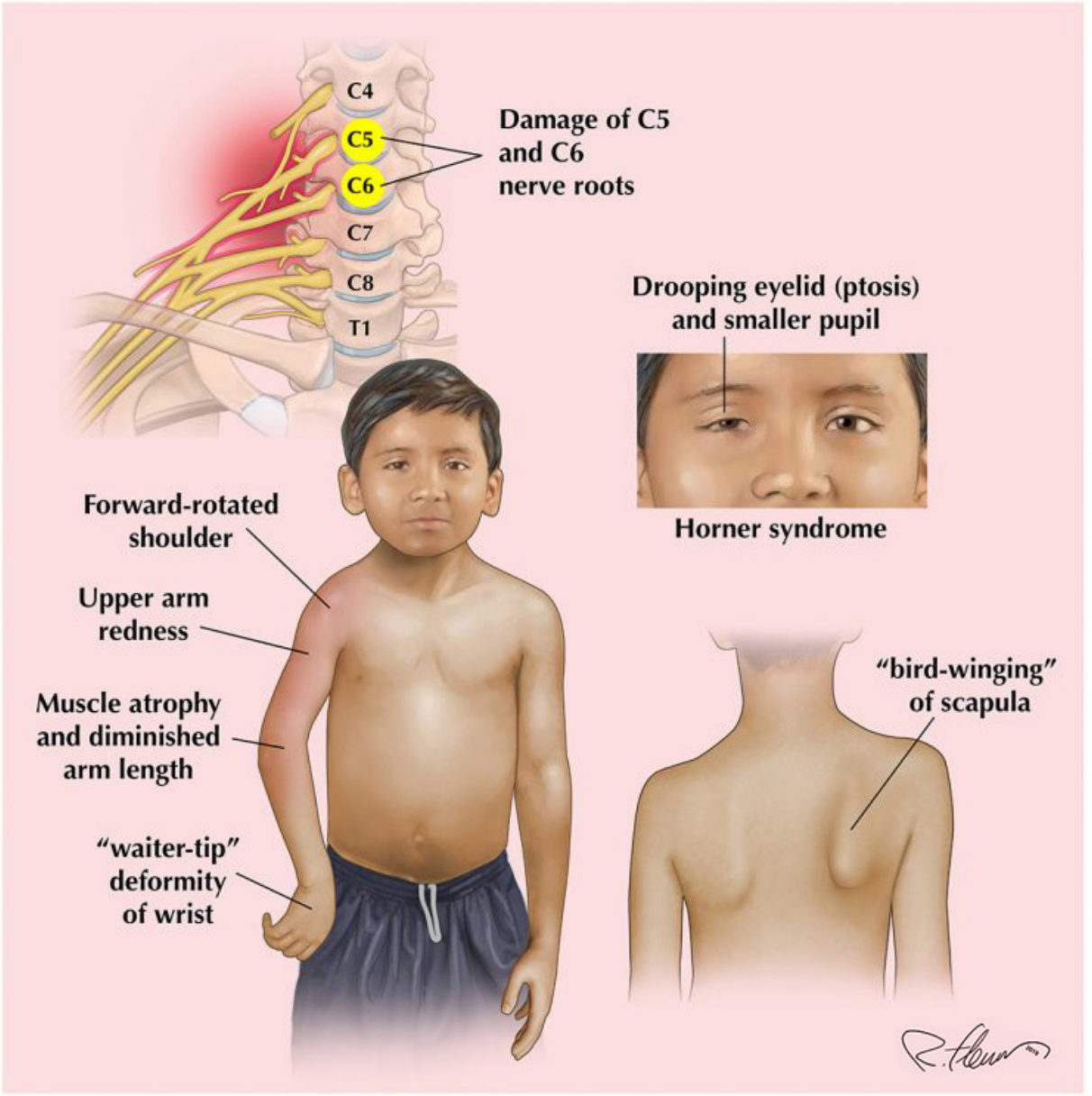

# Klumpke’s palsy

Due to stretch/tear injury

Lower part of brachial plexus C8-T1

Atrophy of forearm and hand muscles

«Claw hand»

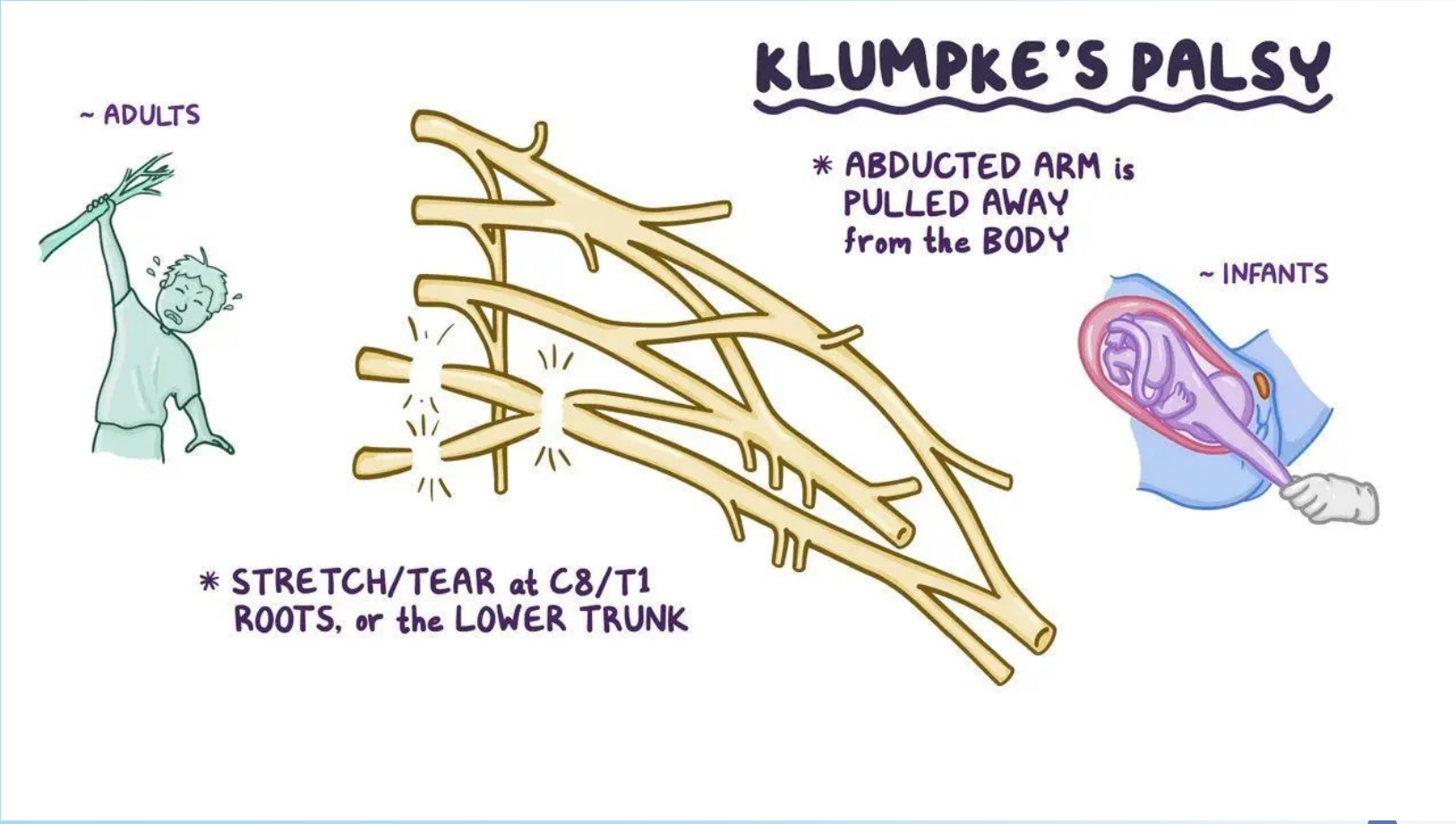


studyaid

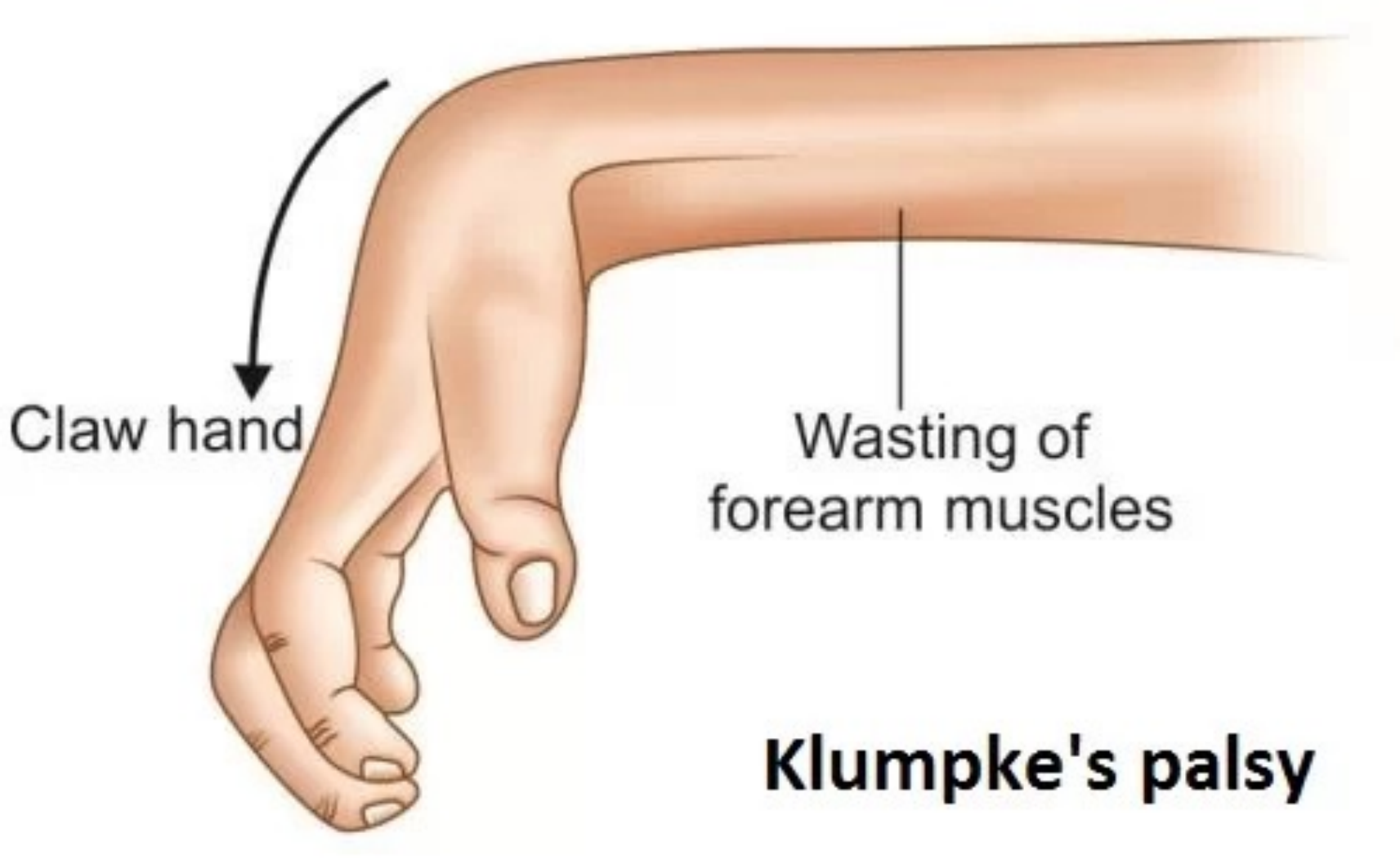


studyaid

# Wooclap!!

Copy participation link

1 Go to wooclap.com

2 Enter the event code in the top banner

Event code
XBDMKR